

Case Report

Ridge Augmentation with autogenous bone graft in anterior region: A case series

Sneha Puri

Department of Periodontics, Swargiya Dadasaheb Kalmegh Smruti Dental College, Nagpur Maharashtra – 441110. Affiliated to MUHS University, Nagpur

ABSTRACT:

Background: The aim of the present study is to evaluate clinical success of bone augmentation using mandibular bone block obtained from symphysis region fixed by titanium pins to augment a single tooth site in maxillary anterior region. **Method:** Ten systemically healthy patients with age range of 22 to 30 years having edentulous area with single tooth ridge deformity in maxillary anterior region were treated by using ridge augmentation procedure by using autogenous bone graft. **Result:** A mean gain of buccolingual ridge width was 2.9 mm, while apico coronal gain was 2.1 mm was observed at 6 months post-operatively. **Conclusion:** The present case series study indicates successful reconstruction of both horizontal & vertical ridge defect using mandibular bone block at the site of single implant placement.

Key words: Ridge Augmentation, Autogenous bone graft, Ridge defect

Received: 13 March, 2019

Revised: 10 June 2019

Accepted: 12 June 2019

Corresponding Author: Dr. Sneha S. Puri, (MDS) Reader, Department of Periodontics, Swargiya Dadasaheb Kalmegh Smruti Dental College, Nagpur Maharashtra – 441110

This article may be cited as: Puri S. Ridge Augmentation with autogenous bone graft in anterior region: A case series. J Adv Med Dent Scie Res 2019;7(8): 37-41.

INTRODUCTION:

The partial rehabilitation in the aesthetic zone of the anterior maxilla represents a challenge to the clinician. Loss of teeth in the anterior maxilla results in resorption of alveolar bone from the labial aspect, leaving a palatally positioned alveolar ridge. Teeth in the anterior maxilla are also at risk of traumatic loss and there may be concomitant alveolar ridge defect resulting from the trauma or from surgical removal of roots. Such alveolar ridge defects can adversely affect the final aesthetic results of the restoration. Therefore, ridge augmentation become necessary to achieve, harmonious balance amongst functional, biological and aesthetics before rehabilitation of the anterior maxillary region.

The ridge augmentation procedure, designed to reconstruct the alveolar ridge defects who were introduced in the dental profession between 1971 to 1985 (Abrams L et al 1971, Allen EP et al 1985, Langer B et al 1980)^{1,2,3}. Various techniques have been proposed to correct alveolar ridge

defect. Autogenous bone grafts have been used extensively in the restoration of alveolar ridge defects and continue to be the gold standard for jaw reconstruction (Burchardt et al 1987, Marx et al 1994)^{4,5}. Autogenous bone graft can be harvested from intraoral (Adell et al 1990, Triplett et al 1998)^{6,7} and extraoral sites (Misch and Deitsh et al 1993, Simion et al 2007)^{8,9} donor sites.

Several studies have confirmed that intraoral harvested intramembranous bone grafts particularly from mandibular symphysis region shows on improved quality of bone, less resorption and a shorter healing period compared with extraorally harvested endochondral bone graft (Borstlap et al 1990 ,Misch et al 1997)^{10,11}. However, donor site morbidity , increased operating time , deficiencies in the quality and or quantity of available bone ; limitations in sizes and shape of available grafts and potential for intra-operative and post-operative complications are clinical concerns associated with the use of autogenous bone block (Jensen et al 1994, Hammerle et al 1998)^{12,13}. Therefore the

aim of the present study is to evaluate clinical success of bone augmentation using mandibular bone block obtained from symphysis region fixed by titanium pins to augment a single tooth site in maxillary anterior region.

METHOD AND MATERIAL:

Ten systemically healthy patients with age range of 22 to 30 years having edentulous area with single tooth ridge deformity in maxillary anterior region, adequate bone support, patients requiring esthetic replacement, normal anterior occlusal relationship, and acceptable oral hygiene were included in the study. However patients with proclinated, rotated or mal-aligned teeth, Habit of smoking or use tobacco products, non-compliant to periodontal maintenance programme and history of bruxism were excluded from the study.

Clinical measurements:

1. Alveolar ridge defect measurements

Bucco-lingual ridge defect width was recorded clinically with the help of the manual Williams graduated periodontal probe at baseline and 6 months after ridge augmentation surgery. Alveolar ridge defect width was recorded at 4 sites viz: Crest, 1mm, 3mm & 5 mm apical to the crest of the defect by placing one probe horizontally across the buccal/labial surface parallel to the crest of the ridge and other perpendicular to it.

Surgical Procedure:

Preparation of Recipient site:

Briefly after induction of local anaesthesia (block and infiltration with 1:1,00,000 epinephrine) using a Bard Parker Surgical blade # 15, a mid crestal incision was made slightly palatal to the crest of edentulous site. Vertical divergent releasing incisions were made extending to the vestibule. The papillae of the adjacent teeth were included in the flap design to allow maximum exposure of the surgical site enabling controlled placement of bone block and assisting predictable wound closure. Full thickness mucoperiosteal flap was elevated buccally. The bony crest was curetted to remove all soft tissues. A sterilized piece of tin foil was placed over recipient site as a surgical template. It was manipulated, cut and adjusted to the configuration of bony defect and used for harvesting Autogenous bone block of same size from donor site using a small round bur. The facial cortex was perforated to open up the bone marrow cavity to induce revascularization and influx of growth factors and platelets to enhance bone neogenesis.

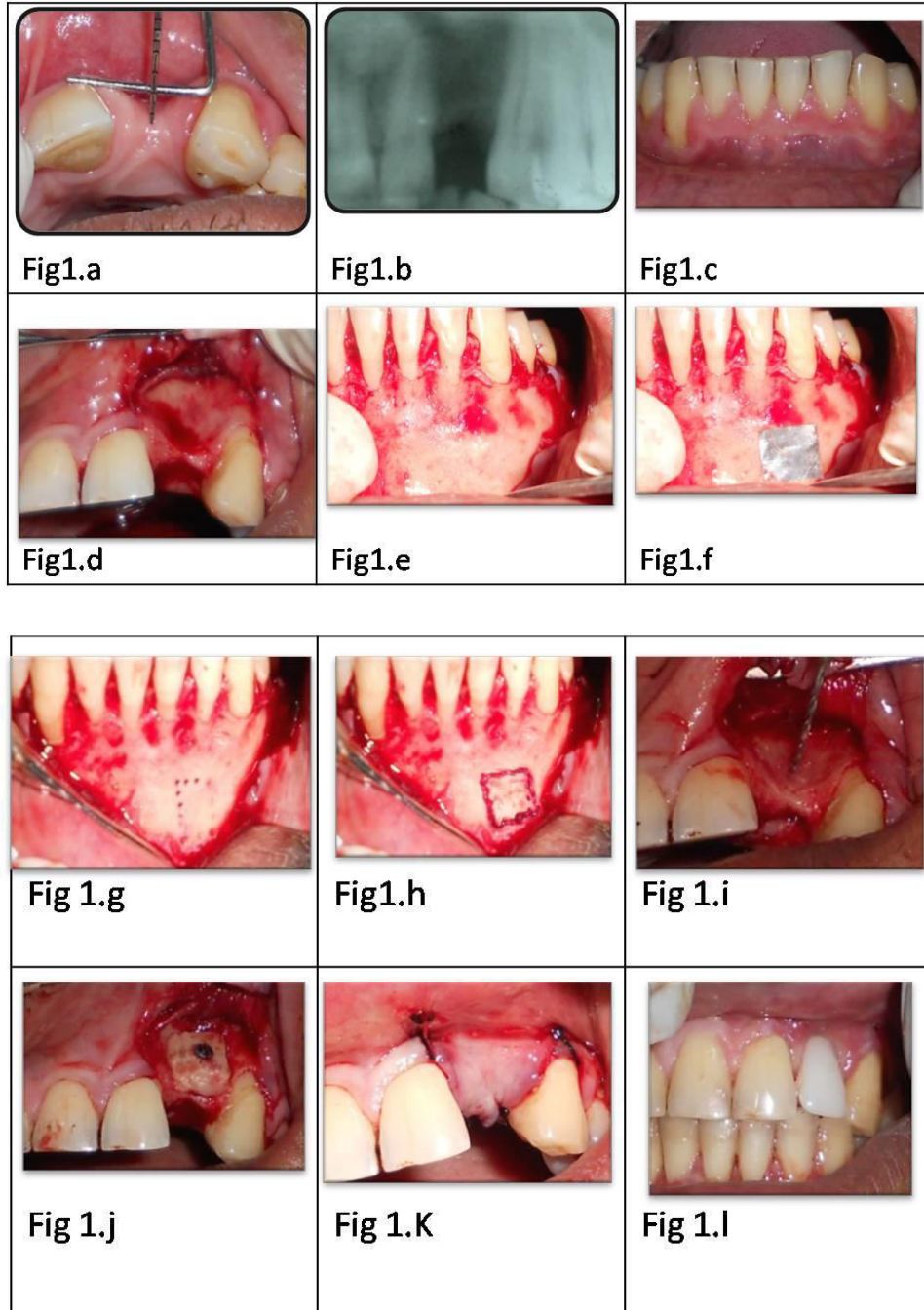
Preparation of Donor site

Briefly after induction of anaesthesia in the symphysis region by inferior alveolar nerve block/ mental nerve block with local anaesthesia (block and infiltration using 2 % Lidocaine with 1:1,00,000 epinephrine) , a curved incision

was made with a Bard Parker blade # 15 apical to the mucogingival line and full thickness flap was reflected to expose the symphysis region. Once the symphysis was exposed, the template was placed over the bony cortex. It was located at least 5 mm away from the inferior border of the mandible, 5 mm from mental foramen, 5 mm from midline spine and 5 mm from the apices of the teeth. The midline spine (protrusion) was preserved to ensure sanctity of the posture of the lower lip and preservation of the labio-mental fold. A ½ round, high speed bur under copious irrigation was used to outline the periphery of the template at a right angle to the bone surface, followed by a 701 surgical-length bur to connect the dot. When the outline was completed the osteotomy was deepened into the marrow space. Tactile sense, as well as bleeding from the outline form indicated penetration into the marrow space. Once this communication was completed, Ochsenbein Chisel was tapped into the outline with a mallet. During tapping phase, patient was asked to clench the teeth in centric occlusion and chin was supported during the tapping phase, which was started in one of the vertical cuts. The inferior osteotomy was avoided or reserved for last to prevent any danger to the border. If during the tapping, the osteotome refuses to advance, it was probable that the marrow space has not been reached. The osteotome might be too thick. After tactile purchase has been achieved around the entire periphery with the osteotome, it was used as a lever to elevate the graft. When some mobility was noted at the first site same strategy was used on the opposite side. This maneuver was employed at a variety of sites until block became mobile. After elevating the graft from the donor site, it was stored in a mixture of saline and the patient's blood, with addition of 80 mg gentamicin. The sharp bony edges at donor site were smoothed and primary wound closure was accomplished with mattress or single interrupted sutures.

Placement of bone block at the recipient site

To maximize success, the graft had to be immobilized, and it should be offered adequate blood supply. The bone block was adapted to the defect site morphology. The flap was undermined to adequately cover the newly grafted area of the recipient site. The bone block and the recipient site were modified to fit as closely as possible at the recipient site. Once this is accomplished, with a spiral drill, the holes for the bone block fixation screw were prepared at the recipient site. One or two screws of diameter 1.5mm were used (1.5mmx8mm, titanium, Orthomax) to stabilize the bone block graft at recipient site. After the graft was secured firmly, voids around the block grafts were filled with cancellous bone graft or bone chips harvested from the donor site. A periosteal releasing incision was made to allow flap mobilization and a tension free primary wound closure. Wound adaptation was accomplished with single interrupted sutures.



RESULTS:

A total of ten systemically healthy patients with age range of 22 to 30 years with single missing teeth associated with Siebert's Class I defect in anterior maxilla were treated with ridge augmentation procedure by using autogenous bone graft. During the course of the study, wound healing was uneventful. None of the above selected patient dropped out before the termination of study. In all sites, the augmented alveolar ridge was covered with oral mucosa. No major complications were observed from donor side.

At 6 months all the bone grafts were successfully incorporated at recipient side. Fixation screws were removed and bleeding from the graft was observed, indicating revascularisation of grafted bone. Analytical data regarding the alveolar ridge defects at base line and again at 6 months.

A mean gain of buccolingual ridge width was 2.9 mm, while apico coronal gain was 2.1 mm was observed at 6 months post-operatively (Table 1).

Table 1

Sr no.	Buccolingual width at the residual crest			Vertical measurement (Apico-coronal width)		
	Baseline	3months post surgery	Alveolar ridge width gain	Baseline	3months post surgery	Alveolar ridge width gain
1	3mm	0mm	3mm	2 mm	0mm	2 mm
2	3mm	0mm	3mm	2 mm	0mm	2 mm
3	2mm	0mm	2mm	2 mm	0mm	2 mm
4	3mm	0mm	3mm	2 mm	0mm	2 mm
5	4mm	0mm	4mm	2 mm	0mm	2 mm
6	3mm	0mm	3mm	2 mm	0mm	2 mm
7	3 mm	0mm	3 mm	3 mm	0mm	3 mm
8	3 mm	0mm	3 mm	2 mm	0mm	2 mm
9	2 mm	0mm	2 mm	2 mm	0mm	2 mm
10	3 mm	0mm	3 mm	2 mm	0mm	2 mm
Mean	2.9 mm	0 mm	2.9 mm	2.1 mm	0 mm	2.1 mm

DISCUSSION:

An inadequate alveolar ridge or ridge deformity is frequently encountered that affect esthetics and the restoration outcome. Clinical esthetic problems arise when replacing missing teeth in maxillary anterior region because of exposure of the cervical area of the teeth and the surrounding soft tissue environment. Therefore, augmentation of alveolar ridge defect becomes more important in terms of aesthetic restoration and to provide sufficient bone volume for the placement of the prosthesis. Therefore the aim of the present study is to evaluate clinical success of bone augmentation using mandibular bone block obtained from symphysis region fixed by titanium pins to augment a single tooth site in maxillary anterior region.

In the present study, alveolar ridge width was measured at baseline and at 6 months after ridge augmentation procedure to determine the changes in alveolar ridge width. A mean gain of buccolingual ridge width was 2.9 mm, while apico coronal gain was 2.1 mm was observed at 6 months post-operatively, Von Arx & Buser 2006¹⁴ reported mean gain in the alveolar ridge width of 4.6 mm by using autogenous bone graft in combination with collagen membrane.

Autogenous bone grafts have been used extensively in the restoration of alveolar atrophy and repair of bone defects and continue to be the gold standard for jaw reconstruction^{9,10}. Autogenous bone graft can be harvested from extraoral (Triplett 1996)¹⁵ or intraoral (Misch et al 1993, Simion et al 2007)^{16,17} donor sites. Several studies have confirmed that intraoral harvested intramembranous bone grafts, in particular mandibular bone graft, when compared with extraorally harvested endochondral bone graft (Borstlap et al 1990, Misch et al 1997)^{10,11} results in an improved quality of bone with a shorter healing period. Bone harvested from the mandible appears to have inherent biologic benefits attributed to its embryologic origin (Avery 1994)¹⁸. Experimental evidence suggests that graft from membranous bone show less resorption than endochondral bone (Lin et al 1990)¹⁹. Although cancellous

graft revascularize more rapidly, than cortical grafts, cortical membraneous grafts revascularize more rapidly than endochondral bone grafts with a thicker cancellous compartment. This early revascularization of membraneous bone grafts is possible explanation for the improved maintenance of graft volume. It may explain why mandibular bone graft, which are primarily cortical bone and contribute few osteogenic cells, exhibit little volume loss and show good incorporation at shortest healing time (Jensen et al 1994, Smith and Abramson 1974)^{12,20}. Others theorize that the improved survival of membraneous bone graft is due to their 3 dimensional structures (Manson et al 1994)²¹. Since, the symphysis region is a source of cortical and cancellous bone that can be used as a predictable donor site and technique of harvesting bone is significant as well as beneficial procedure, in the present study autogenous block was obtained from symphysis region of the mandible.

CONCLUSION:

The present case series study indicates successful reconstruction of both horizontal & vertical ridge defect using mandibular bone block at the site of single implant placement.

REFERENCES:

1. Abrams L. Esthetics in fixed prosthesis. Presentation before the Harrisburg (Pennsylvania) Dental Society; November 1971.
2. Allen EP, Gainza CS, Farthing GG, Newbold DA. Improved technique for localized ridge augmentation. A report of 21 cases. J Periodontal 1985 Apr;56(4): 195-199.
3. Langer B, Calagna L. The subepithelial connective tissue graft. J Prosthet Dent 1980 Oct;44(4):363-367.
4. Burchardt H. Biology of bone transplantation. Orthop Clin North Am. 1987;18:187-195
5. Marx RE. Biology of Bone graft .Oral And Maxillofacial Surg Knowl Update 1994 ;1:RCN 1-17.
6. Adell R, Lekholm U, Grondahl K, Branemark PI, Lindstrom J, Jacobsson M. Reconstruction of severely resorbed edentulous maxillae using osseointegrated fixtures in

- immediate autogenous bone grafts. *Int J Oral Maxillofac Implants*. 1990 Fall;5(3):233-246.
7. Triplett RG, Schow SR. Autologous bone grafts and endosseous implants: complementary techniques. *J Oral Maxillofac Surg*. 1996;54:486-494.
 8. Misch CE, Dietsch F. Bone-grafting materials in implant dentistry. *Implant Dent* 1993;2:158-167.
 9. Simion M , Fontana F , Rasperini G , Maiorana C. Vertical ridge augmentation by expanded –polytetrafluoroethylene membrane and a combination of intraoral autogenous bone graft and deproteinized anorganic bovine bone. (Bio-Oss). *Clin Oral Implants Res* . 2007;18:620-629
 10. Borstlap WA, Heidebuchel KL, Freihofer HP, Kuijjoers-Jagtman AM. Early secondary bone grafting of alveolar cleft defects. A comparison between chin and rib grafts. *J Craniomaxillofac Surg*.1990;18:210-205
 11. Misch CM. Comparison of intraoral donor sites for onlay grafting prior to implant placement. *Int J Oral Maxillofac Implants* 1997; 12:767-776.
 12. Jensen J, Sindet-Pedersen S, Oliver AJ. Varying treatment strategies for reconstruction of maxillary atrophy with implants: results in 98 patients. *J Oral Maxillofac Surg* .1994;52(3):210-216; discussion 216-218.
 13. Hammerle CH, Chiantella GC, Karring T, Lang NP. The effect of a deproteinized bovine bone mineral on bone regeneration around titanium dental implants. *Clin Oral Implants Res* 1998;9(3): 151-162.
 14. Von Arx T, Buser D. Horizontal ridge augmentation using autogenous block grafts and the guided bone regeneration technique with collagen membranes: a clinical study with 42 patients. *Clin Oral Implants Res* 17, 2006; 359-366.
 15. Triplett RG, Schow SR. Autologous bone grafts and endosseous implants: complementary techniques. *J Oral Maxillofac Surg*. 1996;54:486-494.
 16. Simion M , Fontana F , Rasperini G , Maiorana C. Vertical ridge augmentation by expanded –polytetrafluoroethylene membrane and a combination of intraoral autogenous bone graft and deproteinized anorganic bovine bone. (Bio-Oss). *Clin Oral Implants Res* . 2007;18:620-629
 17. Borstlap WA, Heidebuchel KL, Freihofer HP, Kuijjoers-Jagtman AM. Early secondary bone grafting of alveolar cleft defects. A comparison between chin and rib grafts. *J Craniomaxillofac Surg*.1990;18:210-205
 18. Avery JK, development of cartilages and bones of facial skeleton .Avery JK ,ed , *Oral Development and Histology*, New York, NY : Thieme Medical Publisher 1994:42-56
 19. Lin KY,Bartlett SP, Yaremchuk MJ ,et al .The effect of rigid fixation on the survival of onlay bone grafts : An experimental study . *Plast Reconstruct Surg* 1990;86:449-456
 20. Smith JD, Abramson M. Membranous vs endochondral bone autografts. *A Otolaryngol*.1974;99:203-205
 21. Manson PN. Facial bone healing and bone grafts.A review of clinical physiology. *Clin Plast Surg* 1994;21:331-348