

Case Report

Surgical Lip Repositioning: A Compelling Procedure to reduce Gingival Display

Anuj Singh Parihar

Senior Lecturer, Department of Periodontics, RKDF Dental College & Research Centre, Bhopal - 462027, Madhya Pradesh, India

ABSTRACT:

Excessive gingival display or 'Gummy smile' is an aesthetic concern of an individual, affecting the overall personality. It can be predictably managed by Orthognathic surgery and Orthodontic treatment. The purpose of present article is to report an alternative and comparatively less invasive surgical procedure 'Lip repositioning' to treat 'gummy smile'. This case report discusses a 26 years Indian male patient presented with Excessive gingival display. On examination, dynamic smile was extending from maxillary right first molar to maxillary left first molar, with 4 to 5mm of excessive gingival display with normal maxillary anterior anatomic proportions. A comprehensive treatment plan was made which includes Scaling and Root planing followed by Lip positioning procedure to correct excessive gingival display. The purpose of presenting this case is to describe an alternative treatment modality for treatment of excessive gingival display.

Key words: Gummy line, lip Repositioning.

Received: 19 April 2018

Revised: 27 April 2018

Accepted: 12 May 2018

Corresponding author: Dr. Anuj Singh Parihar, Senior Lecturer, Department of Periodontics, RKDF Dental College & Research Centre, Bhopal -462027, Madhya Pradesh, India

This article may be cited as: Parihar AS. Surgical Lip Repositioning: A Compelling Procedure to reduce Gingival Display. J Adv Med Dent Scie Res 2018;6(6):27-29.

INTRODUCTION:

Imbalance in the gingiva- tooth ratio results in predominant gingival appearance referred as "gummy smile." A normal gingival display between the inferior border of the upper lip and the gingival margin of the central incisors during a normal smile is 1-2 mm. In contrast, if the distance is 4mm or more between excessive gingiva to lip then it is classified as unattractive.

Excessive gingival display is a common cause of patients. Patients complain of "gummy smile".¹ Very often in our daily practice we come across patients with chief complaint of gummy smile. Therefore, the clinician need to evaluate the patient's smile, and also consider the relationship between the patient's dentition, gingiva, and lip while smiling.²

Etiological factors resulting in gummy smile can be: Hyper muscular function of upper lip and Skeletal vertical maxillary excess (VME)- it is due to overgrowth of maxillary bone, which enlarges vertical dimension of mid face and results in short lip, treatment ranges from Orthognathic surgery, Le fort I osteotomy, Crown

lengthening, Intrusion, Myectomy to muscle resection. Whenever there is increased maxillary vertical excess, orthognathic surgery is the choice of treatment.³ But in recent years lip repositioning and botox treatment are used to treat gummy smile.⁴

CASE REPORT:

A 26 yrs male patient came with a chief complaint of excessive gingival display (figure 1). The treatment goal was to minimize gingival display in patients smile. The patient's medical history was non contributory, and there were no contraindications to surgical treatment. A clinical examination revealed excessive gingival display. With an exaggerated smile, the patients teeth and gingiva was visible from maxillary right first molar to maxillary left first molar, with 4 to 5mm of excessive gingival display with a normal maxillary anterior anatomic proportions. Informed consent was obtained before starting the procedure.

Pre operative measurements were made to check the smile line (which was measuring around 19mm). Local anesthetic (Local anesthetic (Xylocaine 2% with

epinephrine, 1:100,000, and epinephrine,1:50,000; Dentsply) was administered in the vestibular mucosa and lip from maxillary right to left first molar. A marking pencil was used to outline the incisions on the dried tissues (figure 2). A partial-thickness incision was made at the muco-gingival junction from the right first molar to the left first molar, second partial thickness incision was made parallel to the first incision in the labial mucosa, 10 to 12mm apical to the muco-gingival junction (figure 3). The incisions were connected at each first molar creating an elliptical outline of the incisions, leaving the underlying connective tissue exposed (figure 4, 5). Care was taken to avoid damaging minor salivary glands in the sub-mucosa. Local anesthetic and electro coagulation were used to control bleeding. The parallel incision lines were approximated with interrupted sutures (vicryl 4-0) at the midline and other locations along the borders of the incision to ensure proper alignment of lip midline with the midline of the teeth (figure 6). Then interrupted sutures were continued on the either sides to approximate both flap ends.

Non steroidal anti-inflammatory drugs (ibuprofen 600mg 3 times daily for 3 days after surgery. Post operative instruction - ice pack application, to minimize lip movements when smiling and talking for 1 week. Post operative healing occurred with minimal of ecchymosis and discomfort. The patient reported pain when smiling after surgery for 1 week. Sutures were removed 2 weeks later. The sutures line healed in the form of scar that was not apparent when the patients smiled, because it was concealed in the upper lip mucosa. 2 weeks later showed reduction in patient's excessive gingival display (figure 7). Post operative smile line was measured and it was measuring 24mm (figure 8).

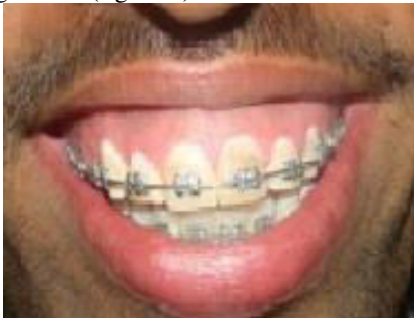

Figure 1: Pre operative smile

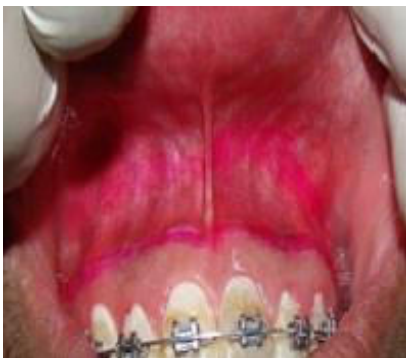

Figure 2: Incision marked using marking pencil

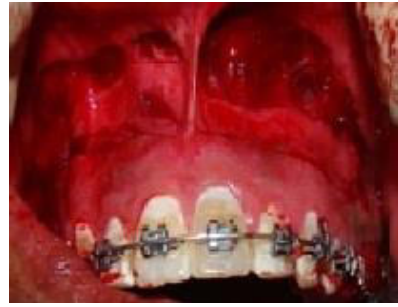


Figure 3: Two incisions

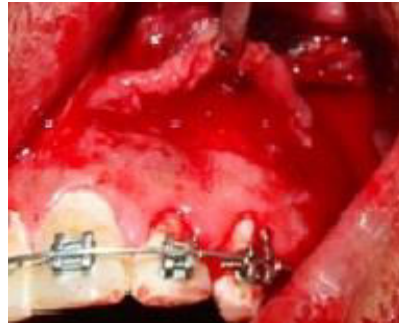


Figure 4: Epithelial layer being removed

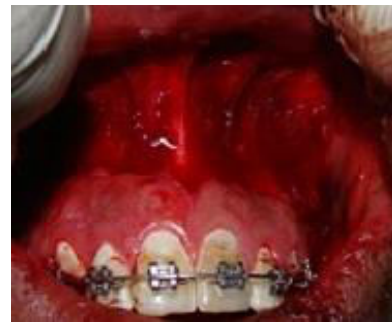

Figure 5: Partial thickness exposing underlying connective tissue

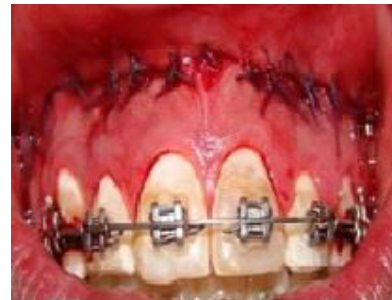

Figure 6: Interrupted sutures in place

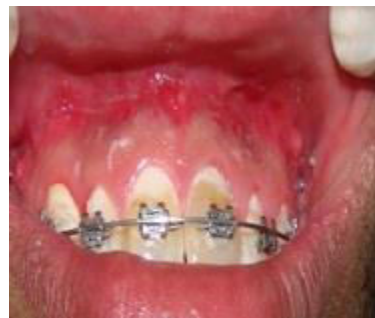

Figure 7: Healing after 2 weeks

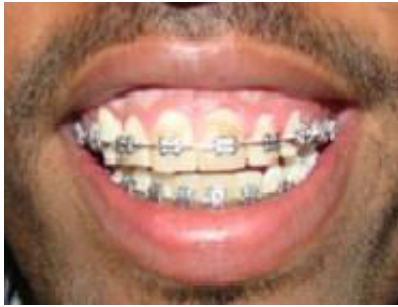

Figure 8: Post operative picture

DISCUSSION:

Patient who have a high lip line exposes a zone of gingival tissue. In this form of the lips, the dentist can modify/ control the form of the teeth, the position of the gingival margins and the incisal edges of the teeth along with repositioning of the lip. It is possible by a interdepartmental approach, to improve dento-facial esthetics. Successful clinical outcome of lip repositioning technique was achieved in this case. Crown length was appropriate and did not require any crown lengthening.

This clinical report describes the use of lip repositioning for the reduction of excessive gingival display. For an excessive gingival display according to VME classification degree II, III orthognatic surgey is preferred.² But in patients who are not willing for orthognatic surgery an alternative treatment is lip repositioning.⁵ This technique is an easy and less time consuming cost-effective way to give satisfactory results to the patient. Contraindications of lip repositioning includes minimal zone of attached gingiva, thereby creating difficulties in flap design, stabilization and suturing, and severe vertical maxillary excess.

CONCLUSION:

Lip repositioning has emerged as an innovative and effective way to improve the gummy smile of a patient. This technique is an easy and less time consuming cost-effective to give satisfactory results to the patients. This procedure minimizes gingival display by placing the upper lip in a more coronal position. The evidence gives stable results in patients who are not willing to undergo orthognatic surgery. But careful diagnosis and case selection are the important factors in the successful outcomes.

REFERENCES:

1. Rosenblatt A, Simon Z. Lip Repositioning for Reduction of Excessive Gingival Display: A Clinical Report. *Int J Periodontics Restorative Dent* 2006;26:433-437.
2. Garber DA, Salama MA. The aesthetic smile: Diagnosis and treatment. *Periodontol* 2000 1996;11:18-28
3. Jananni M, Sivaramakrishnan M, Libby T. Surgical correction of excessive gingival display in class I vertical maxillary excess: Mucosal strip technique. *J Nat Sc Biol Med* 2014;5:494-498.
4. Polo M. Botulinum toxin type A (Botox) for the neuromuscular correction of excessive gingival display on smiling (gummy smile). *Am J Orthod Dentofacial Orthop* 2008;133:195-203.
5. Gaddale R, Desai SR, Mudda JA, Karthikeyan I. Lip repositioning. *J Indian Soc Periodontol* 2014;18:254.

Source of support: Nil

Conflict of interest: None declared

This work is licensed under CC BY: *Creative Commons Attribution 3.0 License*.