

# REVIEW ARTICLE

## HUMAN PAPILOMA VIRUS AND ORAL SQUAMOUS CELL CARCINOMA- AN UPDATE

<sup>1</sup>Archana Lanje, <sup>2</sup>Rajat Misurya, <sup>3</sup>Dilip Gadewar, <sup>4</sup>Manisha Tijare, <sup>5</sup>Shradha Chaoji, <sup>6</sup>Nitin Bhola

<sup>1</sup>Professor and Head, Oral Pathology MPCD and RC Gwalior, Madhya Pradesh, India, <sup>2</sup>Professor, Maharani Laxmi Bai Medical College, Jhansi, Uttar Pradesh, India, <sup>3</sup>Professor and Head, Oral Pathology, New Horizon Dental College and Research Institute, Sakri, Bilaspur, Chhattisgarh 495001, <sup>4</sup>Prof and Head, Oral Pathology RRD College Akola, <sup>5</sup>Oral Pathology, Aurobindo College Of Dentistry, Indore, <sup>6</sup>Professor, Department of Oral Surgery, DIMMS Sawangi Wardha


### ABSTRACT:

Human papillomavirus (HPV) contamination is the most usually analyzed sexually transmitted disease. HPV contamination has been etiologically connected with condyloma acuminatum, squamous intraepithelial lesions, and anogenital malignancy, including cervical, vaginal, vulval, penile, and anal carcinoma. Numerous patients with oropharyngeal squamous cell carcinomas, especially those emerging in the base of the tongue and in the tonsillar district, don't have the conventional hazard factors related with head and neck malignancies (eg, smoking, smokeless tobacco, liquor utilization). Epidemiologic and atomic examinations have recognized the HPV-16 genotype of HPV as a causative specialist in a hefty portion of these patients. Other high-hazard HPV genotypes, for example, HPV-18, 31, or 33, are likewise causative yet are less normal. These high-hazard HPV contaminations may likewise seldom cause tumors at other head and neck sites. The part of HPV disease in head and neck squamous cell carcinoma is discussed here.

**Key words:** HPV, Cancer, Oral squamous cell carcinoma.

Corresponding author: Dr. Archana Lanje, Professor and Head, Oral Pathology MPCD and RC Gwalior, Madhya Pradesh, India

This article may be cited as: Lanje A, Misurya R, Gadewar D, Tijare M, Chaoji S, Bhola N. Human papilloma virus and oral squamous cell carcinoma- An update. J Adv Med Dent Sci Res 2017;5(7):26-31.

Access this article online	
<b>Quick Response Code</b> 	Website: <a href="http://www.jamdsr.com">www.jamdsr.com</a>
	DOI: 10.21276/jamdsr.2017.5.7.07

### INTRODUCTION:

HPV are little deoxyribonucleic acid (DNA) infections that are generally circulated in vertebrates. These infections contain 8 kilobase long, twofold stranded, circular DNA genome. The papillomavirus genome involves early and late qualities that encode early proteins E1-E7 and late proteins L1-L2. The early proteins are nonstructural proteins required in replication and interpretation of the genome (E1-E5) or in have cell tumoral change (E6 and E7), while L1 and L2 are the auxiliary capsid proteins of the virion. The HPV E6 and E7 oncogenes encode proteins comprising of around 151 and 98 amino acids, separately. These qualities are to a great extent in charge of the onset and determination of the harmful procedure in both head and neck and anogenital tumors.<sup>1,2</sup>

The inclusion of human papillomavirus (HPV) in head and neck carcinogenesis was first recommended by Syrjanen in 1983.<sup>3,4</sup> The rising occurrence of oropharyngeal disease, particularly oropharyngeal squamous cell carcinoma

(OSCC) related with human papillomavirus (HPV), is a noteworthy worry for the medicinal services group. Over the past quarter-century, HPV disease has turned out to be solidly settled as an etiologic hazard factor for growths of the oropharynx, particularly those of the tonsils and the base of the tongue.<sup>5</sup>

Most by far (~80 to 90%) of HPV-positive oropharyngeal tumors are related with HPV-16 and HPV-18, two high-chance, HPV sorts that are normally connected with cervical disease and other anogenital malignancies.<sup>6</sup> HPV contamination does not have all the earmarks of being a noteworthy hazard factor for disease of the front 66% of the tongue or remaining locales in the oral cavity.<sup>7,8</sup> HPV-positive squamous cell carcinomas have been recognized in the oral cavity, in spite of the fact that their event is moderately low.

Squamous cell carcinoma accounts for 90% of all oral cancers. It may affect any anatomical site in the mouth, but most commonly the tongue and the floor of the mouth. It usually arises from a pre-existing potentially malignant lesion, and occasionally de novo; but in either case from

within a field of precancerized epithelium. Epidemiological examinations have watched an expanded frequency furthermore, relative hazard for squamous cell carcinomas of the head and neck (HNSCC ) among subjects at first giving cervical cancer.<sup>9,10</sup> Research in this manner has centered upon regular etiologic factors, for example, smoking and disease with HPVs. Loning et al.<sup>11</sup> first proposed a relationship amongst HPV and HNSCC in 1985, and confirmation of a conceivable affiliation has since been expanding. To be sure, these proteins and consequent cell cycle interruption have been illustrated in HNSCC.<sup>12-16</sup> Past examinations have revealed the presence of HPV type 16 and 18 in oropharyngeal tumors. Evaluations of HPV predominance in HNSCC tumors differ with the location technique utilized also, the nature of tissue conservation.<sup>17,18</sup> DNA from new tumor tissue subjected to PCR enhancement of the L1 or E7 viral district has the most noteworthy announced discovery rate.<sup>19</sup>

However data on other hazard factors, for example, tobacco utilize what's more, liquor utilization have regularly been inadequate in these reports. Anatomical destinations and patient qualities, for example, age, sexual orientation, clinical stage, smoking, and liquor utilization have been dynamically revealed as related with HPV recognition.

**EPIDEMIOLOGY:**

A precise survey of HPV related head and neck squamous cell carcinoma (HNSCC) found a pervasiveness of 27%. The commonness was higher in oropharyngeal squamous cell carcinoma (OPSCC) contrasted with oral and laryngeal SCC.<sup>20</sup> The ethnicity and geographic starting point of patients are known to be in charge of contrasts in HPV pervasiveness in HNSCC. The high pervasiveness of HPV in Asiatic patients with oral growths infers that viral disease might be a vital etiological specialist and alongside dietary propensities and a plausible hereditary inclination can cause extra changes prompting threat. The most reduced commonness of HPV-positive HNSCC was in Africa. A few examinations show that HPV disease of the oral cavity and pharynx is a sexually transmitted disease. A solid relationship between sexual conduct and danger of oropharyngeal growth and also HPV 16-positive HNSCC has been illustrated. It has moreover been accounted for that oral sexual movement and surprised kissing are related with the advancement of oral HPV disease. There is an expanded danger of optional pharyngeal disease in patients treated with or without radiotherapy for cervical disease. there is confirmation of an expanding frequency in HPV-positive HNSCC. Signs of HPV-positive HNSCC as an irresistible sexually transmitted illness exist, in spite of the fact that transmission of HPV in different routes as, for case, from mother to child either in utero or amid delivery can't be discounted.

**MECHANISM OF HPV INDUCED ORAL CANCER:**

In humans, more than 70 types have been described. According to epidemiological case-control studies, 15 high-risk HPV types have been recognized (types 16, 18, 31, 33, 35, 39, 45, 51, 52, 56, 58, 59, 68, 73, and 82), while 3 types have been nominated as probable high-risk (types 26, 53, and 66) and 12 types have been classified as low-risk.

The possibility of evolving into direction of malignancy depends on the type of virus, the synergic action with different physical, chemical, and biological agents, the genetic constitution, and the immune defense mechanisms of the host, all of which are able to modify the course of HPV infection. In the case of high-risk HPV infection and under favorable conditions, the viral genome is integrated into the host genome, which is the necessary event for the keratinocytes immortality. It is identified initially as sexually transmitted agents, now considered human carcinogens. Functionally high risk HPV infection contributes to carcinogenesis and tumor progression predominantly through the actions of two viral oncogenes, E6 and E7. Both of these oncogenes interact with and inhibit the activities of critical components of cell cycle regulatory systems, in particular E6 with p53 and E7 with Rb. The E7 protein interacts with pRB and inactivates this cellular protein. As a consequence, E2F transcription factor is released from pRB-E2F complex, leading to transcriptional activation of several genes involved in cell proliferation. Binding of the E6 protein to the p53 promotes the degradation of the latter through a ubiquitin-dependent proteolysis system. Also of significance is that on completion of the degradation of p53 by the ubiquitin-dependent proteolysis system, the E6 protein is free to interact again with remaining p53 molecules, leading to further degradation of the latter. The products of genes E6 and E7 are essential in the process of HPV induced cellular immortalization and transformation. The variants are thought to differ in their biological properties and in their contribution to carcinogenesis. The different type of viruses are characterised by genotypic variations in DNA base sequences of E6 and E7. It is this genotypic variation that permits stratification of virus oncogenic phenotype into high, intermediate and low risk types. E.g. E7 protein of HPV 16 is more oncogenic than E7 protein of HPV 6.<sup>13-21</sup>

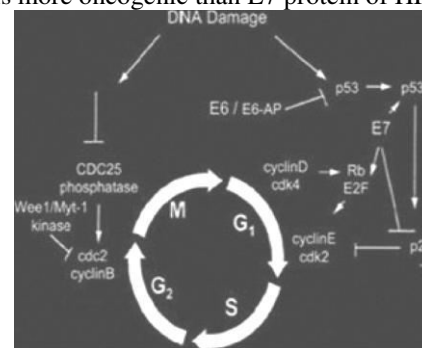


Figure 1: A model explaining the interaction of HPV E6 and E7 with tumor suppressor genes functioning in cell cycle

### **RISK FACTORS:**

Hazard factors for oral and oropharyngeal tumors have ordinarily been more established age (middle age 60 years at conclusion) and the utilization of tobacco and extreme liquor utilization. Be that as it may, in view of the accessible confirmation, HPV contamination is presently viewed as an approved hazard factor for OSCC in the men and women, even without smoking and liquor consumption.<sup>21,22</sup> Oropharyngeal growths related with HPV have chance components for example, more number of sexual accomplices, oral-genital sex, also, oral-anal sex. Marijuana is a free hazard factor for HPV-positive HNSCC, and the hazard increments with the force, span, and combined years of marijuana smoking. Given this developing proof, it has been recommended that utilization of prophylactic HPV antibodies coordinated against HPV-16 and HPV-18 disease may lessen OSCC frequency. Toombak, a type of snuff, is related with oral tumor in Sudan.<sup>23</sup> 47% of oral squamous carcinomas were certain for HPV. Currently, the industrially accessible HPV antibodies are FDA-endorsed for the anticipation of HPV-related growths of the cervical, vulvar, vaginal and anal mucosa.

### **SIGNS AND SYMPTOMS:**

Oral lesions are asymptomatic at first, featuring the requirement for oral screening. Most dental experts deliberately inspect the oral cavity and oropharynx amid routine care and may do a brush biopsy of strange territories. The injuries may show up as zones of erythroplakia or leukoplakia and might be exophytic or ulcerated. Growths are regularly indurated and firm with a moved fringe. As the lesions increase in size, pain, dysarthria, and dysphagia may come about. The warts related with most HPV diseases leave all alone with no signs or side effects. In any case, the infection is still in a contaminated individual's body. Subsequently, that individual may accidentally pass HPV to sexual partners. When the infection doesn't leave all alone, it can cause genuine medical issues. These incorporate genital warts and warts in the throat (known as intermittent respiratory papillomatosis). The types of HPV that causes warts are not the same as that causes tumor. In that capacity, having genital warts caused by HPV doesn't imply that you'll create cancer. Cancers caused by HPV frequently don't demonstrate indications until the point that the disease is in later phases of development. General screenings can help analyze HPV-related medical issues prior. This can enhance standpoint and increment odds of survival.

### **CLINICAL FACTORS:**

HPV-positive oral cancer happens in more youthful age gather as contrasted with HPV-negative malignancies with a normal age contrast of 5–10 years. HPV-positive patients likewise have higher wage and more years of education. The male : female proportion is 5 : 1. HPV related malignancies more often than not give littler essential

tumors however more progressed nodal stage.<sup>24</sup> Cystic metastatic neck nodes have been revealed and now and again the tumor can show asmetastatic nodal infection with obscure essential. Numerous patients give a tumor of the neck, with the inception of the tumor initially being analyzed when a symptomatic tonsillectomy is performed during the time spent disentangling the unknown primary tumor.

The course of oral SCC is unpredictable, but the TNM stage (T-tumour size, N-nodal metastasis, M-distant metastasis) of the primary tumour correlates well with the survival rate. The forecast is best when the essential tumor is little and there is no proof of local lymphnode contribution or far off metastasis. Actually, the 5-year survival rate of people with beginning time oral SCC as indicated by the TNM organizing framework may achieve 80% - 90% , though the five-year survival rate for cutting edge arrange oral SCC is around 40% .

Around 66% of oral SCC are now of generous size, and will have clinically perceivable metastases to cervical lymphnodes at the time of analysis. The influenced lymphnodes are firm and non-delicate to palpation, and if extracapsular spread into the encompassing connective tissue has happened, they will be settled and tangled. Vitaly, in around 20% - 40% of cases with no clinical or imaging confirmation of metastatic spread to lymphnodes at the season of analysis of oral SCC. The identification of HPV-related SCC by cytology and by ISH of fine needle aspirate of cervical metastasis could be an essential apparatus for recognizing the site of origin of an unknown primary tumor with cervical lymph nodes to the neck . The nonkeratinizing SCC in metastatic cervical lymph nodes anticipated positive HPV-ISH and was emphatically suggestive of an oropharyngeal primary tumor. These tumors are frequently basaloid what's more, inadequately separated.

### **HISTOPATHOLOGY**

The pathologic elements of HPV-positive tumors are distinctive from HPV-negative tumors in the accompanying:

1. They are not related with surface dysplasia or keratinisation.
2. They have penetrating lymphocytes
3. They display lobular development.
4. Basaloid variations are normal.

HPV-positive tumors are normally all around separated and the basaloid tumors have great visualization.

### **DIAGNOSIS:**

Early detection of oropharyngeal tumor altogether expands the five-year survival rate. Although malignancies of the oropharynx are hard to picture and are analyzed at later stages than those of the oral cavity, people with HPV-constructive oropharyngeal cancer have a lower danger of passing on or having repeat than those with HPV-antagonistic cancers.<sup>25</sup> The patient's wellbeing history,

especially any verbal or composed sign of at first suggestive side effects, for example, determined sore throat, dysphagia, raspiness, ear torment, augmented lymph nodes or weight reduction, ought to be precisely assessed as a feature of the full clinical appraisal and head and neck examination. Patients with at first suggestive side effects ought to likewise be alluded for medicinal assessment and development. Likewise, dental specialists should keep on providing exhortation and direction to their patients in regards to the known dangers for oral and oropharyngeal diseases from smoking and overwhelming liquor utilization. The basic techniques being utilized as a part of finding of HPV are viral DNA location with polymerase chain response (PCR) or, then again In Situ Hybridization and p16 location by immunohistochemistry.<sup>26</sup> Intensification of target DNA successions by PCR took after by hybridization with committed tests is the commonest technique for HPV location and genotyping. A current report utilized three methods together to decide the HPV impact on event of HNSCCs. They utilized a blend of p16 immunohistochemistry, Consensus PCR HPV DNA, and In Situ Hybridization to better distinguish HNSCCs caused by HPV. All the HNSCCs which were HPV-positive by PCR and additionally ISH were likewise p16 positive by immunohistochemistry (IHC), with IHC showing a high affectability as single test (100% in both OSCC and OPSCC) however bring down specificity.<sup>27</sup>

Antibodies to HPV can be identified in the serum and is a measure of the total introduction of a person to HPV disease. Antibodies against HPV16 L1 and E6 were discovered all the more every now and again in oropharyngeal diseases as contrasted with oral malignancies. Antibodies against HPV16 E6 or E7 were found in 65% of patients with HPV16 positive malignancies of the oropharynx.<sup>28</sup> Consequently, these can be utilized as markers of HPV without fitting cytologic or histologic markers compared to tissue. Immune response diminishes in HIV patients and HPV location rates are said to be higher. Other regular methods utilized for analysis incorporates; Biopsy, Endoscopy to distinguish second primary cancer, Chest x-ray and CT of head and neck

Any suspicious ranges ought to be biopsied. Incisional or brush biopsy should be possible relying upon the specialist's inclination. Coordinate laryngoscopy and esophagoscopy are done in all patients with oral cavity disease to reject a concurrent second primary tumor. PET/CT has started to assume a bigger part in the assessment of patients with oral cavity malignancy. Women ages 30 to 60 ought to be screened like clockwork with Pap and HPV tests in the meantime. In case you're more youthful than the age of 30, your specialist or gynecologist may likewise ask for a HPV test if your Pap spread outcomes are anomalous.

#### **PREVENTION AND TREATMENT:**

The general point of growth anticipation is to decrease the occurrence of the malady; and of malignancy control is to

identify the ailment in its underlying stages and to expeditiously initiate viable and proficient treatment.<sup>29</sup> Measures guided at general society to lessen the frequency of oral SCC and to alarm those at hazard to the regale of early identification ought to incorporate instruction about the risk factors related with the infection, about the early signs and side effects of the sickness, and about the perils of postponing looking for proficient counsel. Proficient measures ought to incorporate the making accessible of prompt viable and effective medicinal treatment, and of screening programs for high-hazard populaces with a perspective of distinguishing conceivably harmful oral issue, or early SCC.

The treatment of oral SCC for the most part requires the administrations of a multidisciplinary group, the essential point of treatment continually being to kill the growth, to forestall repeat, and seeing that is conceivable to reestablish the frame and capacity of the influenced parts. The choice of a particular treatment methodology is directed by the idea of the carcinoma and by the general state of the patient. Remarkable components identified with the carcinoma incorporate the particular site influenced, the clinical size, the degree of nearby intrusion, histopathological highlights, provincial lymphnode inclusion and removed metastasis. Persistent elements incorporate age, general wellbeing status, a past filled with already treated oral SCC and high-hazard propensities.<sup>30</sup>

An assortment of modalities are accessible for the treatment of oral SCC. These incorporate extraction/resection, radio-treatment, systemic cytotoxic chemotherapy and obstructing of epithelial development factor receptor (EGF-R), or a mix of these, either simultaneously or in a systematic succession. Surgery is the favored first line treatment of little, open oral SCCs. Notwithstanding, propelled arrange oral SCC is typically treated by a joined treatment program of surgery, chemotherapy, and radiotherapy.<sup>31</sup> In instances of intermittent oral SCC, EGF-R inhibitor combined with chemoradiotherapy, is the main line of treatment.

Surgical resection of oral carcinoma with tumor free edges of under 5 mm might be trailed by neighborhood repeat and conceivably by removed metastasis, and more often than not requires the organization of post-surgery chemoradiotherapy. The significance of the nearness of dysplastic epithelium in post-resection without carcinoma edges is of far from being obviously true significance, however it is not normally thought to be a solid sign for facilitate treatment.<sup>32</sup>

Twenty to thirty percent of instances of resection of oral SCC with adequate, wider than 5 mm, without tumor edges as confirm on histopathological examination will create nearby or coterminous provincial "repeat".<sup>33</sup> There are two conceivable clarifications for this high rate of repeat. Right off the bat, some carcinomatous keratinocytes may have stayed in the edges of the surgical injury, but since there were so few, they were not identified by histopathological examination; also, the expansive field of precancerized

epithelium including precancerous keratinocytes at various phases of change from which the essential carcinoma created, was not evacuated at the surgical strategy. Epithelium from a field of precancerization may seem typical minutely, or it might be dysplastic. It might likewise seem typical minutely, however by the by may harbor keratinocytes with cytogenetic adjustments including loss of heterozygosity and p53 transformations, or epigenetic changes in methylations of specific promoters of tumoursuppressor qualities and DNA repair qualities. Following securing of extra hereditary modifications, either keratinocytes in the dysplastic epithelium or the hereditarily changed keratinocytes may wind up noticeably destructive offering ascend to another field carcinoma near where the essential carcinoma had been extracted making an impression of repeat.

Accordingly, the return of SCC in the prompt or general region of the essential oral SCC, might be a repeat if the two carcinomata display indistinguishable hereditary profiles; might be another field carcinoma from a subclone of cells inside the field if the hereditary profiles of the two malignancies are comparable, yet not indistinguishable; or might be another essential carcinoma from an alternate clone inside a similar field of precancerization if the hereditary profile of the two tumors are disparate.<sup>34</sup>

It would be incredibly beneficial on the off chance that it were conceivable to treat a field of precancerized oral epithelium. Notwithstanding, as markers which anticipate with any level of conviction movement of precancerized epithelium to SCC have not yet been distinguished, and as just 30% of patients with essential oral SCC will build up a moment field tumor, any sort of treatment of a precancerous field is probably going to be hurtful to those 70% of patients, who were not going to create "neighborhood repeat.

## CONCLUSION:

Oral SCC emerges from inside a field of precancerous epithelium either from a prior conceivably malignnant injury, or de novo. The utilization of tobacco and betel quid, overwhelming drinking of mixed refreshments and an eating regimen low in new foods grown from the ground are the significant hazard factors for oral SCC. The 5-year survival rate is poor at around half, primarily on the grounds that around 66% of people with oral SCC as of now have huge injuries at the time of diagnosis.

## REFERENCES:

1. Myers, J. N., Elkins, T., Roberts, D., and Byers, R. M. Squamous cell carcinoma of the tongue in young adults: increasing incidence and factors that predict treatment outcomes. *Otolaryngol. Head Neck Surg.*, 122: 44–51, 2000.
2. Koch, W. M., Lango, M., Sewell, D., Zahurak, M., and Sidransky, D. Head and neck cancer in nonsmokers: a distinct clinical and molecular entity. *Laryngoscope*, 109: 1544–1551, 1999.
3. Syrjanen K, Vayrynen M, Castren O, Mantyjärvi R, Pyyrönen S, Yliskoski M. Morphological and immunohistochemical evidence of human papilloma virus (HPV) involvement in the dysplastic lesions of the uterine cervix. *Int J Gynaecol Obstet* 1983;21:261–9.
4. Syrjanen K, Syrjanen S, Lamberg M, Pyyrönen S, Nuutinen J. Morphological and immunohistochemical evidence suggesting human papillomavirus (HPV) involvement in oral squamous cell carcinogenesis. *Int J Oral Surg* 1983;12:418–24.
5. Chaturvedi AK. Epidemiology and clinical aspects of HPV in head and neck cancers. *Head Neck Pathol* 2012;6 Suppl 1:S16–24.
6. D'Souza G, Dempsey A. The role of HPV in head and neck cancer and review of the HPV vaccine. *Prev Med* 2011;53 Suppl 1:S5–S11.
7. Kreimer AR, Clifford GM, Boyle P, Franceschi S. Human papillomavirus types in head and neck squamous cell carcinomas worldwide: a systematic review. *Cancer Epidemiol Biomarkers Prev* 2005;14(2):467–75.
8. Hobbs CG, Sterne JA, Bailey M, Heyderman RS, Birchall MA, Thomas SJ. Human papillomavirus and head and neck cancer: a systematic review and meta-analysis. *Clin Otolaryngol* 2006;31(4):259–66.
9. Bjørge, T., Hennig, E. M., Skare, G. B., Søreide, O., and Thoresen, S. Ø. Secondary primary cancers in patients with carcinoma in situ of the uterine cervix. The Norwegian experience 1970–1992. *Int. J. Cancer*, 62: 29–33, 1995.
10. Rabkin, C. S., Biggar, R. J., Melbye, M., and Curtis, R. E. Secondary primary cancers following anal and cervical carcinoma: evidence of shared etiologic factors. *Am. J. Epidemiol.*, 136: 54–58, 1992.
11. Loning, T., Ikenberg, H., Becker, J., Gissman, L., Hoepfer, I., and zur Hausen, H. Analysis of oral papillomas, leukoplakias, and invasive carcinomas for human papillomavirus type related DNA. *J. Investig. Dermatol.*, 84: 417–420, 1985.
12. van Houten, V. M. M., Snijders, P. J. F., van den Brekel, M. W. M., Kummer, J. A., Meijer, C. J. L. M., van Leeuwen, B., Denkers, F., Smeele, L. E., Snow, G. B., and Brakenhoff, R. H. Biological evidence that human papillomaviruses are etiologically involved in a subgroup of head and neck squamous cell carcinomas. *Int. J. Cancer*, 93: 232–235, 2001.
13. Zumbach, K., Hoffman, M., Kahn, T., Bosch, F., Gottschlich, S., Go'ro'gh, T., Rudert, H., and Pawlita, M. Antibodies against oncoproteins E6 and E7 of human papillomavirus types 16 and 18 in patients with head-and-neck squamous-cell carcinoma. *Int. J. Cancer*, 85: 815–818, 2000.
14. Andl, T., Kahn, T., Pfuhl, A., Nicola, T., Erber, R., Conradt, C., Klein, W., Helbig, M., Dietz, A., Weidauer, H., and Bosch, F. X. Etiologic involvement of oncogenic human papillomavirus in tonsillar squamous cell carcinomas lacking retinoblastoma cell cycle control. *Cancer Res.*, 58: 5–13, 1998.
15. Wilczynski, S. P., Lin, B. T.-Y., Xie, Y., and Paz, I. B. Detection of human papillomavirus DNA and oncoprotein overexpression are associated with distinct morphological patterns of tonsillar squamous cell carcinoma. *Am. J. Pathol.*, 152: 145–156, 1998.
16. Miller, C. S., and Johnstone, B. M. Human papillomavirus as a risk factor for oral squamous cell carcinoma: a meta-analysis, 1982–1997. *Oral Surg. Oral Med. Oral Pathol. Oral Radiol. Endod.*, 91: 622–635, 2001.

17. McKaig, R. G., Baric, R. S., and Olshan, A. F. Human papillomavirus and head and neck cancer: epidemiology and molecular biology. *Head Neck*, 20: 250–265, 1998
18. Harnish, D. G., Belland, L. M., Scheid, E. E., and Rohan, T. E. Evaluation of human papillomavirus-consensus primers for HPV detection by the polymerase chain reaction. *Mol. Cell. Probes*, 13: 9–21, 1999.
19. Herrington, C. S., Anderson, S. M., Bauer, H. M., Tronccone, B., de Angelis, M. L., Noell, H., Chimera, J. A., Van Eyck, S. L., and McGee, J. O'D. Comparative analysis of human papillomavirus detection by PCR and non-isotopic in situ hybridization. *J. Clin. Pathol. (Lond.)*, 48: 415–419, 1995.
20. J. K. Stephen, G. Divine, K. M. Chen, D. Chitale, S. Havard, and M. J. Worsham, "Significance of p16 in site-specific HPV positive and HPV negative head and neck squamous cell carcinoma," *Cancer and Clinical Oncology*, vol. 2, pp. 51–61, 2013.
21. Chaturvedi AK, Engels EA, Pfeiffer RM, et al. Human papillomavirus and rising oropharyngeal cancer incidence in the United States. *J Clin Oncol* 2011;29(32):4294–301.
22. Ryerson AB, Peters ES, Coughlin SS, et al. Burden of potentially human papillomavirus-associated cancers of the oropharynx and oral cavity in the US, 1998-2003. *Cancer* 2008;113(10 Suppl): 2901-9.
23. A. Y. Babiker, F. M. Eltom, M. S. Abdalaziz, A. Rahmani, S. Abusail, and H. G. Ahmed, "Screening for high risk humanpapilloma virus (HR-HPV) subtypes, among sudanese patients with oral lesions," *International Journal of Clinical and Experimental Medicine*, vol. 6, no. 4, pp. 275–281, 2013.
24. E. Benson, R. Li, D. Eisele, and C. Fakhry, "The clinical impact of HPV tumor status upon head and neck squamous cell carcinomas," *Oral Oncology*, vol. 50, no. 6, pp. 565–574, 2014.
25. Fakhry C, Westra WH, Li S, et al. Improved survival of patients with human papillomavirus-positive head and neck squamous cell carcinoma in a prospective clinical trial. *J Natl Cancer Inst* 2008;100(4):261-9.
26. G. Pannone, V. Rodolico, A. Santoro et al., "Evaluation of a combined triple method to detect causative HPV in oral and oropharyngeal squamous cell carcinomas: P16 immunohistochemistry, consensus PCR HPV-DNA, and in Situ Hybridization," *Infectious Agents and Cancer*, vol. 7, article 4, 2012.
27. A. K. Chaudhary, S. Pandya, R. Mehrotra, A. C. Bharti, M. Singh, and M. Singh, "Comparative study between the Hybrid Capture II test and PCR based assay for the detection of human papillomavirus DNA in oral submucous fibrosis and oral squamous cell carcinoma," *Virology Journal*, vol. 7, article 253, 2010.
28. J. E. Cameron, I. V. Snowwhite, A. K. Chaturvedi, and M. E. Hagensee, "Human papillomavirus-specific antibody status in oral fluids modestly reflects serum status in human immunodeficiency virus-positive individuals," *Clinical and Diagnostic Laboratory Immunology*, vol. 10, no. 3, pp. 431–438, 2003.
29. J. H. Lorch, M. R. Posner, L. J. Wirth and R. I. Haddad, "Seeking Alternative Biological Therapies: The Future of Targeted Molecular Treatment," *Oral Oncology*, Vol. 45, No. 4, 2009, pp. 447-453.
30. B. J. Braakhuis, E. Bloemena, C. R. Leemans and R. H. Brakenhoff, "Molecular Analysis of Surgical Margins in Head and Neck Cancer: More than a Marginal Issue," *Oral Oncology*, Vol. 46, No. 7, 2010, pp. 485- 491.
31. F. Levi, V. C. Te, L. Randimbison, M. Maspoli and C. La Vecchia, "Second Primary Oral and Pharyngeal Cancers in Subjects Diagnosed with Oral and Pharyngeal Cancer," *International Journal of Cancer*, Vol. 119, No. 11, 2006, pp. 2702-2704.
32. O. Gallo and S. Bianchi, "P53 Expression: A Potential Biomarker for Risk of Multiple Primary Malignancies in the Upper Aerodigestive Tract," *European Journal of Cancer Part B, Oral Oncology*, Vol. 31, No. 1, 1995, pp. 53-57.
33. D. Goldenberg, S. Harden, B. G. Masayeva, P. Ha, N. Benoit, W. H. Westra, W. M. Koch, D. Sidransky and J. A. Califano, "Intraoperative Molecular Margin Analysis in Head and Neck Cancer," *Archives of Otolaryngology—Head and Neck Surgery*, Vol. 130, No. 1, 2004, pp. 39-44.
34. B. J. Braakhuis, M. P. Tabor, C. R. Leemans, I. van der Waal, G. B. Snow and R. H. Brakenhoff, "Second Primary Tumors and Field Cancerization in Oral and Oropharyngeal Cancer: Molecular Techniques Provide New Insights and Definitions," *Head and Neck*, Vol. 24, No. 2, 2002, pp. 198-206

**Source of support:** Nil

**Conflict of interest:** None declared

This work is licensed under CC BY: *Creative Commons Attribution 3.0 License*.