(e) ISSN Online: 2321-9599

(p) ISSN Print: 2348-6805

ORIGINAL ARTICLE

Assessment of orbit length, width and index on dry skulls

Banita Bhagat

Assistant Professor, Department of Anatomy, Index Medical College Hospital & Research Centre, Indore, M.P., India

ABSTRACT:

Background: Anthropometric studies are an integral part of craniofacial surgery and syndromology. The present study compared the orbital height, width and index between males and females. **Materials & Methods:** 20 dry skulls of both genders were taken and parameters such as the measurements of orbital length (the maximum distance between the upper and lower margins of the orbital cavity), orbital width (Distance between the midpoint of the medial margin of the orbit to the midpoint on the lateral margin of the orbit) and orbital index (OI) (Orbital height/ Orbital breadth X 100) was recorded with the help of vernier caliper calibrated in millimeters. **Results:** The mean orbit length in males was 3.54 mm and in females was 3.14 mm. The difference was significant (P<0.05). The mean orbit width in males was 4.37 mm and in females was 4.12 mm. The difference was significant (P<0.01). The mean orbit index (OI) in males was 84.9 mm and in females was 84.1 mm. The difference was non- significant (P>0.05). **Conclusion:** Orbital length, with and index is effective in the field of forensic sciences. Careful analysis is required which helps in gender identification. There is variation in orbital length, width and index in both genders.

Key words: Gender, Morphometric, Orbit

Corresponding author: Banita Bhagat, Assistant Professor, Department of Anatomy, Index Medical College Hospital & Research Centre, Indore, M.P., India

This article may be cited as: Bhagat B. Assessment of orbit length, width and index on dry skulls. J Adv Med Dent Scie Res 2016;4(4):294-296.

INTRODUCTION

Understanding anatomical structure, proportion and mechanical function of the human body and racial variations in ocular anatomy is vital to clinical assessment and treatment of patients. Anthropometry aids the understanding of anatomical structures, constitutes the technique of expressing quantitatively the form of human body and skeleton.[1] It is a basic tool of biological anthropology and has been of immense help in the development of forensic sciences in general and forensic medicine in particular. Anthropometric studies are an integral part of craniofacial surgery and syndromology.[2]

The stereo-structure of the orbit is affected by several orbital diseases. Many factors have been implicated in the transformation of the facial skeleton into the adult form.[3] Although the basic structure is determined in accordance with genetically regulated blueprints while in utero, that is modified pre and postnatally through functional matrices responding to environmental and epigenetic influence such as climate, activity patterns and masticatory functions.[4] The orbit is the cavity or socket of the skull in which the eye and its appendages are situated. The orbital index (OI), the proportion of the orbit height to its breadth multiplied by 100 is determined by the shape of the face and varies with race, regions within the same race and periods in evolution.[5] The present study compared the orbital height, width and index between males and females.

MATERIALS & METHODS

The present study was conducted on 20 dry skulls of both genders. Ethical approval was obtained before starting the study.

Parameters such as the measurements of orbital length (the maximum distance between the upper and lower margins of the orbital cavity), orbital width (Distance between the midpoint of the medial margin of the orbit to the midpoint on the lateral margin of the orbit) and orbital index (OI) (Orbital height/ Orbital breadth X 100) was recorded with the help of vernier caliper calibrated in millimeters. Results were subjected to statistical analysis for correct inferences. P value less than 0.05 was considered significant.

RESULTS

Table I Assessment of orbital length

Gender	Mean (mm)	P value
Males	3.54	0.02
Females	3.14	

Table I shows that the mean orbit length in males was 3.54 mm and in females was 3.14 mm. The difference was significant (P<0.05).

Table II Assessment of orbital width

Gender	Mean (mm)	P value
Males	4.37	0.05
Females	4.12	

Table II shows that mean orbit width in males was 4.37 mm and in females was 4.12 mm. The difference was significant (P<0.01).

Table III Assessment of orbital index

Gender	Mean (mm)	P value
Males	84.9	0.17
Females	84.1	

Table III, graph I shows mean orbit index (OI) in males was 84.9 mm and in females was 84.1 mm. The difference was non- significant (P>0.05).

Graph I Assessment of orbital index

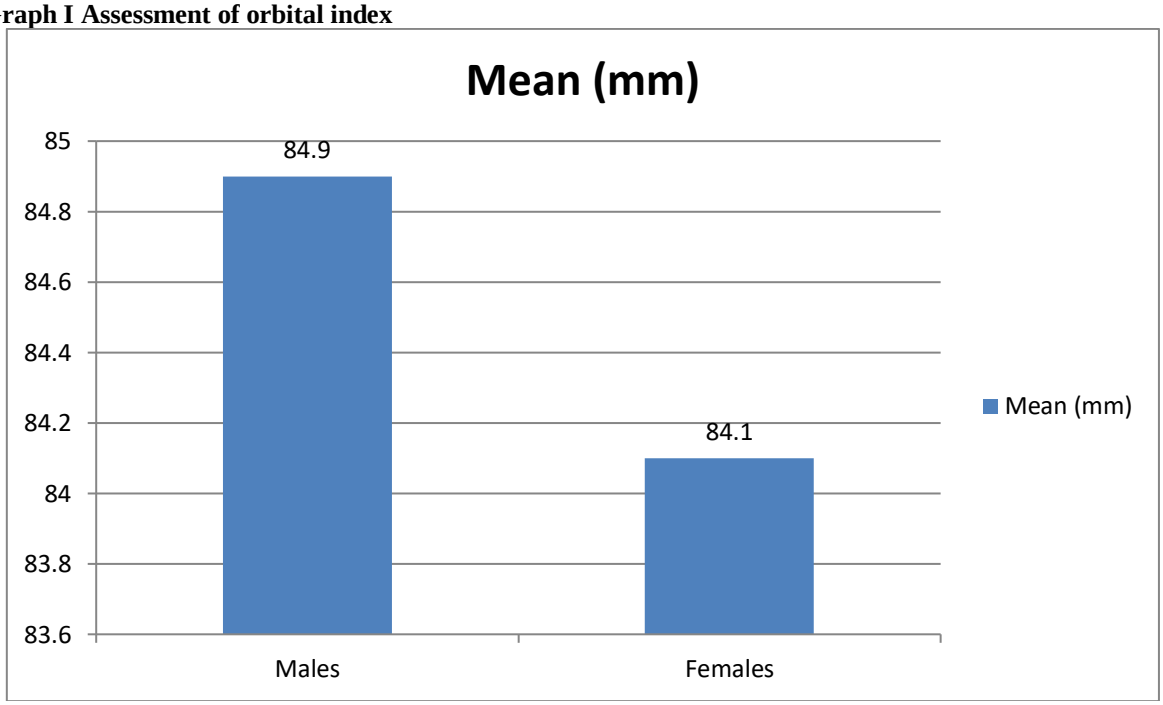

DISCUSSION

The human orbit is a complex anatomic region. Each of its four bony walls has its own unique features and is perforated by a number of fissures and foramina that carry important nerves and blood vessels.[6] The two orbital cavities are situated on either side of the saggittal plane of skull between the cranium and the skeleton of the face.[7] Thus situated, they encroach about equally on these two regions.[8] Orbital morphometric study will also provide parameters for preoperative planning and prediction of postoperative outcome.[9] In present study we compared orbital length, width and index in both males and females skull.

We found that the mean orbit length in males was 3.54 mm and in females was 3.14 mm. Kaur et al[10] in their study orbital dimensions of thirty (30) dry skulls of adult were measured by direct measurement technique with Vernier Caliper. The mean orbital height for the right and left sides were 31.9 ± 2.2 and 32.2 ± 1.8 mm while, their orbital breadth were 39.7 ± 2.2 and 38.8 ± 3.1 mm respectively. The mean orbital index was 81.65. The north population belongs to the Microseme category and this study will serve as a guide to surgical management of orbital pathologies as it relates to our environment.

We found that mean orbit width in males was 4.37 mm and in females was 4.12 mm. Among modern human groups there is considerable variability in the characteristics of the orbit. The volume of the orbit is 30 millilitres of which the eye occupies 6.5 ml. The orbital contents comprise the eye, the orbital and retrobulbar fascia, extraocular muscles, cranial nerves II, III, IV, V, and VI, blood vessels, fat, the lacrimal gland with its sac and nasolacrimal duct, the eyelids, medial and lateral palpebral ligaments, check ligaments, the suspensory ligament, septum, ciliary ganglion and short ciliary nerves.[11]

We observed that mean orbit index (OI) in males was 84.9 mm and in females was 84.1 mm. Cheng et al[12] evaluated the orbital aperture dimensions along with interorbital distance as observed on postero-anterior (PA) cephalograms for personal and gender identification. The present study found 84.8%

accuracy after subjecting the obtained value to discriminant function analysis. The morphometric analysis of the orbital aperture using postero-anterior cephalogram can be used as an adjuvant for personal and gender identification in forensic anthropology.

Mekala et al[13] measured the orbital dimensions on 200 human skulls using manual vernier caliper on South Indian population concluded that both the orbital height and breadth were significantly greater in males than females.

Rossi et al[14] evaluated the relationship of the orbital aperture dimensions with gender on 97 Brazilian human skulls using PA Caldwell radiographic view. The authors stated that the orbital measurements parameters such as width, area, and interorbital difference in both the genders were statistically significant.

Kumar et al[15] found that the mean distance between the anterior lacrimal crest (ALC) to the anterior ethmoidal foramen (AEF) is 24.52 ± 2.69 mm on the right side and 23.88 ± 2.76 mm on the left side in males and 23.84 ± 3.02 mm on the right side 23.00 ± 3.01 mm on the left side in females. The mean distance between ALC to PEF in males is 36.84±1.97 mm on the right side and 36.48±2.10 mm on the left side. In females it is 36.80±2.08 mm on the right side and 35.88±2.03 mm on the left side. These parameters are statistically significant in both sides. The mean distance between the anterior lacrimal crest to the optic canal is 42.40 ± 2.60 mm on the right side and 41.84 ± 2.10 mm on the left side in males, for females it is 42.08 ± 2.33 mm on the right side and 41.64 ± 2.18 mm on the left side in females.

The shortcoming of the study is small sample size.

CONCLUSION

Authors found that there is variation in orbital length, width and index in both genders. This measurement is useful in forensic studies. Careful analysis is required which helps in gender identification.

REFERENCES

1. Novit, M. Facial, upper facial and orbital index in Batak, Klaten and Flores students of Jember University. Dent. J. 2006; 39: 116-119.
2. Patniak, V.V.G., Bala Sanju and Singla Rajan, K. Anatomy of the bony orbits- some applied aspects. J. Anatomical Soc. Ind. 2001; 1: 59-67.
3. Everekliogiu, C., Doganay, S., Gunduz, A, Tercan, M., Balat, A. and Cumurcu, T. Craniofacial anthropometry in a Turkish population. Cleft Palate Craniofacial J. 2002; 39(2): 208-218.
4. Fawehinmi, H.B., Ligha, A.E. and Chikwu, P. Orbital dimensions of Nigerian adults. Jobiomed. Afr. 2008; 6: 1-2.
5. Xing, Song, Victoria Gibbon, Ronald Clarke, and Wu Liu. Geometric morphometric analyses of orbit shape in Asian, African, and European human populations. Anthropological Science 2013; 1:1-11.
6. Munguti Jeremiah, Mandela Pamela, Butt Fawzia. Sex differences in the cranial and orbital indices for a black Kenyan population. Int. J. Med. Sci 2013; 2:81-84.
7. Ukoha U., Egwu OA., Okafor IJ., et al. Orbital dimensions of adult male nigerians: A direct measurement study using dry skulls. Int J Biol Med Res.2011; 2: 688-690.
8. Sayee Rajangam, Kulkarni R.N, Lydia Quadrilos, et al. Orbital dimensions. Indian Journal of Anatomy 2012; 1:5-10.
9. Nitek S, Wysocki J, Reymond J, Piasecki K. Correlations between selected parameters of the human skull and orbit. Med Sci Monit. 2009;15:BR370–7.
10. Deepak S. Howale, Jain L. K, Kanaklata Iyer, et al. Orbital and Nasal indices of Maharastra region: A direct measurement study using dry skulls. International Journal of Current Research 2012; 4: 158-161.
11. Kaur J, Yadav S, Singh Z. Orbital dimensions-A direct measurement study using dry skulls. J Acad Indus Res. 2012;1(6):293-5.
12. Cheng AC, Lucas PW, Yuen HK, Lam DS, So KF. Surgical anatomy of the Chinese orbit. Ophthalmic Plast Reconstr Surg. 2008;24:136–41.
13. Mekala D, Shubha R, Rohini M. Orbiatal dimensions and orbital index: A measurement study on South Indian Dry Skull. Int J Anatomy Res. 2015;3:1387–91.
14. Rossi AC, de Souza Azevedo FH, Freire AR, Groppo FC, Júnior ED, Ferreira Caria PH, et al. Orbital aperture morphometry in Brazilian population by postero-anterior Caldwell radiographs. J Forensic Leg Med. 2012;19:470–3.
15. Kumar SS, Gnanagurudasan E. Morphometry of bony orbit related to gender in dry adult skulls of South Indian population. Int J Health Sci Res. 2015;5:20714.