

## Original Research

### Assessment of Complications of Laparoscopic Cholecystectomy

Manoj Kumar Sharma<sup>1</sup>, Rajesh Kumar Badal<sup>2</sup>

<sup>1,2</sup>Assistant Professor, Department of General Surgery, Govt. Medical College Datia, M.P. , India

#### ABSTRACT:

**Background:** During the past decade laparoscopic cholecystectomy (LC) has become the procedure of choice in the surgical treatment of symptomatic biliary lithiasis. The operation is not completely risk-free, some incidents and complications being more frequent than with open cholecystectomy (OC). The present study was conducted to assess complications of cholecystectomy of gall stones removal.

**Materials & Methods:** The present study was conducted on 328 patients of cholelithiasis of both genders. The standard 4- port laparoscopic cholecystectomy was performed in all patients. Complications arising from the surgery were recorded. **Results:** In this study, out of 328 patients, males were 152 and females were 176. Both biliary and nonbiliary complications take an important place in the published studies. The most common biliary complications described are lesions of the common bile duct, lesions of the right hepatic duct, and perforation of the gallbladder with spilt calculi. We found that common complications were loss of gall stones in 4, perforations of gall bladder in 8, respiratory problem in 2, Cardiac arrhythmia in 4, Hypothermia in 2, sudden death in 2, arterial bleeding in 8 and air embolism in 10. **Conclusion:** With the introduction of Laparoscopic cholestectomy, there is a surge of newer type of complications but the morbidity associated with this procedure is low. Common complications occurring are loss of gall stones, perforations of gall bladder, respiratory problem, Cardiac arrhythmia, Hypothermia, sudden death, arterial bleeding and air embolism.

**Key words:** Arrhythmia, Complications, laparoscopic cholecystectomy.

Received: 15 May, 2019

Revised: 02 June 2019

Accepted: 05 June 2019

**Corresponding author:** Dr. Rajesh Kumar Badal, Assistant Professor, Department of General Surgery, Govt. Medical College Datia, M.P. , India

**This article may be cited as:** Sharma MK, Badal RK. Assessment of complications of laparoscopic cholecystectomy. J Adv Med Dent Scie Res 2019;7(8): 243-246.

#### INTRODUCTION

Cholelithiasis is quite common in adults with a prevalence rate of 10-20% in the western world. Asian population appears to have a lower incidence of gallstones. The incidence of gallstone disease in Indian population is between 3-6% with a female preponderance.<sup>1</sup> Cholelithiasis is infrequent in children less than 16 years of age (<1%) and rather rare in the less than 12 years of age group. Though, it has long been considered comparatively less common in children, but in recent years the condition has been increasingly diagnosed mainly due to wide spread use of ultrasonography.<sup>2</sup>

Cholecystectomy is the most common elective surgery in India and world. Contrary to the traditional open method of abdominal exploration in present era of endoscopy ushered in many old and new laparoscopic approaches to the

peritoneal cavity. First decade of twentieth century saw several modification of the historical laparoscopic technique including single chip camera, rigid rod lens system and low definition screens etc. the second decade of this century has been introduced into a multitude of ramification of the multiport laparoscopic access and now we have single incision laparoscopic surgery (SILS), natural orifice transluminal endoscopic surgery (NOTES) and many other modification with their attendant benefit to the patient in particular and community in general.

Laparoscopic cholecystectomy has gained widespread popularity for treatment of symptomatic cholelithiasis. First laparoscopic cholecystectomy was performed by Dr Erich Miuhe in the year 1985 for removal of gall stones. It is after then that cholecystectomy has been widely used. It is not that this procedure is not associated with complications.<sup>3</sup>

Various major and minor complications are associated with it. Male gender, age, presence of systemic inflammatory response syndrome (defined by elevated inflammatory parameters- elevated white blood cell count and C- reactive protein), acute inflammation of the gallbladder and preoperative ultrasonographic finding of increased thickness of the gallbladder wall, and/or presence of gallbladder empyema, are all factors that increase risk for possible development of intraoperative laparoscopic complications, and the possibility of needing a conversion. These complications can be divided into biliary and non biliary. The incidence of complications associated with this procedure varies between 0.5 to 60%.<sup>4</sup> Even though there have been reports of increased complication rates but the morbidity and mortality associated with laparoscopic procedure is less than that of open procedure. Laproscopic cholecystectomy is the treatment of choice for cholelithiasis. The operation is not completely risk-free, some incidents and complications being more frequent than with open cholecystectomy (OC).<sup>5</sup> The present study was

conducted to assess complications of cholecystectomy of gall stones removal.

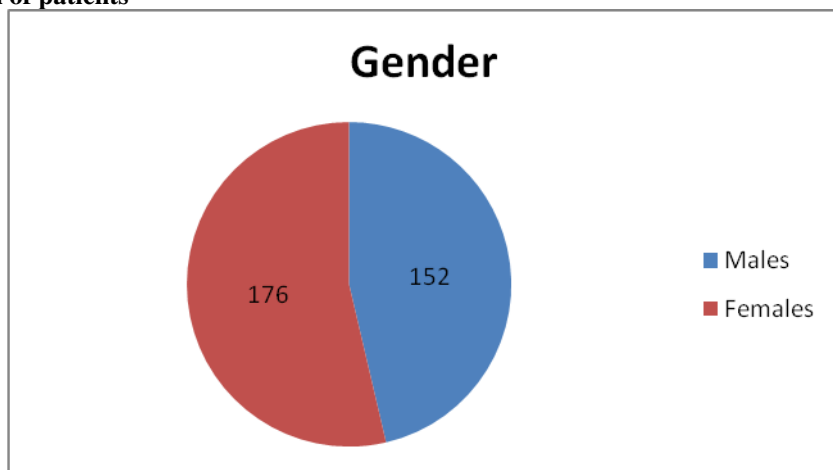
**MATERIALS & METHODS**

The present study was conducted in the Department of General Surgery, Govt. Medical College Datia, M.P. , India. We retrospectively analysed medical records of 328 patients who were diagnosed with cholelithiasis and had laparoscopic cholecystectomy. All were informed regarding the study and written consent was obtained. Ethical clearance was taken from institute ethical committee. General information such as name, age, gender etc. was recorded.

All patients subjected to CBC, urine examination, and abdominal Ultrasonography (USG). The standard 4- port laparoscopic cholecystectomy was performed in all patients. Complications arising from the surgery were recorded. Results thus obtained were subjected to statistical analysis. P value less than 0.05 was considered significant.

**RESULTS**

**Graph 1 Distribution of patients**



Graph I shows that out of 328 patients, males were 152 and females were 176.

**Table 1:** Showing operative diagnosis in our study

Diagnosis	Frequency	Percentage
Chronic calculous cholecystitis	202	61.58
Acute cholecystitis	55	16.76
Acalculous cholecystitis	30	9.14
Gall bladder mucocele	12	3.6
Gall stones in gall bladder remnant	4	1.22
Sclero-atrophic cholecystitis	25	7.7

Table 1 shows the data regarding the operative diagnosis. Majority of cases were of Chronic calculous cholecystitis(61.58%) followed by Acute cholecystitis 16.76%, Acalculous cholecystitis 9.14%, Sclero-atrophic cholecystitis 7.7%, Gall bladder mucocele 3.6%, Gall stones in gall bladder remnant 1.22%.

**Table 2: Complications of cholecystectomy**

Complications	Number	P value
Loss of gall stones	4	0.05
Perforations of gall bladder	8	
Respiratory problem	2	
Cardiac arrhythmia	4	
Hypothermia	2	
Sudden death	2	
Arterial bleeding	8	
Air embolism	10	

Table 2 shows that common complications were loss of gall stones in 4, perforations of gall bladder in 8, respiratory problem in 2, Cardiac arrhythmia in 4, Hypothermia in 2, sudden death in 2, arterial bleeding in 8 and air embolism in 10. The difference was significant ( $P < 0.05$ ).

## DISCUSSION

Gallstone disease has always been considered as a disease of the adults. It is relatively uncommon in childhood. A review of literature has suggested an increase in the frequency of cholelithiasis in children and resultant cholecystectomies.<sup>8</sup> An increased use of ultrasound for every case of pain in the abdomen also has helped in establishing a diagnosis of very small and single gallstones as well as biliary sludge. In young and otherwise healthy patients, early cholecystectomy is generally accepted as the standard treatment of acute cholecystitis.<sup>9</sup>

Laparoscopic cholecystectomy became the preferred method for the treatment of symptomatic cholelithiasis. Laparoscopic cholecystectomy has many advantages over the standard open cholecystectomy: minimal trauma, decreased pain, shorter hospital stay, satisfactory cosmetic outcome, quick recovery, and return to work. However, numerous studies have shown this that laparoscopic cholecystectomy is associated with a higher frequency of complications compared to the standard open cholecystectomy including lesions to the common bile duct, injury to the vascular and visceral structures during the application of a Veress needle, and a trocar with fatal outcomes. The present study was conducted to assess complications of cholecystectomy of gall stones removal.

In this study, out of 328 patients, males were 152 and females were 176. Both biliary and nonbiliary complications take an important place in the published studies. The most common biliary complications described are lesions of the common bile duct, lesions of the right hepatic duct, and perforation of the gallbladder with spilled calculi. We found that common complications were loss of gall stones in 4, perforations of gall bladder in 8, respiratory problem in 2, Cardiac arrhythmia in 4, Hypothermia in 2, sudden death in 2, arterial bleeding in 8 and air embolism in 10.

Radunovic et al<sup>10</sup> in their study found that there were 97 (13.1%) intraoperative complications (IOC). Iatrogenic perforations of a gallbladder were the most common

complication - 39 patients (5.27%). Among the postoperative complications (POC), the most common ones were bleeding from abdominal cavity 27 (3.64%), biliary duct leaks 14 (1.89%), and infection of the surgical wound 7 patients (0.94%). There were 29 conversions (3.91%). The presence of more than one complication was more common in males. The increased incidence of complications was noted in patients with ultrasonographic finding of gallbladder empyema and increased thickness of the gallbladder wall, as well as in patients with acute cholecystitis that was confirmed by pathohistological analysis. They concluded that adopting laparoscopic cholecystectomy as a new technique for treatment of cholelithiasis, introduced a new spectrum of complications. Major biliary and vascular complications are life threatening, while minor complications cause patient discomfort and prolongation of the hospital stay. It is important recognising IOC complications during the surgery so they are taken care of in a timely manner during the surgical intervention. Conversion should not be considered a complication.

Sarda et al<sup>11</sup> conducted a study in which various major and minor complications are associated with laparoscopic cholecystectomy were compared with open cholecystectomy. A total of records of 230 patients were analyzed. All the patients were aged between 30-65 years. There was a male predominance in our study. The mean age group was 40.21±1.13 years. Majority of cases were of chronic calculous cholecystitis (64.3%). There were 20% cases (n=46) of acute cholecystitis. There were 12 cases of leakage of bile, out of them 6 were managed conservatively, 4 underwent minimal invasive surgery and 2 underwent open surgery.

Deziel et al<sup>12</sup> found that all 120 patients included underwent laparoscopic cholecystectomy after going through a thorough clinical, radiological and laboratory investigations to confirm the disease process. 120 patients were divided into two groups with 60 in each group, group I with age 20-50 years and group II with age of 50-80 years.

This study shows that laparoscopic cholecystectomy can be performed in any age group. It can also be performed safely in the elderly patients, although the operative time is slightly longer in view of relatively higher incidence of adhesions in and around the Calots triangle. Operative difficulty, rate of conversion, hospital stay and postoperative short term outcome are not influenced by the age of the patient.

S Duca et al<sup>13</sup> observed that the main operative incidents encountered were haemorrhage (224 cases, 2.3%), iatrogenic perforation of the gallbladder (1517 cases, 15.9%) and common bile duct (CBD) injuries (17 cases, 0.1%). Conversion to open operation was necessary in 184 patients (1.9%), usually due to obscure anatomy as a result of acute inflammation. The main postoperative complications were bile leakage (54 cases), haemorrhage (15 cases), sub-hepatic abscess (10 cases) and retained bile duct stones (11 cases). Ten deaths were recorded (0.1%). They recommend these minimally invasive procedures in appropriate patients.

## CONCLUSION

Every procedure is associated with complications. With the introduction of Laparoscopic cholecystectomy, there is a surge of newer type of complications but the morbidity associated with this procedure is low. Authors found common complications such as loss of gall stones, perforations of gall bladder, respiratory problem, Cardiac arrhythmia, Hypothermia, sudden death, arterial bleeding and air embolism.

## REFERENCES

1. Abdul Aziz Laghari,, K AltafTalpur, Ahmed Khan Sangrasi et al; Emergency laparoscopic cholecystectomy in acute cholecystitis: PJS, Volume 23, Issue 1, 2007; 18-22.
2. Chok KS, Yuen WK, Lau H, Lee F, Fan ST. Outpatient laparoscopic cholecystectomy in Hong Kong Chinese –an outcome analysis. *Asian J Surg* 2004; 27:313-6.
3. Elder S, Sabo E, Nash E, Abrahamson J, Matter I. Laparoscopic versus open cholecystectomy in acutecholecystitis. *Surg Laparoscendosc* 1997 Oct; 7(5); 407-14.
4. Attwood SE, Hill AD, Mealy K, Stephens RB. A prospective comparison of laparoscopic cholecystectomy versus open cholecystectomy. *Ann R Coll surg Engl.* 1992;74(6):397-400.
5. Abu-Eshy SA, Mahfouz AA, Badr A, El Gamal MN, Al-Shehri MY, Salati MI, et al. Prevalence and risk factors of gallstone disease in a high altitude Saudi population. *East Mediterr Health J.* 2007;13(4):794–802.
6. Fuller J, Ashar BS, Carey-Corrado J. Trocar-associated injuries and fatalities: an analysis of 1399 reports to the FDA. *Journal of minimally invasive gynecology.* 2005 Aug 31;12(4):302-7.
7. Strasberg SM. An analysis of the problem of biliary injury during laparoscopic cholecystectomy. *Am Coll Surg.* 1995;180:101-25.

8. Woods MS, Shellito JL, Santoscoy GS, et al. Cystic duct leaks in laparoscopic cholecystectomy. *Am J Surg.* 1994; 168:560–5.
9. CH Chau, CN Tang, WtSiu et al; Laparoscopic cholecystectomy versus open cholecystectomy in elderly patients with acute cholecystitis: retrospective study. *Hong Kong Med J* 2002; 8:394-9.
10. Radunovic M, Lazovic R, Popovic N, Magdelinic M, Bulajic M, Radunovic L, Vukovic M, Radunovic M. Complications of Laparoscopic Cholecystectomy: Our Experience from a Retrospective Analysis. *Open Access Maced J Med Sci.* 2016 Dec 15; 4(4): 641–646.
11. Sarda DK, Garg PK. Retrospective Analysis of Complications Associated with Laparoscopic Cholecystectomy: A Hospital Based Study. *J Adv Med Dent Scie Res* 2018;6(4):40-42.
12. Deziel DJ, Millikan KW, Economou SG, Doolas A, Ko ST, Airan MC. Complications of laparoscopic cholecystectomy: a national survey of 4,292 hospitals and an analysis of 77,604 cases. *The American journal of surgery* 1993; 165(1):9-14.
13. S Duca, O Bălă, N Al-Hajjar, C Iancu, IC Puia, D Munteanu, and F Graur. Laparoscopic cholecystectomy: incidents and complications. A retrospective analysis of 9542 consecutive laparoscopic operations. *HPB (Oxford).* 2003; 5(3): 152–158.