

## Original Article

### Role of MRI in Evaluation of Cerebello pontine angle tumour

Shruti Kapoor<sup>1</sup>, V M Kulkarni<sup>2</sup>

<sup>1</sup>PG Student, <sup>2</sup>Prof & Head, Department of Radio Diagnosis, Dr D Y Patil Patil Medical College, Hospital and Research Centre, Pimpri Pune 411018

#### ABSTRACT:

**Background:** Lesions of the cerebellopontine angle (CPA) comprise 10% of all intracranial tumors. Since the introduction of Magnetic Resonance (MR), malformations of the brain have been found with greater frequency than previously suspected. Hence; we planned the present study to assess the role of Magnetic resonance imaging (MRI) in evaluating patients with cerebello pontine angle tumour.

**Materials & methods:** The present study included assessment of role of MRI in assessment of cerebello pontine angle (CPA) tumour. A total of 50 patients with CPA masses were included in the present study. Detailed clinical and radiographic examination of all the patients was done. The standard protocol comprised of T1WI, T2WI, DWI and FLAIR images in axial, sagittal and coronal planes. All the results were summarized in Microsoft excel sheet and were analyzed by SPSS software. **Results:** Common clinical symptoms included in the present study were tinnitus, vertigo, facial nerve palsy, hearing problem, headache and vomiting. Acoustic schwannoma and Meningioma were the most common CPA tumour encountered in the present study found to be present in 56 percent and 30 percent of the subjects.

**Conclusion:** For improving the sensitivity of CPA pathologies detection, MRI can be regarded as a significant reliable tool.

**Key words:** Cerebello pontine angle, Magnetic resonance imaging, Tumour.

Received: 20 March 2018

Revised: 19 May 2018

Accepted: 24 June 2018

**Corresponding author:** Dr. V M Kulkarni, Prof & Head, Department of Radio Diagnosis, Dr D Y Patil Patil Medical College, Hospital and Research Centre, Pimpri Pune 411018

**This article may be cited as:** Kapoor S, Kulkarni VM. Role of MRI in Evaluation of Cerebello pontine angle tumour. J Adv Med Dent Scie Res 2018;6(9):15-18.

#### INTRODUCTION

Lesions of the cerebellopontine angle (CPA) comprise 10% of all intracranial tumors. Most common extra-axial tumors of CPA are vestibular schwannomas, which constitutes the about 70-80% of all CPA lesions.<sup>1-3</sup> The CPA is a subarachnoid space located in the ventral surface of the brainstem and medial cerebellar hemisphere, laterally bordered by the superior and inferior limbs of the cerebellopontine fissure (CPF). The CPF is formed by the ventrolateral wings of the quadrangular lobule (superiorly) and simple lobule (inferiorly) folding around the middle cerebellar peduncle.<sup>4-6</sup>

Since the introduction of Magnetic Resonance (MR), malformations of the brain have been found with greater frequency than previously suspected. This is especially true for any lesions in the cerebellopontine angle, where the sensitivity and specificity of MR imaging with its

multidimensional imaging capabilities are far superior to that of CT.<sup>7-9</sup>

Hence; we planned the present study to assess the role of Magnetic resonance imaging (MRI) in evaluating patients with cerebello pontine angle tumour.

#### MATERIALS & METHODS

The present study was conducted in the department of radio-diagnosis of the medical institute and it included assessment of role of MRI in assessment of cerebello pontine angle (CPA) tumour. A total of 50 patients with CPA masses were included in the present study. All those patients were included in which CPA were detected on MRI. SIEMENS 1.5 Tesla MAGNETOM Avanto Machine was used for performing the MRI. 60 cm was the size of the bore of the machine, while 160 cm was the overall length of the system.

Inclusion criteria for the present study included:

- Patients within the age group of 25 to 60 years,
- Patients with negative history of any other systemic illness,
- Patients with negative history of any form of metabolic disorder
- Patients who presented with clinical symptoms of CPA lesions

Exclusion criteria for the present study included:

- Patients presenting with contraindication to MRI technique,
- Patients with positive history of previous Central nervous system surgical intervention

Detailed clinical and radiographic examination of all the patients was done. The standard protocol comprised of T1WI, T2WI, DWI and FLAIR images in axial, sagittal and coronal planes. Wherever required, Gadopentate

dimeglumine was used as contrast. All the results were summarized in Microsoft excel sheet and were analyzed by SPSS software. Chi-square test was used for assessment of level of significance.

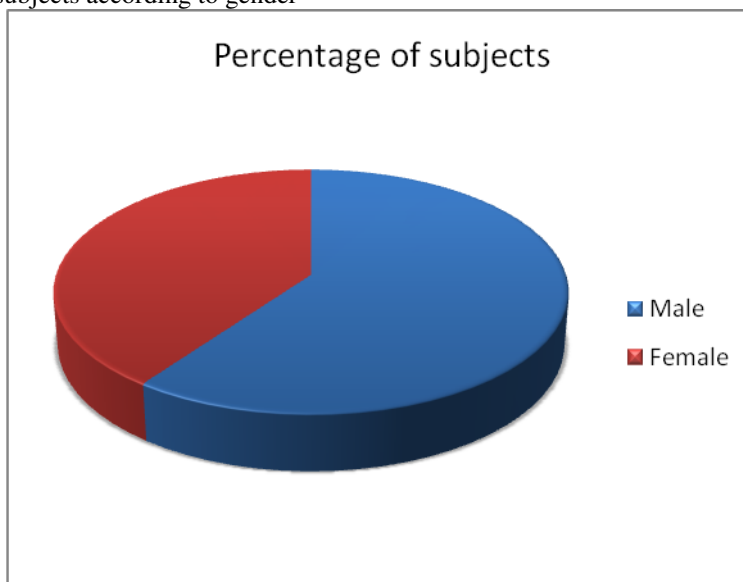
**RESULTS**

In the present study, a total of 50 patients were assessed. Among these patients, 44 percent belonged to the age group of 30 to 40 years. 30 percent of the patients were less than 30 years of age. 13 patients were more than 40 years of age. 60 percent of the patients of the present study were male. Common clinical symptoms included in the present study were tinnitus, vertigo, facial nerve palsy, hearing problem, headache and vomiting. Acoustic schwannoma and Meningioma were the most common CPA tumour encountered in the present study found to be present in 56 percent and 30 percent of the subjects.

**Table 1:** Age-wise distribution of subjects of the present study

Age group	Number of subjects	Percentage of subjects
Less than 30 years	15	30
30 to 40 years	22	44
More than 40 years	13	26
<b>Total</b>	<b>50</b>	<b>100</b>

**Graph 1:** Distribution of subjects according to gender



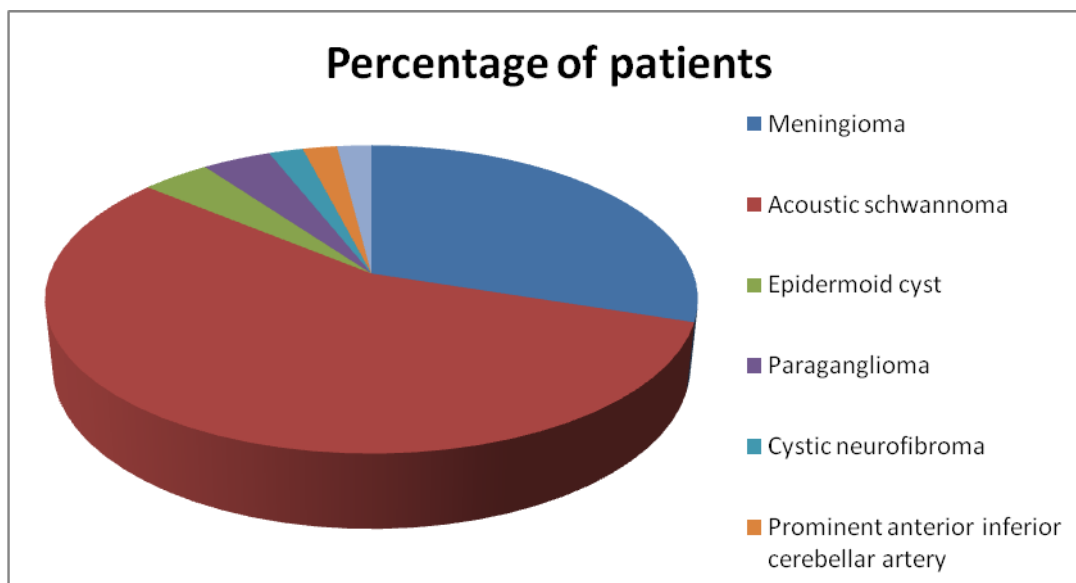
**Table 2:** Clinical presentation of cases included in the present study

Clinical symptoms	Number of cases	Percentage
Tinnitus	22	44
Vertigo	15	30
Facial nerve palsy	2	4
Hearing problem	38	76
Headache	28	56
Vomiting	2	4

**Table 3:** MRI diagnosis

MRI diagnosis	Number of subjects	Percentage of patients
<b>Meningioma</b>	15	30
<b>Acoustic schwannoma</b>	28	56
<b>Epidermoid cyst</b>	2	4
<b>Paraganglioma</b>	2	4
<b>Cystic neurofibroma</b>	1	2
<b>Prominent anterior inferior cerebellar artery</b>	1	2
<b>Arachnoid cyst</b>	1	2
<b>Total</b>	50	100

**Graph 2:** Graphical presentation of MRI diagnosis



**DISCUSSION**

In the present study, analysis of a total of 50 patients was done. Among these patients, 44 percent belonged to the age group of 30 to 40 years. 30 percent of the patients were less than 30 years of age. 13 patients were more than 40 years of age. Singh K et al evaluated the role of Magnetic Resonance Imaging (MRI) to localize and characterize the MR imaging features of cerebellopontine angle schwannomas and to compare with surgical/histopathological findings. It was a prospective study which included 19 patients, who presented with signs and symptoms s/o any lesion in the CP angle and were referred to the radiology department for MRI. All patients included in the study were subjected to detailed clinical history and physical examination following which MRI was carried out on Philips GyroscanAchieva 1.5 Tesla unit and the standard protocol consisted of T1WI, T2WI, DWI and FLAIR images in axial, sagittal and coronal planes. Hearing abnormality was the most common presenting complaint in patients with CP angle schwannoma’s followed by headache and tinnitus. Vestibulocochlear nerve was the most commonly involved nerve in patients with these lesions followed by involvement of trigeminal nerve. MRI was erroneous in

giving provisional diagnosis of schwannoma in one case, which on subsequent surgery and histopathology was found to be a meningioma. The sensitivity of MRI for correctly diagnosing vestibular schwannoma was 100 % and specificity was 92.86 % with a positive predictive value of 94.12 % and accuracy of 96.67 %. MRI is considered as an excellent noninvasive investigation for CP angle schwannoma’s. It can identify the site and extension of the lesions as well as the characteristic signal.<sup>10</sup> In the present study, 60 percent of the patients of the present study were male. Common clinical symptoms included in the present study were tinnitus, vertigo, facial nerve palsy, hearing problem, headache and vomiting. Acoustic schwannoma and Meningioma were the most common CPA tumour encountered in the present study found to be present in 56 percent and 30 percent of the subjects. Maaly MA et al explored an appropriate diagnosis to assess the extent and type of the lesion allowing for proper treatment. This study included 25 patients with symptoms suggestive of neurological disorders. Patients were subjected to different MRI sequences such as pre contrast, post contrast, diffusion MR, and MR spectroscopy. Of the 25 patients studied, the final diagnosis by MRI showed acoustic schwannoma in 12

(48.0%) patients, which was the most common lesion, followed by meningioma, was noted in seven (28.0%) patients, epidermoid cyst in one (4.0%) patient, prominent anterior inferior cerebellar artery (AICA) in one (4.0%) patient, paraganglioma in one (4.0%) patient, cystic neurofibroma in one (4.0%) patient, neurofibromatosis type 2 in one (4.0%) patient, and an arachnoid cyst in one (4.0%) patient. MRI is the gold-standard method to differentiate the lesions by anatomical site of origin, shape, signal intensity, and behavior after an injection of contrast media.<sup>11</sup> Haque S et al determined the diagnostic accuracy of MRI in the evaluation of intracranial extra axial CP angle Schwannoma. MRI scan of brain was done on 42 consecutively selected patients referred for the evaluation of CP Acoustic Schwannoma. The age range from 21-60 years and the mean age was 42.85 (+/- 9.5) years. Highest incidence of cerebello-pontine angle (CPA) mass were found 42.86% in 41-50 age group of patients. Male and Female ratio was 1.083:1. The most common presenting feature of the patients with CP angle Acoustic Schwannoma were headache 90.48%. Acoustic Schwannoma is T1 hypointense 100%, T2 hyper intense 84.61% and heterogeneously hyper intense 92.30% in FLAIR image. After giving contrast agents, homogeneous enhancement 57.69% and heterogeneous 42.31% cases of Acoustic Schwannoma. Overall 61.54% Acoustic Schwannoma strong contrast enhancement was observed. Dural tail was observed in 26.92% cases. Perilesional edema was observed 38.46% cases. Mass effect was observed in 76.92%. After complete MRI evaluation 61.9% had Acoustic Schwannoma. Histopathologically proved cases showed out of all patients Acoustic Schwannoma 59.52%. The overall sensitivity of MRI to diagnose Acoustic Schwannoma were found, Sensitivity- 96%, Specificity- 88.2%, PPV-92.31%, NPV-93.75% and Accuracy 92.86%. Test is significant with  $p < 0.0001$  level. It is conceivable that MRI is a highly accurate, sensitive and Gadolinium enhanced MRI is more sensitive in detection of acoustic Schwannoma. MR imaging is the study of choice for the examination of the patient of cerebellopontine angle Schwannoma because of its high sensitivity specially after use of contrast material.<sup>12</sup>

## CONCLUSION

Under the light of above obtained data, the authors concluded that for improving the sensitivity of CPA pathologies detection, MRI can be regarded as a significant reliable tool. For differentiating the CPA lesions in terms of site, location, shape and other morphological characteristics, MRI is a gold-standard method. However; further studies are recommended.

## REFERENCES

1. Moffat DA, Ballagh RH. Rare tumours of the cerebellopontine angle. *ClinOncol (R CollRadiol)* 1995;7:28-41.
2. Brunori A, Scarano P, Chiappetta F. Non-acoustic neuroma tumor (NANT) of the cerebello-pontine angle: a 15-year experience. *J Neurosurg Sci.* 1997;41:159-168.
3. Moffat DA, Ballagh RH. Rare tumours of the cerebellopontine angle. *ClinOncol.* 1995;7:28-41.
4. Breuer T, Gjuric M, Wigand M. Extended middle fossa surgery for meningiomas within or at the internal auditory canal. *Am J Otol* 2000; 21 :729-734.
5. Matson DD. *Neurosurgery of infancy and childhood.* Springfield: Charles C Thomas; 1969. p. 441.
6. Ahn MS, Jackler RK. Exophytic brain tumors mimicking primary lesions of the cerebellopontine angle. *Laryngoscope.* 1997;107:466-471.
7. Bonneville F, Sarrazin J, Marsot-Dupuch K. Unusual lesions of the cerebello-pontine angle: a segmental approach. *Radiographics.* 2001;21:419-438.
8. Springborg J, Poulsgaard L, Thomsen J. Nonvestibular schwannoma tumors in the cerebellopontine angle: a structured approach and management guidelines. *Skull Base* 2008; 18:217-227.
9. Lalwani A, Jackler R. Preoperative differentiation between meningioma of the cerebellopontine angle and acoustic neuroma using MRI. *Otolaryngol Head Neck Surg* 2003; 109 :88-95.
10. Singh K, Singh MP, Thukral C, Rao K, Singh K, Singh A. Role of Magnetic Resonance Imaging in Evaluation of Cerebellopontine Angle Schwannomas. *Indian Journal of Otolaryngology and Head & Neck Surgery.* 2015;67(1):21-27.
11. Maaly MA, Sultan AA. Current role of MRI in cerebellopontine angle lesions. *Menoufia Med J* 2016;29:147-51.
12. Haque S1, Hossain A, Quddus MA, Jahan MU. Role of MRI in the evaluation of acoustic schwannoma and its comparison to histopathological findings. *Bangladesh Med Res Counc Bull.* 2011 Dec;37(3):92-6.

**Source of support:** Nil

**Conflict of interest:** None declared

This work is licensed under CC BY: **Creative Commons Attribution 3.0 License.**