

Original Research

A comparative evaluation of different intraocular lens in patients requiring eye surgery

Virender Singh Chauhan

Professor, Department of Ophthalmology, TSM Medical College, Lucknow, Uttar Pradesh, India

ABSTRACT:

Background: Anterior chamber intra-ocular lens implantation is coming back into favor among some surgeons. The present study was conducted to compare different intraocular lens. **Materials & Methods:** 76 patients requiring eye surgery were randomly divided into 2 groups of 38 each. Group I patients underwent anterior chamber IOLs (ACIOLs) implantation and group II patients underwent scleral fixated IOLs (SFIOLs) implantation. The pre and post-operative visual acuity was measured. **Results:** Group I had 20 males and 18 females and group II had 19 males and 19 females. There was more improvement in BCVA score in patients with 6/12- 6/18 eye sight in both groups followed by patients with 6/60 and worse eye sight in both groups, whereas in patients with 6/6- 6/9 less improvement was observed in both groups ($P > 0.05$). **Conclusion:** Both intraocular lens were comparable in terms of treatment outcome in patients of eye surgery.

Key words: Anterior chamber intraocular lens, Eye surgery, Scleral fixated intraocular lens.

Received: September 12, 2020

Accepted: September 22, 2020

Corresponding Author: Dr. Virender Singh Chauhan, Professor, Department of Ophthalmology, TSM Medical College, Lucknow, Uttar Pradesh, India

This article may be cited as: Chauhan VS. A comparative evaluation of different intraocular lens in patients requiring eye surgery. J Adv Med Dent Sci Res 2020;8(10):249-251.

INTRODUCTION

Ideal correction of aphakia means the placement of the intraocular lens (IOLs) in the bag which relies on good capsular support. In these circumstances, IOL is well centered to the pupillary axis, maximizing the chances of optimal surgical and refractive outcomes.¹ In the absence of adequate posterior capsular support, like in complicated cataract surgery with disruption of the posterior capsule, it is often possible to place the IOL in the sulcus with excellent visual outcome.²

Anterior chamber intra-ocular lens implantation is coming back into favor among some surgeons, improved, open loop ACIOL designs and re-emergence of the iris fixated claw IOL.⁵ Sizing is less critical with the flexible haptics of the open-loop ACIOLs; as opposed to the more rigid or closed-loop ACIOL designs.³

There are five primary methods for dealing with IOL requirements in the absence of capsular support, mainly depending on the preoperative status of the eye: flexible

open loop ACIOLs and iris claw ACIOLs; iris-fixated retropupillary ACIOLs; iris-sutured PCIOLs and transscleral – sutured PCIOLs. If both the iris and the capsule are absent or disrupted, sutured transscleral PCIOLs are the only option.⁴

Each of these IOL has its own advantages and disadvantages. ACIOL is technically less demanding but has potential for increased damage to the corneal endothelium and the angle structures. Iris claw and iris fixated IOLs have increased chances of pigment release and intraocular inflammation. Sutured SFIOL implantation is technically more demanding and can have problems like pseudophacodonesis and suture related complications like suture knot exposure, suture breakage and IOL subluxation.⁵ The present study was conducted to compare different intraocular lens.

MATERIALS & METHODS

The present study was conducted in 76 patients requiring eye surgery of both genders in the department

of Ophthalmology. All patients were informed regarding the study and written consent was obtained. Data such as name, age, gender etc. was recorded. Patients were randomly divided into 2 groups of 38 each. Group I patients underwent anterior chamber IOLs (ACIOLs) implantation either primary or

secondary and group II patients underwent scleral fixated IOLs (SFIOLs) implantation either primary or secondary. In both groups, the pre and post-operative visual acuity was measured. Results thus obtained were subjected to statistical analysis. P value < 0.05 was considered significant.

RESULTS

Table I Distribution of patients

Groups	Group I	Group II
Method	Anterior chamber IOLs	Scleral fixated IOLs
M:F	20:18	19:19

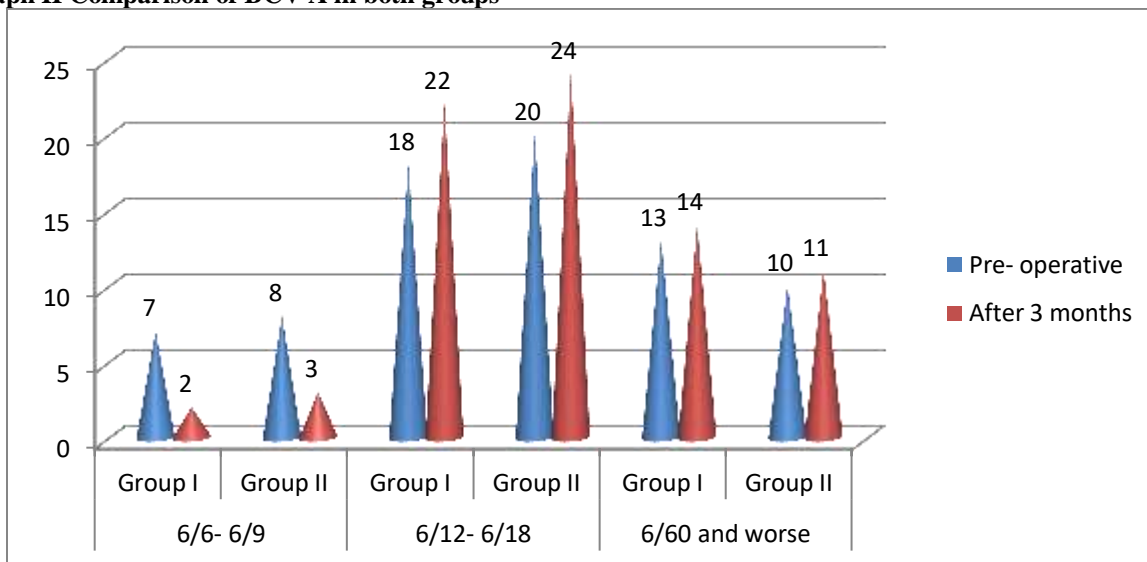
Table I, graph I shows that group I had 20 males and 18 females and group II had 19 males and 19 females.

Table II Comparison of BCV A in both groups

BCV A	Groups	Pre- operative	After 3 months	P value
6/6- 6/9	Group I	7	2	0.02
	Group II	8	3	
6/12- 6/18	Group I	18	22	0.05
	Group II	20	24	
6/60 and worse	Group I	13	14	0.09
	Group II	10	11	

Table II, graph II shows that there was more improvement in BCV A score in patients with 6/12- 6/18 eye sight in both groups followed by patients with 6/60 and worse eye sight in both groups, whereas in patients with 6/6- 6/9 less improvement was observed in both groups (P> 0.05).

Graph II Comparison of BCV A in both groups



DISCUSSION

Fixation of intraocular lenses in cases of insufficient or no capsular support is challenging and requires good surgical techniques to resolve different situations.⁶ In such a situation, the surgeon has four options, to leave the eye aphakic, to implant an anterior chamber

intraocular lens (AC IOL), to fixate a posterior chamber intraocular lens (PC IOL) in the iris or to fixate a PC IOL in the sclera. The potential issues of anisometropia, optical aberrations, and contact lens intolerance make aphakia a less-than-optimal solution in all but a few patients.⁷ anterior chamber (ACIOLs), iris-fixated

(IFIOLs), and scleral-fixated (SFIOLs). Choosing the best technique in the absence of capsular support can be challenging, although all these variants proved to have similar benefits and risks.⁸ A vitreoretinal surgeon is relatively frequently confronted with the situation to place an IOL in an eye without capsular support following the various conditions: trauma, complicated cataract surgery, and different ocular diseases. Trauma is of special interest, since it affects younger patients and is frequently followed by other changes in eye anatomy that add difficulty to the IOL implantation procedure.⁹

Several studies demonstrated improved results with these modern devices. Nevertheless, concern remains that ACIOLs are more damaging to the corneal endothelium than PCIOLs. The modern ACIOL designs had decreased the complications which were associated with the closed-loop ACIOLs but they have not been eliminated.¹⁰ The present study was conducted to compare different intraocular lens.

In present study, group I had 20 males and 18 females and group II had 19 males and 19 females. Kaur et al¹¹ in their study found that visual acuity improved from 0.94 ± 0.11 to 0.44 ± 0.13 in group A and group B eyes showed improvement from 0.95 ± 0.11 to 0.24 ± 0.09 . Preoperative mean IOP in SFIOL (17.2 ± 2.09 mmHg) increased by 13.95% to 19.6 ± 2.11 mm Hg after surgery. An increase of 21.08% was seen in preoperative IOP levels of 16.6 ± 2.98 mmHg to 20.1 ± 2.86 mmHg after ACIOL implantation. SFIOL implantation in group A lead to 5.42% fall in endothelial Count as compared to ACIOL implantation that caused a fall of 11.66% in group B eyes. A statistically significant improvement was seen in visual acuity after ACIOL implantation as compared to SFIOL implantation. The comparison of post operative IOP levels of SFIOL and ACIOL revealed statistical significance. However there was no statistical difference in the endothelial count between the groups.

We observed that there was more improvement in BCVA score in patients with 6/12- 6/18 eye sight in both groups followed by patients with 6/60 and worse eye sight in both groups, whereas in patients with 6/6- 6/9 less improvement was observed in both groups. Ahmad et al¹² found that of 62 eyes who completed 1 month follow up, 48 were men and 14 women. There was a significant improvement in uncorrected distance visual acuity after surgery ($p < 0.001$). One month postoperative best corrected distance visual acuity was 6/18 or better in 45 eyes (72.6%). The common early postoperative complications were hypotony, corneal

edema. No serious complications such as endophthalmitis and retinal detachment were seen.

CONCLUSION

Author found that both intraocular lens were comparable in terms of treatment outcome in patients of eye surgery.

REFERENCES

1. Apple DJ, Brems RN, Park RB. Anterior chamber lenses. Part I: complications and pathology and a review of designs. *J Cataract Refract Surg.* 1987; 13: 157-74.
2. Auffarth GU, Wesendahl TA, Brown SJ. Are there acceptable anterior chamber intra-ocular lenses for clinical use in the 1990s? An analysis of 4104 explanted anterior chamber intra-ocular lenses. *Ophthalmology.* 1994, 101: 1913–22.
3. Malbran ES, Malbran E Jr, Negri I. Lens guide suture for transport and fixation in secondary IOL implantation after intracapsular extraction. *Int Ophthalmol.* 1986; 9: 151-60.
4. Sujata S, Rajamohan M, Prabhakar. Comparison of Outcomes of Scleral Fixated Versus Anterior Chamber IOLs in Complicated Cataract Surgeries, AIOC 2008 Proceedings, Cataract Session II. 2008; 2: 91-3.
5. Poor YM, Lavin MJ. Techniques of intraocular lens suspension in the absence of capsular/zonular support. *Surv Ophthalmol.* 2005; 50: 429-62.
6. Oh H, Chu Y, Woong known O. Surgical technique for suture fixation of a single piece hydrophilic acrylic intraocular lens in the absence of capsular support. *J Cataract Refract Surg.* 2007; 33: 962-5.
7. Dick HB, Augustin AJ. Lens implant selection with absence of capsular support. *Curr Opin Ophthalmol.* 2001; 12: 47-57.
8. Wagoner MD, Cox TA, Ariyasu RG, et al. Intraocular lens implantation in the absence of capsular support: a report by the American Academy of Ophthalmology. *Ophthalmology.* 2003; 110: 840–59.
9. Kwong YY, Yuen HK, Lam RF, Lee VY, Rao SK, Lam DS. Comparison of outcomes of primary scleral- fixated versus primary anterior chamber intraocular lens implantation in complicated cataract surgeries. *Ophthalmology.* 2007 Jan 1;114(1):80-5.
10. Ellakwa AF, Hegazy KA, Farahat HG, et al. Anterior chamber intraocular lens versus scleral fixated intraocular lens in cases with insufficient capsular support. *MMJ July 2010; 23:5– 12.*
11. Kaur M, Mohindra V K. Comparison of visual outcome and complications between Scleral Fixated Intraocular Lens and Anterior Chamber Intraocular Lens in Aphakes. *J Adv Med Dent Scie Res* 2019;7(5): 59-62.
12. Ahmad M, Naem M, Iqbal S, Khan S. Visual outcome and complications of anterior chamber intraocular lens versus scleral fixated intraocular lens. *Pakistan Journal of Ophthalmology.* 2012;28(4).