

Original Article

Evaluation of Crestal Bone Loss adjoining the Implants prior to Prosthetic Loading of Dental Implant Systems

Paulami Bagchi

Associate Professor, Dept of Prosthodontics, D Y Patil Dental School Lohegaon Pune, India


ABSTRACT:

Objective: Crestal bone loss along implant surface jeopardizes its longevity and success of treatment. The bone must remain healthy after dental implant is placed for the dental implant to last. The study was done to assess crestal bone loss adjoining the implants before prosthetic loading of dental implant systems. **Materials and Methods:** About 10 two-stage implants of life care implant system and 10 two-stage implants of Noble biocare implant system were placed in patients in fourth quadrant. Digital orthopantomograph (OPG) was taken on day of implant placement. After 6 months, at time of second stage surgery, the implant stability was evaluated by the periosteal instrument. The crestal bone loss was evaluated on digital OPG. Same procedure for each system was carried out. **Results:** About 6 months after the implant placement, radiographic evaluation on digital OPG showed a mean crestal bone loss of 1.694 mm on the mesial side of implant and 1.892 mm on distal side of implant for Noble biocare system and radiographic evaluation on digital OPG showed a mean crestal bone loss of 0.863 mm on the mesial side of implant and 0.792 mm on distal side of implant for life care system.

Key Words: Collar design, crestal bone loss, implant, stability.

Corresponding author: Dr. Paulami Bagchi, Associate Professor, Dept of Prosthodontics, D Y Patil Dental School Lohegaon Pune, India

This article may be cited as: Bagchi P. Evaluation of Crestal Bone Loss adjoining the Implants prior to Prosthetic Loading of Dental Implant Systems. J Adv Med Dent Sci Res 2017;5(12):11-14.

Access this article online	
<p>Quick Response Code</p> 	Website: www.jamdsr.com
	DOI: 10.21276/jamdsr.2017.5.12.04

INTRODUCTION

The recovery time for dental implants is similar to physiological healing of bone tissue. The studies of titanium implants have shown that the process of healing can be divided in three phases: osteophilic, osteoconductive and osteoadaptive.^{1,2} The success of therapy is surgically, esthetically and functionally predictable only if there is an adequate amount of bone and gingival tissue.³ The amount of crestal bone loss during the first year may affect the sulcus depth and environment for the longevity of the implant.⁴

It has also been studied that rough/coated collar design implants show decreased bone loss.^{5,6} Marginal bone loss with both collar designs needs to be assessed. Endosseous implants during placement forms an intimate union with the surrounding bone, this process is known as osseointegration. The prognosis of dental implants depends on this connection between implant and hard, soft tissues of the oral cavity. The implant-tissue interface generally begins at the crestal region in successfully osseointegrated endosteal implants.⁷⁻⁹ In particular, after the first year of function

(prosthesis loading), crestal bone loss to or beyond the top of titanium screw implants. There is a lack of agreement as to why greater bone loss occurred during the initial year of implant function than later years. There are many possible etiologies to early implant bone loss. There are different parameters to assess the success rates of dental implants like lack of mobility, discomfort, infection, and continuous periapical radiolucency.^{10,11} There are various implant designs developed to achieve osseointegration and reduce bone loss crestal bone loss. 1 mm of marginal bone loss during the first year of implant placement and loading and afterward 0.1 mm yearly bone loss has been documented by previous studies. Various implant neck collar designs are being proposed to reduce bone loss. Some implant systems have a polished collar design to reduce plaque accumulation and to promote seal between biologic tissues. This polished collar design may have led to crestal bone loss. Studies show that there is crestal bone loss initially after loading of dental implant with prosthesis. But how much marginal bone loss will be there before loading of two-stage implants with prosthesis, needs further assessment.

METHODS

About 20 Partial dentate subjects with one or two missing teeth were selected (25-50 year age group). Missing teeth were mostly in the mandibular posterior quadrant that is in 36 or 46 region (Figure 1). All steps involved in treatment study were told to the patients. Ethical clearance from the institution was taken. Diagnostic Impressions (Alginate Impression Material, IMPRINT, DPI) was made. All necessary investigations were carried out, before implant placement. With the consent of the patients, the study was further carried. Subjects included in the study are with age between (25 and 50 years), who are medically fit, without any systemic diseases and can come for post-operative follow-up. Implants were placed in the mandibular posterior region with adequate bone support. The study duration was kept of 6 months. Subjects excluded in the study are with any oral pathological conditions. Subjects had undergone any corticosteroid therapy. Subjects\patients with any bone disorders. About 10 implants were placed with the help of life care dental implant system, EZ HI-Tech implant (life care), and other 10 implants were placed with the help of Noble biocare dental implant system, replace select implant (Noble biocare), by following proper manufacturer’s instructions. Both types of dental implants are root-form, TPS-coated, pure Titanium two-stage dental implants. Dental implants were placed equicrestal. Implant site was closed with the help of the flap. The patient was kept on medication for one week, post -operatively. Follow-up visits and post-operative instructions where kept and given. To assess marginal bone loss on mesial and distal sides This study was undertaken to assess marginal bone loss on the proximal sides of the dental implant, by OPG in both systems at the end of 6 months after implant placement, but before loading them prosthetically. Crestal bone loss was measured on Digital OPG. A horizontal line tangential to the most coronal border of the implant was used as reference. Measurements from this line to the crestal bone around the implant were performed along a line parallel to the long axis of implant to measure vertical bone measurement. The distance between the neck of dental

implant and at the level of marginal bone (first bone to implant neck contact) along the implant surface on both proximal side was assessed on the OPG machine monitor, using its software (Image Plus Software) (Figure 2). Values obtained were up to one unit after decimal. The radiographic assessment was done by Digital OPG, with standardized values. Marginal bone loss values were tabulated.

RESULTS

Distribution of mean and standard deviation (SD) values of crestal bone loss after 6 months for life care implants (System A) on mesial and distal sides (Table 1). Distribution of mean and SD values of crestal bone loss after 6 months for Noble biocare implants (System B) on mesial and distal sides (Table 2). Comparison of crestal bone loss after 6 months for life care implants (System A) and Noble biocare implants (System B) on mesial and distal sides (Table 3).

Figure 1: Intraoral photographs showing missing teeth in posterior region

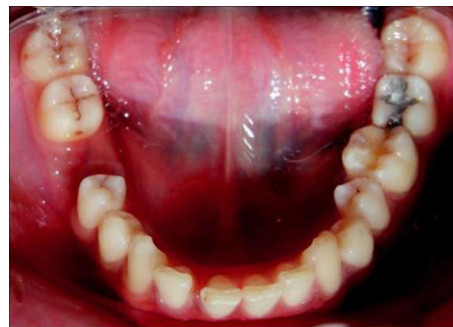

Figure 2: Image plus software to measure bone loss.

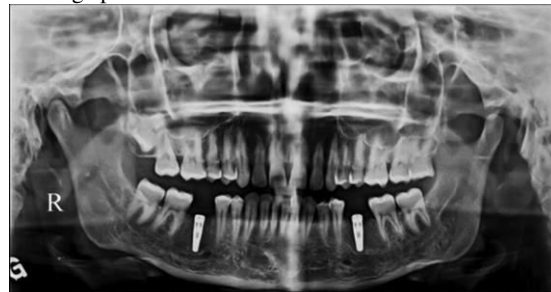

Table 1: Mean values of crestal bone loss after 6 months for life care implants (System A)

Crestal bone loss after 6 months for life care implants (System A) (n=10)		
	Mesial	Distal
Mean±SD	0.863±0.73	0.792±0.96
Range	0-2.43	0-3

Table 2: Mean values of crestal bone loss after 6 months for Noble biocare implants (System B)

Crestal bone loss after 6 months for Noble biocare implants (System B) (n=10)		
	Mesial	Distal
Mean±SD	1.694±1.63	1.892±0.93
Range	0.1-3.83	0.63-3.4

Table 3: Assessment of crestal bone loss after 6 months for life care implants (System A) and noble biocare implants (System B)

	Crestal bone loss after 6 months (n=10)			
	Mean±SD		t- value	p value
	Life care implants (System A)	Noble biocare implants (System B)		
Mesial	0.863±0.73	1.694±1.63	1.76	<0.05
Distal	0.792±0.96	1.892±0.93	3.25	<0.01

DISCUSSION

Conventional protocol proposed by Branemark states that the complete healing of the alveolar bone before placement of dental implant after tooth extraction; requires healing period of 6-12 months.^{12,13}

Panoramic radiographs and intraoral periapical X-rays are the most commonly used imaging source in implant dentistry.¹⁴ The panoramic radiographs were found to be as reliable as conventional periapical radiographs when used to assess the level of peri-implant bone level following implant treatment.¹⁵ In the present series of patients, the Digital panoramic and periapical radiographs were used to assess the peri-implant surface marginal bone changes. The digital OPG and radiographs were taken immediately after the procedure and 6th months postoperatively to measure the vertical and horizontal height of the crestal bone. The measurement was made by three observers and average mean value taken. The observer variability should be considered when comparing the values of radiographic assessment of level of marginal bone around the osseointegrated implants from the follow-up studies.¹⁶

In the present study, radiographic evaluation of mesial and distal vertical crestal bone demonstrated radiographic assessment of mean marginal bone loss of 0.863±0.73 mm on the mesial side and 0.792±0.96 mm on distal side of implant for implant System A (life care implant system) and mesial bone resorption of mean crestal bone loss of 1.694±1.63 mm on the mesial side and 1.892±0.93 mm on distal side of implant for implant System B (Noble biocare implant system) at the end of 6th month post-operative before functional loading of the implants and a cumulative success rate of implants was 100%. These results are compatible with previously reported data.¹⁵

The implant used in this study was two-piece, root-form, threaded implants. There is less of documentation on why there is marginal bone loss surrounding the dental implant collar, during the first year of implant surgery, placement. Different researchers have given different cause for it. The amount of bone loss is influenced by dental implant crest module design of the collar.^{17,18}

To reduce plaque accumulation, researchers have proposed the smooth polished machined collar of the implant.¹⁷ The cortical bone can withstand more compressive stresses than shear stresses. This lack of mechanical properties results in bone loss. The implants used are life care (Ez implants) had two mm collar design with micro threads and Noble biocare (replace select implant) had two mm smooth collar without micro threads. Implants were placed equicrestal that is at the level of crest of alveolar bone so that the junction of smooth

collar and rough threaded portion lies about 2 mm below the level of crestal bone. Thus, the initial crestal bone loss may be due to smooth collar design, even before Prosthetic loading. Hermann, Buser, Schenk and Cochra showed that rough-smooth implant border has effect on the peri-implant marginal bone reaction.¹⁹ These clinical trials show that the smooth polished collar length is directly proportional to the crestal bone loss.

CONCLUSION

The assessment of crestal bone loss around implants is necessary for evaluating implant success. It can be said that the present study achieved a 100% survival rate at 6 months. The design of collar of implant may have led to crestal bone loss. More stress should be given on implant neck collar design. The marginal bone loss may be influenced by the smooth polished collar design of the dental implant.

REFERENCES

1. Krhen J, Canjuga I, Jerolimov V, Krhen T. Implant stability measurement six weeks after implantation. *Acta Stomatol Croat* 2009;43(1):45–51.
2. Marx RE, Ehler WJ, Peleg M. “Mandibular and facial reconstruction” rehabilitation of the head and neck cancer patient. *Bone*. 1996;19(1):59–82.
3. Živko-Babić J, Jakovac M, Carek A, Lovrić Ž. Implantoprosthesis therapy of a missing front tooth. *Acta Stomatol Croat* 2009;43(3):234–41.
4. Misch CE. *Dental implant prosthetic; Library of Congress Cataloging in-Publication Data*. St Louis: Mosby; 2005.
5. Pilliar RM, Deporter DA, Watson PA, Valiquette N. Dental implant design – Effect on bone remodeling. *J Biomed Mater Res* 1991;25(4):467-83.
6. Hänggi MP, Hänggi DC, Schoolfield JD, Meyer J, Cochran DL, Hermann JS. Crestal bone changes around titanium implants. Part I: A retrospective radiographic evaluation in humans comparing two non-submerged implant designs with different machined collar lengths. *J Periodontol* 2005;76:791-802.
7. Adell R, Lekholm U, Rockler B, Brånemark PI. A 15-year study of osseointegrated implants in the treatment of the edentulous jaw. *Int J Oral Surg* 1981;10(6):387-416.
8. Buser D, Weber HP, Lang NP. Tissue integration of non-submerged implants 1-year results of a prospective study with 100 ITI hollow-cylinder and hollow-screw implants. *Clin Oral Implants Res* 1990;1(1):33-40.
9. Jemt T, Lekholm U, Gröndahl K. 3-year followup study of early single implant restorations ad modum Brånemark. *Int J Periodontics Restorative Dent* 1990;10(5):340-9.
10. Albrektsson T, Zarb G, Worthington P, Eriksson AR. The long-term efficacy of currently used dental implants: A review

- and proposed criteria of success. *Int J Oral Maxillofac Implants* 1986;1(1):11-25.
11. Smith DE, Zarb GA. Criteria for success of osseointegrated endosseous implants. *J Prosthet Dent* 1989;62(5):567-72.
 12. Paolantonio M, Dolci M, Scarano A, d'Archivio D, di Placido G, Tumini V, *et al.* Immediate implantation in fresh extraction sockets. A controlled clinical and histological study in man. *J Periodontol* 2001;72(11):1560-71.
 13. Wagenberg B, Froum SJ. A retrospective study of 1925 consecutively placed immediate implants from 1988 to 2004. *Int J Oral Maxillofac Implants* 2006;21(1):71-80.
 14. Jaffin R, Kolesar M, Kumar A, Ishikawa S, Fiorellini J. The radiographic bone loss pattern adjacent to immediately placed, immediately loaded implants. *Int J Oral Maxillofac Implants* 2007;22:187-94.
 15. West JD, Oates TW. Identification of stability changes for immediately placed dental implants. *Int J Oral Maxillofac Implants* 2007;22(4):623-30.
 16. Brugnolo E, Mazzocco C, Cordioli G, Majzoub Z. Clinical and radiographic findings following placement of single-tooth implants in young patients – Case reports. *Int J Periodontics Restorative Dent* 1996;16(5):421-33.
 17. Oh TJ, Yoon J, Misch CE, Wang HL. The causes of early implant bone loss: Myth or science? *J Periodontol* 2002;73(3):322-33.
 18. Joly JC, de Lima AF, da Silva RC. Clinical and radiographic evaluation of soft and hard tissue changes around implants: A pilot study. *J Periodontol* 2003;74(8):1097-103.
 19. Hermann JS, Buser D, Schenk RK, Cochran DL. Crestal bone changes around titanium implants. A histometric evaluation of unloaded non-submerged and submerged implants in the canine mandible. *J Periodontol* 2000;71(9):1412-24.

Source of support: Nil

Conflict of interest: None declared

This work is licensed under CC BY: *Creative Commons Attribution 3.0 License*.