

## Original Article

### Analysis of Cases of Anterior Hyperfunction Syndrome: A Clinical Study

Pranjali Dutt<sup>1</sup>, Vidhi Srivastava<sup>2</sup>, Pooran Chand<sup>3</sup>, Balendra Pratap Singh<sup>4</sup>, Sunit Kumar Jurel<sup>5</sup>

<sup>1</sup>Senior resident, PhD. Scholar, <sup>2</sup>Senior resident, <sup>3</sup>Professor & Head, <sup>4,5</sup>Associate Professor, Department of Prosthodontics, Faculty of Dental Sciences, KGMU, Lucknow, U.P., India

#### ABSTRACT:

**Background:** Anterior hyperfunction syndrome is when an edentulous maxilla is opposed by natural mandibular anterior teeth. This leads to various complications in patients requiring denture. The present study was conducted to analyze the cases of anterior hyperfunction syndrome in study population. **Materials & Methods:** This study was conducted on 80 patients having edentulous maxilla wearing maxillary denture and partially edentulous mandible wearing mandibular removable partial denture. They were analyzed for various signs and symptoms seen in patients with anterior hyperfunction syndrome. **Results:** Maximum cases were recorded for lack of maxillary denture adaptation (male- 12, female- 8). The need for replacement for maxillary denture was seen in 5 males and 4 females. Growth of the tuberosities was seen in 4 males and 5 females. Lack of mandibular denture adaptation was seen in 7 males and 3 females. Need for replacement for mandibular denture was seen in 6 males and 2 females. Papillary hyperplasia was seen in 1 male and 1 female. Hypermobility of the anterior part of the maxilla was seen in females (7) and males (3). Extrusion of lower anterior teeth was seen in 3 males and 2 females. The difference was significant (0.01). **Conclusion:** The prevalence rate of combination syndrome was 30% with slight male predominance. Most common sign was lack of maxillary denture adaptation and the need for replacement for maxillary denture.

**Key words:** Anterior hyperfunction syndrome, Mandible, Maxilla.

Received: 18 April 2018

Accepted: 29 May 2018

**Corresponding author:** Dr. Vidhi Srivastava, Senior resident, Department of Prosthodontics, Faculty of Dental Sciences, KGMU, Lucknow, U.P., India

**This article may be cited as:** Dutt P, Srivastava V, Chand P, Singh BP, Jurel SK. Analysis of Cases of Anterior Hyperfunction Syndrome: A Clinical Study. J Adv Med Dent Sci Res 2018;6(6):12-14.

#### INTRODUCTION

Anterior hyperfunction syndrome occur when an edentulous maxilla is opposed by natural mandibular anterior teeth, including loss of bone from the anterior portion of the maxillary ridge, overgrowth of the tuberosities, papillary hyperplasia of the hard palatal mucosa, extrusion of mandibular anterior teeth, and loss of alveolar bone and ridge height beneath the posterior mandibular removable dental prosthesis bases. It is also known as combination syndrome.<sup>1</sup>

If the bilateral distal extension mandible and completely edentulous maxilla are rehabilitated with removable partial dentures, there are chances that mandibular denture base sink gradually because of resorption of alveolar bone in the posterior aspect of mandible leading to posterior open bite. The lack of posterior occlusal contacts causes an eventual and progressive shift of masticatory function to anterior

segments. The absence of teeth can be managed by partial or complete denture if patient has few missing teeth or complete loss of teeth respectively. The prognosis depends upon various factors. The situation becomes difficult when maxillary complete denture opposes mandibular removable partial denture.<sup>2</sup>

Saunders et al<sup>3</sup> added six more characteristics (1) loss of vertical dimension of occlusion, (2) occlusal plane discrepancy, (3) anterior spatial repositioning of the mandible, (4) poor adaptation of the prostheses, (5) epulis fissuratum and (6) periodontal changes.

Completely edentulous maxilla and partially edentulous mandible with only anterior teeth remaining include loss of occlusal vertical dimension, occlusal plane discrepancy, anterior spatial repositioning of the mandible, and poor adaptation of the prosthesis, epulis fissuratum and periodontal changes are few conditions. The present study

was conducted to analyze the cases of anterior hyperfunction syndrome.

**MATERIALS & METHODS**

This study was conducted in department of Prosthodontics. It included 80 patients of both genders. All patients were of Kennedy class I ie having edentulous maxilla wearing maxillary denture and partially edentulous mandible wearing mandibular removable partial denture. All were informed regarding the study and written consent was obtained. Ethical clearance was taken from institutional ethical committee.

General information such as name, age, gender etc. was recorded. The hypermobility of the anterior part of the maxilla (HAM), extrusion of the mandibular anterior teeth (EMAT), epulis fissuratum (EF), presence of loose hypermobile tissue overlying the alveolar ridge, lack of adaptation of prostheses (LA maxilla/ mandible), growth of the tuberosities (GT), papillary hyperplasia (PH), necessity for replacements of prostheses (NR maxilla/ mandible) were recorded. Results thus obtained were subjected to statistical analysis. P value less than 0.05 was considered significant.

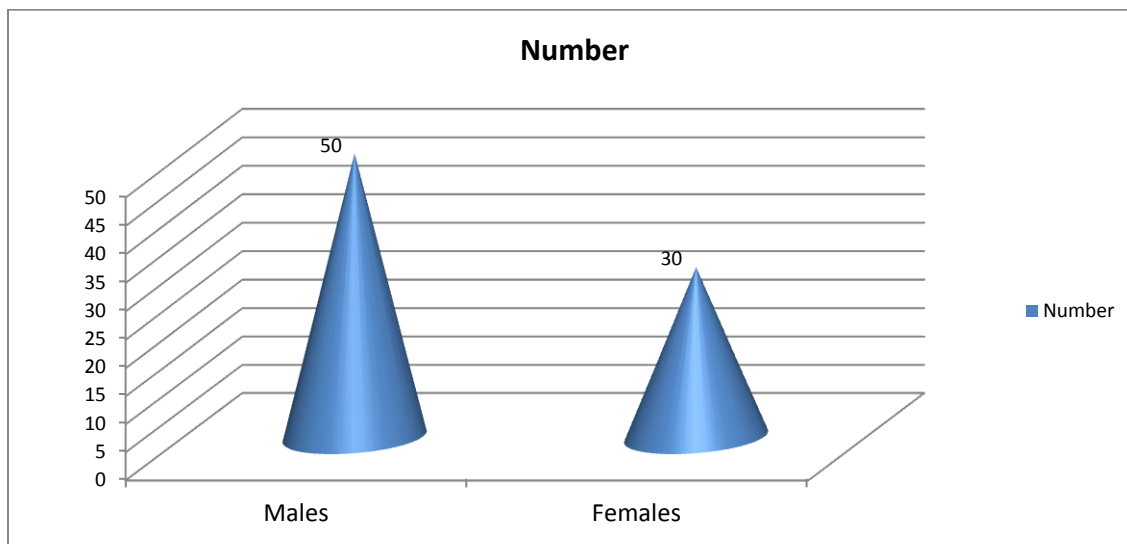
**RESULTS**

**Table I Number of anterior hyperfunction syndrome patients**

<b>Total examined</b>	<b>Anterior hyperfunction syndrome</b>	<b>%</b>
240	80	30%

Out of 240 patients examined, 80 (30%) patients were found positive for anterior hyperfunction syndrome.

**Graph I Distribution of patients**



Graph I shows that out of 80 patients, males were 50 and females were 30. The difference was non-significant (P= 0.1).

**Table II Occurrence of signs in patients**

Signs	Males	Females	P value
Extrusion of lower anterior teeth	3	2	0.01
Epulis Fissuratum	5	2	
Growth of Tuberoisity	4	5	
Hypermobility of Anterior Maxilla	7	3	
Papillary Hyperplasia	1	1	
NR maxillary denture	5	4	
NR mandibular denture	6	2	
lack of maxillary denture adaptation	12	8	
lack of mandibular denture adaptation	7	3	
<b>Total</b>	<b>50</b>	<b>30</b>	

Table II shows that maximum cases were recorded for lack of maxillary denture adaptation (male- 12, female- 8). The need for replacement for maxillary denture was seen 5 males and 4 females. Growth of the tuberoisities was seen in 4 males and 5 females. Lack of mandibular denture adaptation was seen in 7 males and 3 females. Need for replacement for mandibular denture was seen in 6 males and 2 females. Papillary hyperplasia was seen in 1 male and 1 female. Hypermobility of the anterior part of the maxilla was seen in females (7) and males (3). Extrusion of lower anterior teeth was seen in 3 males and 2 females. The difference was significant (0.01).

## DISCUSSION

Early loss of bone from the posterior part of the mandible leads to increase in function in the anterior region as a result of posterior hypofunction. Hypertrophy of the anterior mandible with anterior hyperfunction develops. Forces originating from the lower anterior teeth are directed toward the anterior portion of the unsupported maxillary denture leading to loss of bone and ridge height anteriorly, the posterior residual ridge becomes larger with the development of enlarged tuberosity. The changes in tissue form and health seen in this syndrome can be attributed to several factors, one of which is the biomechanical factor. When mandibular anterior teeth are present, patients tend to favor these teeth functionally because of the ability to generate maximum force. Excessive anterior function and parafunctional in excursive movements constantly overload the anterior ridge to result in alveolar bone resorption and possible development of epulis fissuratum.<sup>4</sup>

We found that out of 240 examined patients, 80 had this syndrome. Another paramount aspect of this syndrome is a repercussion of ridge resorption is impairment in established posterior occlusal contact leading to the progressive collapse of vertical dimension of occlusion causing the mandible to move forward resulting in pseudomandibular prognathism.<sup>5</sup>

A study by Ashok et al<sup>6</sup> found 89 patients completely edentulous maxilla. Thirty-two patients had a Kennedy Class I removable partial denture and 57 had Kennedy Class II. Three major alterations were observed in 28.5% of the studied population. Nevertheless, these changes were present only in 27% of patients with Kennedy Class I removable partial denture. Resham et al<sup>7</sup> in his study have found 32% prevalence rate. However in our study, it was 30%. Males were more as compared to females. The bone resorption beneath the mandibular distal extension, wearing of artificial teeth, positional changes in anterior teeth instigate parafunctional activities, thereby augmenting the force per unit area on the maxillary alveolar bone.

Lack of maxillary denture adaptation, need for replacement for maxillary denture and lack of mandibular denture adaptation showed higher prevalence rate as compared to other indices. This is in agreement with Ahen et al.<sup>8</sup> The growth of the tuberosities was often seen unilaterally, accentuating the lack of occlusal stability provided by acrylic teeth. One can theorize that disocclusion on the working side with natural teeth would generate a lever force on the non-working side with acrylic teeth, dislodging the complete prosthesis, giving space for down growth of the tuberosities and leading to the resorption of mandibular residual ridges. There is need to check for denture flanges to avoid these complications.<sup>9</sup>

Maximum support of the denture-bearing area, preservation of the mandibular posterior abutment, and balanced occlusion were all proposed to prevent bone loss and excess pressure on the anterior maxillary alveolar ridge. Similarly, Van et al<sup>10</sup> suggested the avoidance of total tooth extraction, the preservation of a few teeth, and the use of overdentures. Both implants retained and implant supported prostheses have become increasing popular and have been proven successful in prosthetic rehabilitation of partially and completely edentulous maxilla and mandible.<sup>11</sup> The unstable occlusion in combination syndrome results in progressive posterior mandibular atrophy.

## CONCLUSION

The prevalence rate of anterior hyperfunction syndrome was 30%. Males showed higher prevalence than females. Most common sign was lack of maxillary denture adaptation and the need for replacement for maxillary denture.

## REFERENCES

1. Kelly E. Changes caused by a mandibular removable partial denture opposing a maxillary complete denture. *J Prosthet Dent* 1972;27:140-50.
2. Langer. The use of linear occlusion to treat a patient with combination syndrome: A clinical report. *J Prosthet Dent* 2001; 85:15-9.
3. Saunders TR, Gillis RE, Desjardins RP. The maxillary complete denture opposing the mandibular bilateral distal-extension partial denture: treatment considerations. *J Prosthet Dent* 1979; 41:124-8.
4. Lechner SK, Mammen A. Combination syndrome in relation to osseointegrated implant-supported overdentures: a survey. *Int J Prosthodont.* 1996; 9: 58-64.
5. Maxson BB, Powers MP, Scott RF. Prosthodontic considerations for the transmandibular implant *J Prosthet Dent* 1998; 63: 554-8.
6. Ashok. The continuing reduction of the residual alveolar ridges in complete denture wearers: a mixed-longitudinal study covering 25 years. *J Prosthet Dent* 1972; 27: 120-32.
7. Resham, Rooney GE Jr. Alveolar bone loss in overdentures: a 5-year study. *J Prosthet Dent.* 1978; 40: 610-3.
8. Ahen K, Gonglo RK. Prevalence of the 'combination syndrome' among denture patients. *J Prosthet Dent* 1989; 62: 642-4.
9. Palmqvist S, Carlsson GE, Owall B. \_e combination syndrome: a literature review. *J Prosthet Dent* 2003; 90: 270-5.
10. Van MA, Jonkman RE, Kalk W, Vant Hof MA, Plooij J, Van Os JH. Differences two years after tooth extraction in mandibular bone reduction in patients treated with immediate overdentures or with immediate complete dentures. *J Dent Res.* 1993; 72: 1001-4.
11. Burns DR, Unger JW, Elsewick RK Jr, Giglio JA. Prospective clinical evaluation of mandibular implant overdentures. Part II: patient satisfaction and preference. *J Prosthet Dent* 1995; 73:364-9.

Source of support: Nil

Conflict of interest: None declared

This work is licensed under CC BY: *Creative Commons Attribution 3.0 License.*