

Original Article

Assessment of Pattern of Lip Prints in Patients with Oral Pre-malignant lesions

Iqbal Kaur¹, Jasdeep Kaur Cheema²

^{1,2}Private Practitioner, B.D.S. Amritsar, Punjab, India

ABSTRACT:

Background: Several researches have proven that genetic and environmental factors are important determinants in causation of oral potentially malignant diseases (PMDs) and oral cancer. In this context, cheiloscopy can also be useful tool to other diagnostic methods in identifying various diseases of genetic origin. **Aim of the study:** To study the pattern of lip prints in patients with oral pre-malignant lesions. **Materials and methods:** The present study was conducted in the Department of Oral Medicine of the dental institute. A written informed consent was obtained from the participants after explaining them the procedure of the study. For the study, we selected 50 subjects from the outpatient department. The subjects having full dentition were included. Patients were grouped into 2 groups, Group 1: Patients without oral premalignant lesions (n=25) and Group 2: Patients with oral premalignant lesions (n=25). **Results:** We observed that most frequent type of lip print in Group 1 was Type III lip prints. Similarly, the most frequent type of lip print in Group 2 was Type II lip prints. The results were comparable and were statistically non-significant. We observed that oral leukoplakia was seen in 4 subjects, OLP was seen in 5 subjects, oral erythroplakia was seen in 7 subjects and OSMF was seen in 9 patients. The results were comparable and observed to be statistically non-significant. **Conclusion:** From the results of the present study, we conclude that the association of lip prints with oral pre-malignant lesions is non-significant. Further studies are required to support the hypothesis.

Key words: Lip prints, pre-cancerous lesions, pre-malignant lesions.

Received: 2 May 2018

Revised: 16 May 2018

Accepted: 17 May 2018

Corresponding author: Jasdeep Kaur Cheema, Private Practitioner, B.D.S. Amritsar, Punjab, India

This article may be cited as: Kaur I, Cheema JK. Assessment of Pattern of Lip Prints in Patients with Oral Pre-malignant lesions. J Adv Med Dent Scie Res 2018;6(7):8-11.

INTRODUCTION:

Cheiloscopy (from the Greek words cheilos meaning 'lips' and e skopein meaning 'to see') is the name given to the lip print studies. The importance of cheiloscopy is linked to the fact that the lip prints are unique to one person, except in monozygotic twins. Like fingerprints and palatal rugae, the lip grooves are permanent and unchangeable.^{1, 2} It is possible to identify the lip patterns as early as the 6th week in uterine life. From that moment on, the lip groove patterns rarely change, resisting many afflictions, such as herpetic lesions.³ In current scenario, dermatoglyphics is widely used in the dentistry to detect the genetic basis of various conditions like cleft lip and palate, early childhood caries, developing malocclusion in pediatric population, periodontal diseases, bruxism, and also potentially malignant and malignant conditions.^{4, 5} Several researches have proven that genetic and environmental factors are important determinants in causation of oral potentially

malignant diseases (PMDs) and oral cancer. In this context, cheiloscopy can also be useful tool to other diagnostic methods in identifying various diseases of genetic origin. Hence, the present study was planned to study the association of lip prints with oral pre-malignant lesions.⁶ Hence, the present study was conducted to study the pattern of lip prints in patients with pre-malignant lesions.

MATERIALS AND METHODS:

The present study was conducted in the Department of Oral Medicine of the dental institute. The ethical clearance for the study was obtained from the research ethical committee of the institute. A written informed consent was obtained from the participants after explaining them the procedure of the study. For the study, we selected 50 subjects from the outpatient department. The subjects having full dentition were included. However, the eruption of the last molar is ignored in classifying full dentition, as its eruption is

variable. Lips free from any pathology, having absolutely normal transition zone between the mucosa and the skin were included in the study. Subjects with malformation, deformity inflammation trauma and surgical scars (e.g. operation for cleft palate) and other abnormalities of the lips were excluded because of their unsuitability for this investigation. Patients were grouped into 2 groups,

- Group 1: Patients without oral premalignant lesions (n=25)
- Group 2: Patients with oral premalignant lesions (n=25)

A detailed case history was obtained with conducting a thorough clinical examination. Findings were recorded. The cases of potentially malignant disorders were diagnosed on the basis of their clinical features and their association with supporting etiological factors. In order to classify the lip prints in this study, the classification scheme proposed by Suzuki and Tsuchihashi was used: Type I—clear-cut groove running vertically across the lip, Type II—partial length groove, Type III—branched groove, Type IV—intersected groove, Type V—reticular pattern, Type VI—other patterns. Red and brown colored lipstick, cellophane tape, white chart paper and magnifying lens were used to analyze the lip prints, where red lipstick was used for females and brown for males. Lips of the subjects were cleaned and they were asked to open the mouth when lipstick was applied in a single motion. They were asked to gently rub the lips together to spread the lipstick evenly and to make a lip

impression in the normal rest position of the lips by dabbing it in the center first and then pressing it uniformly toward the corners of the lips. The cellophane strip was then stuck to the white chart paper for permanent record purpose and then the recorded lip prints were visualized by magnifying lens. Data were collected to analyze for various dermatoglyphic patterns. Comparison of dermatoglyphic data was done between the groups.

The statistical analysis of the data was done using SPSS version 11.0 for windows. Chi-square and Student's t-test were used for checking the significance of the data. A p-value of 0.05 and lesser was defined to be statistical significant.

RESULTS:

The present study was planned to analyze lip prints pattern in patients with oral pre-malignant lesions. Table 1 shows the types of Lip prints in both groups. We observed that most frequent type of lip print in Group 1 was Type III lip prints. Similarly, the most frequent type of lip print in Group 2 was Type II lip prints. The results were comparable and were statistically non-significant. [Fig 1] Table 2 shows the oral pre-malignant lesions and types of lip prints in study population. We observed that oral leukoplakia was seen in 4 subjects, OLP was seen in 5 subjects, oral erythroplakia was seen in 7 subjects and OSMF was seen in 9 patients. The results were comparable and observed to be statistically non-significant. [Fig 2]

Table 1: Types of Lip prints in both groups

Type of Lip prints	Number of patients		p-value
	Group 1 (n=25)	Group 2 (n=25)	
Type I	3	4	0.8
Type II	7	8	0.11
Type III	9	6	0.665
Type IV	6	7	0.15

Fig 1: Comparative analysis of types of lip prints in Group 1 and 2

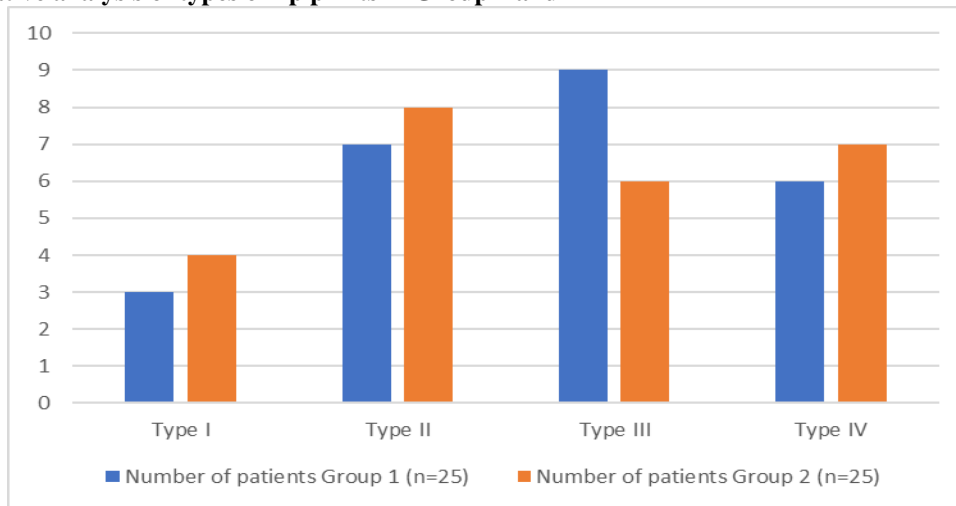
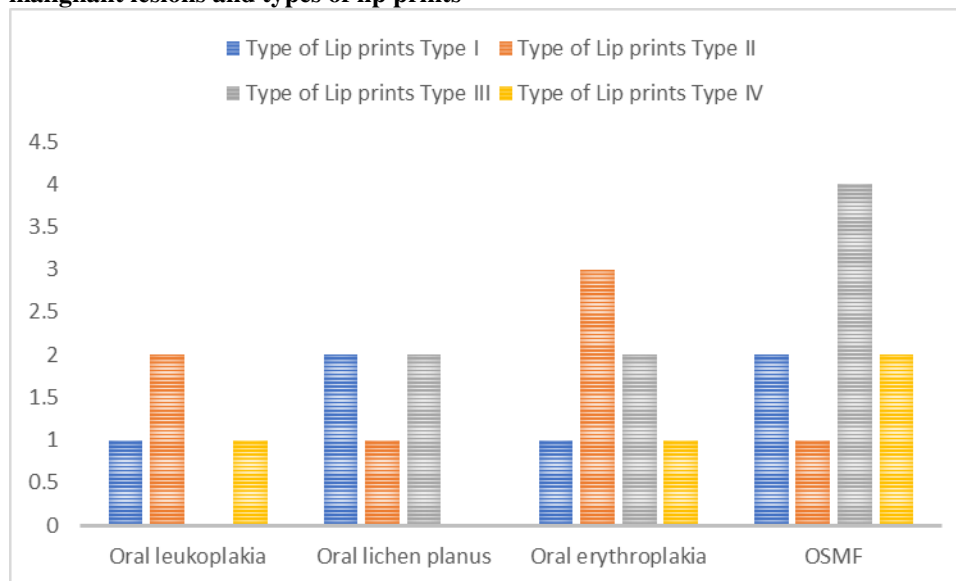


Table 2: Oral pre-malignant lesions and types of lip prints

Oral pre-malignant lesions	Type of Lip prints				Total	p-value
	Type I	Type II	Type III	Type IV		
Oral leukoplakia	1	2	0	1	4	0.221
Oral lichen planus	2	1	2	0	5	0.31
Oral erythroplakia	1	3	2	1	7	0.12
OSMF	2	1	4	2	9	0.8

Fig 2: Oral pre-malignant lesions and types of lip prints



DISCUSSION:

The present study was planned analyze lip prints pattern in patients with oral pre-malignant lesions. We observed that non-significant association of lip prints with oral pre-malignant lesions is present. The results were compared with previous researches. Gupta A et al analyzed the palmar dermatoglyphics in SCC and OSF and find a dermatoglyphic marker, if any. 120 individuals were divided into four groups based upon their habits of tobacco/areca nut usage and presence of OSF/SCC. Dermatoglyphic patterns were recorded using standard ink method. Various patterns were analysed statistically in the four groups. In SCC, there was an increase in frequency of arch and ulnar loop patterns on fingertips, decrease in frequency of simple whorl patterns on fingertips, decrease in frequency of palmar accessory triradii on right and left hands. Significant findings in OSF included an increase in frequency of arch and ulnar loop pattern, decrease in frequency of simple whorl patterns on fingertips, decrease in atd angle on right hand, decrease in frequency of palmar accessory triradii on right hand. The results revealed that the field of dermatoglyphics holds promising results for determining the genetic susceptibility of individuals to develop SCC and OSF. Devi A et al evaluated the visible lip patterns in Rajasthan population

in relation to the gender and to ascertain the existence of hereditary pattern followed among parents and offsprings. The second aim was to compare visible and latent lip print patterns on non-biological materials like tracing paper, microscopic glass slides and stainless steel tumblers. The lip prints of 300 subjects including 25 families were obtained using lipstick. Out of these 300 individuals, 60 were selected for latent lip prints. In order to prevent any intra- and inter-observer variability single observer carried out all the observations. The lip prints were analyzed using magnifying lens and were classified using the criteria given by Suzuki and Tsuchihashi. The determination of the pattern in each segment of the lip was based on the numerical superiority of properties of the lines on the fragment. The most predominant pattern in the entire study population among upper and lower lips considering both males and females was type III lip pattern. Hereditary resemblance was observed between parents and offsprings in 37.66%. The latent lip prints were better visualized on microscopic glass slide when compared to stainless steel tumblers. They concluded that the lip prints have a good potential for use in criminal investigations. They have been used only occasionally despite their frequent occurrence at crime scenes.^{7, 8}

Saujanya K et al analyzed the various pattern types of lip prints and dermatoglyphics in parents of CL(P) children and to detect if any specific type can be contemplated as a genetic marker in the transmission of CL(P). (2) To compare these patterns with that of parents of unaffected children. Materials and Methods: 31 parents of children with CL(P) as a study group, and 31 parents of unaffected children as control group were included. Lip prints and finger prints were collected from all subjects and analysis of both patterns was carried out followed by a comparison of the patterns of unaffected parents with the controls statistically. Results: Among the mothers of the study group, type O followed by type IIa lip patterns were found to be significantly higher in upper and lower lips, and in fathers type IIa followed by type O were significantly higher. In the control group, type IIb followed by type III were higher in both fathers and mothers. Dermatoglyphic analysis of palm and finger prints revealed no significant difference in the pattern types and total ridge counts, but the Atd angle asymmetry was found to be significant between study and control group. Conclusion: Types IIa and O lip patterns, asymmetry of Atd angles can be considered as genetic markers for the transmission of CL(P) deformity to offsprings. Jatti D et al compared the dermatoglyphic patterns of such patients, in patients without habits and in patients with habits but with no lesions. Materials and Methods: Fingerprints and palm prints were studied in 90 patients of Karnataka origin, who were randomly divided into three groups: (A) 30 subjects with OSMF, OL and OSCC, (B) 30 patients with habits and no lesions, and (C) 30 healthy controls, for the purpose of finding patterns that could identify patients with PMDs and OSCC. Finger and palm prints were taken by the ink method. Prints were analysed by two examiners and were repeated 1 month later. Results: The results were tested for statistical significance. Weighted kappa statistics were used to evaluate the inter- and intra-observer agreement. It was observed that the arch pattern (60.7%) was pre-dominant with a decrease in whorl pattern (29.3%) in group A when compared with the controls (group B and C) and the difference was highly significant ($P < 0.01$). The study group demonstrated an increase in the mean total finger ridge count as compared to the controls and the result was found to be highly significant ($P < 0.02$). The kappa-value for interobserver agreement was 0.675 and for intraobserver agreement it was 0.747.

CONCLUSION:

From the results of the present study, we conclude that the association of lip prints with oral pre-malignant lesions is non-significant. Further studies are required to support the hypothesis.

REFERENCES:

1. Utsuno H, Kanoh T, Tadokoro O, Inoue K. Preliminary study of post mortem identification using lip prints. *Forensic Sci Int* 2005;149:129–32.
2. Caldas IM, Magalha T, Afonso A. Establishing identity using cheiloscopy and palatoscopy. *Forensic Sci Int* 2007;165: 1–9.
3. Molano MA, Gil JH, Jaramillo JA, Ruiz SM. Estudioqueiloscópicoenestudiantes de la facultad de odontología de la Universidad de Antioquia. *Rev Fac Odontol Univ Antioquia* 2002;14:26–33.
4. Neville B, Damm D, Allen C, Bouquot J. *Oral and Maxillofacial Pathology* 2nd edn. Philadelphia: WB Saunders, 2002:763–74.
5. van der Waal I. Potentially malignant disorders of the oral and oropharyngeal mucosa; terminology, classification and present concepts of management. *Oral Oncol.* 2009;45:317–323.
6. Thomas G, Hashibe M, Jacob BJ, Ramadas K, Mathew B, Sankaranarayanan R, Zhang ZF. Risk factors for multiple oral premalignant lesions. *Int J Cancer.* 2003;107:285–291.
7. Gupta A, Karjodkar FR. Role of dermatoglyphics as an indicator of precancerous and cancerous lesions of the oral cavity. *Contemporary Clinical Dentistry.* 2013;4(4):448-453.
8. Devi A, Astekar M, Kumar V, Kaur P, Singh N, Sidhu GK. The study of inheritance analysis and evaluation of lip prints in individuals. *Forensic Dent Sci.* 2015 Jan-Apr; 7(1): 49–53.
9. Saujanya K, Prasad M G, Sushma B, Kumar J R, Reddy Y, Niranjani K. Cheiloscopy and dermatoglyphics as genetic markers in the transmission of cleft lip and palate: A case-control study. *J Indian Soc PedodPrev Dent* 2016;34:48-54
10. Jatti D, Kantraj YB, Nagaraju R. Role of dermatoglyphics in malignant and potentially malignant disorders of the oral cavity: A cross-sectional study. *J Indian Acad Oral Med Radiol*2014;26:379-84.

Source of support: Nil

Conflict of interest: None declared

This work is licensed under CC BY: **Creative Commons Attribution 3.0 License.**