

Case Report

Nonsurgical healing of large peri-radicular lesions using a triple antibiotic paste: A case series

Vinisha Pandey¹, Subhra Dey², Mansi Luthra³, Reshu Singh⁴, Pranav⁵, Silpi Chatterjee⁶

¹Reader, Department of Conservative dentistry and Endodontics, Maharana Pratap Dental College, Kanpur, U.P.

²Reader, Department of Conservative dentistry and Endodontics, Siddhartha Institute of Dental Sciences, Vijaywada, A.P.;

³Post graduate student, Department of Conservative dentistry and endodontics, K.D. Dental College, Mathura, U.P.;

⁴Reader, Department of Prosthodontics, Hazaribagh College of dental sciences and hospital, Demotand, Hazaribagh, Jharkhand;

⁵Reader, Department of Pedodontics and Preventive dentistry, Mithila Minority Dental College, Darbhanga;

⁶Senior lecturer, Department of Public Health Dentistry, Hazaribagh College of Dental Sciences and Hospital, Demotand, Hazaribagh, Jharkhand, India

ABSTRACT:

Periapical lesions develop as sequelae to pulp disease or as a result of a chronic aggression by the presence of pathogenic microorganisms into the root canal. They often occur without any episode of acute pain and are discovered on routine radiographic examination. Microbial invasion of the pulpal tissues occurs either through dental caries, trauma or any developmental tooth anatomy causing pulpal infection and subsequent pulpal necrosis. The necrotic root canal system provides a very favorable environment for the growth of microorganisms inside the root canal system. In the era of minimally invasive dentistry, non-surgical endodontic approach has been highly recommended to promote periapical healing which involves Lesion Sterilization and Repair Therapy (LSRT). The case report series below describes the regression of the periradicular lesion using nonsurgical endodontic treatment (LSRT) that uses a combination of triple antibiotics paste (ciprofloxacin, metronidazole and minocycline). The triple antibiotic paste was used for 3 months. After 3 months, teeth were asymptomatic and were obturated. The follow up cases showed progressive healing of periradicular lesions.

Key words: Lesion Sterilization and Repair Therapy, Triple antibiotic paste.

Received: 22 August, 2019

Revised: 11 October, 2019

Accepted: 12 October, 2019

Corresponding Author: Dr. Vinisha Pandey, Reader, Department of Conservative dentistry and Endodontics, Maharana Pratap Dental College, Kanpur, U.P., India

This article may be cited as: Pandey V, Dey S, Luthra M, Singh R, Pranav, Chatterjee S. Nonsurgical healing of large peri-radicular lesions using a triple antibiotic paste: A case series. J Adv Med Dent Scie Res 2019;7(11):158-162.

INTRODUCTION

Microorganisms lodged in the root canal system plays an important role in the development and maintenance of periapical and periradicular lesions. The necrotic root canal system provides a very favourable

environment for the growth of microorganisms inside the root canal system. Thus, the elimination of these bacteria is of great importance for apical and periapical healing after endodontic treatment be it surgical or nonsurgical. Microorganisms creating

periapical pathology produce toxic products in periapical tissues, and contain endotoxins in their cell wall. Management of the teeth with pulp necrosis and chronic periapical reaction should not only be concerned with bacterial death, but also the inactivation of endotoxin[1,2]. A large periradicular lesion may have direct communication with the root canal system and respond favourably to non surgical treatment. Clinical studies show that simple non surgical treatment with proper infection control promotes healing of large periapical lesions.

Researchers have developed the concept of 'Lesion Sterilization and Tissue Repair (LSTR)' therapy that uses a triple antibiotic paste of ciprofloxacin, metronidazole, and minocycline, for disinfection of oral infectious lesions, including dentinal, pulpal, and periradicular lesions. The drug of choice is Metronidazole because of its wide antibacterial spectrum against gram negative bacteria and obligate anaerobes. However, some bacteria are resistant to metronidazole, and hence, ciprofloxacin and minocycline are added to the mix. The combination of drugs has been shown to penetrate efficiently through dentine from the prepared root canals especially from the ultrasonically irrigated root canals. The commercially available drugs are powdered and mixed in a ratio of 1:3:3 (3 Mix) and mixed either with macrogol-propylene glycol (3 Mix-MP) or a canal sealer (3 Mix-sealer). A 1:1:1 ratio of the drug combination has also been used. Although the volume of the drugs applied in this therapy is small, care should be taken to check if the patients are sensitive to chemicals or antibiotics. A disadvantage of the triple antibiotic paste is tooth discoloration induced by minocycline. Cefaclor and fosfomycin are proposed as possible alternatives for minocycline, in terms of their antibiotic effectiveness, but further clinical studies are needed to demonstrate their efficacy in the root canal. [3-5]

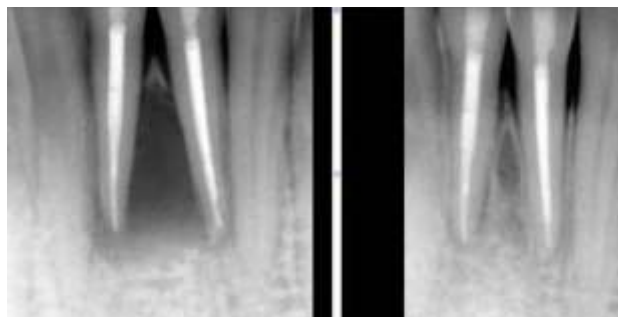
The ultimate goal of endodontic therapy should be to return the involved teeth to a state of health and function without surgical intervention.[6-10] All inflammatory periapical lesions should be initially treated with conservative nonsurgical procedures. Surgical intervention is recommended only when nonsurgical techniques have failed. Moreover, surgical techniques have major drawbacks which limit its use in the routine management of periapical lesions. Various studies have reconfirmed that non-surgical treatment with adequate infection control can help to create favorable environment in the healing of large periapical lesions upto 85%.

The following case reports describe the endodontic treatment of a large peri-radicular lesion using a combination of antibiotics drugs.

CASE 1

A 27-year-old male was referred to the department of Conservative Dentistry and Endodontics because of swelling in his left mandibular region. His medical status was noncontributory. According to the patient's clinical records, he reported a history of pain with pus discharge from lower front teeth 1 month back.

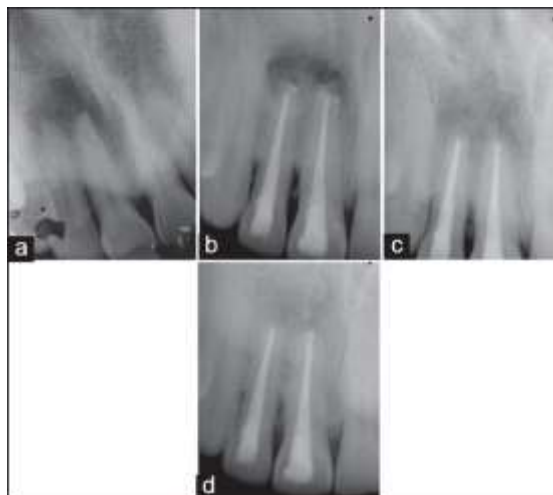
On intraoral examination, there was a hard swelling of the buccal vestibule in the concerning region covered with normal mucosa. Tooth 31 and 41 were slightly tender to percussion with probing and exhibited normal mobility. The electronic pulp test was negative for tooth. Radiograph showed a well circumscribed radiolucent lesion located around the apex of tooth 31 and 41. The lesion was approximately 10 mm in maximum diameter. After evaluating all the data, a root canal treatment was planned. At the same appointment, the root canal treatment was initiated. A hemorrhagic, purulent exudates was found from the teeth. The working length was estimated using an apex locator. The canals were instrumented with size 15-40 K files. During the instrumentation, the canal was irrigated copiously with 3% sodium hypochlorite solution using a 27-gauge endodontic needle after each instrument. Drainage was performed until the discharge through the canal ceased. The canals were dried with sterile paper points and a sterile cotton pellet was inserted into the access cavity before sealing it with a temporary filling material. After 3 weeks, the discharge from the canals did not cease completely. The treatment procedure was changed. The canals were irrigated and the smear layer was removed with 17% EDTA followed by 3% sodium hypochlorite. The canals were dried, and a triple antibiotic paste consisting of ciprofloxacin, metronidazole and minocycline (100 mg of each drug in 0.5 ml total volume) was placed with the help of a lentulo spiral. The compounding of the antibiotic paste was standardized the case. The paste was changed every month for a period of 3 months until the teeth displayed no symptoms. On examination, the teeth showed no pain on percussion, soft tissues were found healthy, and the canals were dry. The canals were irrigated with 3% sodium hypochlorite followed by normal saline and obturated with gutta percha and AH plus by using a lateral compaction technique. The restoration was accomplished with glass ionomer cement. After 12 months and 16 months, the radiographs showed complete bony healing with well-defined trabeculae.



CASE 2

A 19 year old male was referred to the Department of Conservative Dentistry and Endodontics with a chief complaint of pain and swelling in his upper right front region. His medical status was noncontributory. After questioning, it was learnt that 5 years back he had got his upper jaw hurt in an accident. It was at that point of time he came to our department.

An extraoral examination revealed a diffuse, swelling on the right side of upper lip. An intraoral examination showed discoloured and tender maxillary right central and lateral incisors. The lesion was approximately 13x17 mm in maximum diameter. After evaluating all the data, a root canal retreatment of teeth 11 and 21 was planned. A rubber dam was applied, and the access cavities were prepared. The drainage of pus was noted from both teeth. Both teeth were instrumented to ISO size 50 by using the step back technique. During instrumentation, the canals were irrigated with 3% sodium hypochlorite and then dried and dressed with triple antibiotic paste. After 3 weeks, the swelling had subsided, but the patient complained of a constant dull pain and heaviness in the concerned region. The canals were wet and showed mild discharge. The treatment procedure was changed. The canals were irrigated and dried; a triple antibiotic paste was replenished, and the teeth were temporized. The paste was changed every month for a period of 3 months until the teeth displayed no symptoms. After 3 months the canals were irrigated with 2.5% sodium hypochlorite and obturated with gutta percha and AH plus. The restoration was accomplished with composite resin. The patient returned to the department for the 1-year follow-up examination and was asymptomatic. Radiographic examination showed progressive healing of lesion.



DISCUSSION

Microorganisms creating periapical pathology produce toxic products in periapical tissues, and contain endotoxins in their cell wall. Management of the teeth with pulp necrosis and chronic periapical reaction should not only be concerned with bacterial death, but also the inactivation of endotoxin.

In this study, triple antibiotic paste was used. After its application, the symptoms resolved. Since the overwhelming majority of bacteria in the deep layers of the infected dentine of the root canal wall consist of obligate anaerobes, [4] metronidazole was selected as the first choice among antibacterial drugs. It is reported that metronidazole can penetrate the deep layers of carious lesions and disinfect the lesions *in vivo* and diffuse throughout the dentine. As the bacterial flora of the root canal with a periradicular lesion is complex in nature [13] metronidazole alone cannot kill all bacteria indicating that other drugs may be necessary to sterilize the infected root dentine. Thus, ciprofloxacin and minocycline, in addition to metronidazole were required to sterilize the infected root dentine.

Research with topical antibiotics has shown that a combination of metronidazole, ciprofloxacin, and minocycline is effective in killing common endodontic pathogens from necrotic/infected root canals *in vitro*. This antibiotic combination is also an effective disinfectant *in vivo*. Furthermore, the triple antibiotic paste has been used successfully in regenerative endodontic treatments [15] and in healing of large periradicular lesions.

Caution should be taken in general when giving local or systemic drugs. Although the volumes of the drugs applied in this therapy were small and there were no reports of side effects, care should be taken if patients are sensitive to chemicals or antibiotics.

The compounding of the triple antibiotic paste was standardized in this series of cases. Each batch of the

triple antibiotic pastes was compounded within 24 h of use and was removed from the canals after every 1 month of placement for 3 months. The antibiotic paste contained 100 mg of each of the three antibiotics in a total volume of 0.5 ml. The pharmaceutical carrier propylene glycol was used. These ingredients allow increased solubility and delivery of the paste into the canal. Aqueous solutions of antibiotics can often degrade and this degradation is increased by a rise in temperature and pH.

Healing of the periapical lesion usually occurs with hard tissue regeneration that is characterised by reduction of the radiolucency on follow-up radiographs.

One unbiased method of reviewing systematic radiographs is the Periapical Index (PAI). The PAI is a scoring system of radiographic apical periodontitis that can be used not only for epidemiological and clinical trials but also in retrospective analysis of treatment results. The PAI allows assessment of periapical condition from radiographic images. The index is based on an ordinal scale made of five scores ranging from 1 (healthy) to 5 (severe periodontitis with exacerbating features). (Figure 1).

In terms of success and failure Ørstavik and his colleagues suggest that a root filled tooth with PAI 4 or 5 should be deemed a definite failure, but would not consider a tooth for re-treatment with a score of 3 and would deem such treated teeth as a success.

It must be realised that when deciding if a treatment is successful or not, this must depend on which definition of success is used. Definitions of success have previously been summarised elsewhere. Previous work has suggested that the term healing/disease should be used rather than success/failure. This defined *healing* as reduced radiolucency and clinical normality. *Healed* was defined as no clinical signs, symptoms or radiolucency. Finally, *disease* was defined as either persistent radiolucency or new radiolucency development with or without clinical signs.

| Fig. 9 The periapical index ^{6,7} |
|---|
| PAI 1 - Normal periapical structure |
| PAI 2 - Small changes in bone structure not pathognomic for apical periodontitis |
| PAI 3 - Changes in bone structure with some mineral loss characteristic of apical periodontitis |
| PAI 4 - Periodontitis with well defined radiolucent area |
| PAI 5 - Severe periodontitis with exacerbating features and bone expansion |

CONCLUSION

Nonsurgical management of periapical lesions have shown a high success rate. A nonsurgical approach should always be adopted before resorting to surgery. Various methods can be used in the nonsurgical management of periapical lesions: the conservative root canal treatment, decompression technique, active nonsurgical decompression technique, aspiration-irrigation technique, method using calcium hydroxide, Lesion Sterilization and Repair Therapy, and the Apexum procedure. Monitoring the healing of periapical lesions is essential through periodic follow-up examinations.

The decompression and aspiration-irrigation techniques can be used when there is drainage of cystic fluid from the canals. These techniques act by decreasing the hydrostatic pressure within the periapical lesions. When there is no drainage of fluid from the canals, calcium hydroxide or the triple antibiotic paste can prove beneficial. Periodic follow-up examinations are essential and various assessment tools can be used to monitor the healing of periapical lesions. The surgical approach can be adopted for cases refractory to nonsurgical treatment, in obstructed or nonnegotiable canals and for cases where long-term monitoring of periapical lesions is not possible.

REFERENCES

1. Byström A, Sundqvist G (1981) Bacteriologic evaluation of the efficacy of mechanical root canal instrumentation in endodontic therapy. *Scand J Dent Res*89:321-328.
2. Tronstad L, Barnett F, Riso K, Slots J (1987) Extraradicular endodontic infections. *Endod Dent Traumatol*3:86-90.
3. Gomes BP, Souza SF, Ferraz CC, Teixeira FB, Zaia AA, et al. (2003) Effectiveness of 2% chlorhexidine gel and calcium hydroxide against *Enterococcus faecalis* in bovine root dentine in vitro. *IntEndod J* 36: 267-275.
4. Athanassiadis B, Abbot PV, Walsh LJ (2007) The use of calcium hydroxide, antibiotics and biocides as antimicrobial medicaments in endodontics. *Australian Dent J* 52:S64-S82.
5. Soares JA, Leonardo MR, da Silva LA, TanomaruFilho M, Ito IY (2006) Effect of rotary instrumentation and of the association of calcium hydroxide and chlorhexidine on the antiseptics of the root canal system in dogs. *Brazil Oral Res* 20: 120-126.
6. Mori GG, Ferreira FC, Batista FRS, Godoy MAS, Nunes DC (2009) Evaluation of the diffusion capacity of calcium hydroxide pastes through the dentinal tubules. *Brazil Oral Res* 23: 113-118.
7. Negri MR, Panzarini SR, Poi WR, Sonoda CK, Gulinelli JL, et al. (2008) Analysis of the healing process in delayed tooth replantation after root canal filling with calcium hydroxide, Sealapex and Endofill: a microscopic study in rats. *DentTraumatol*24: 645-650.

8. de la Casa ML, Salas MM, López ME, Raiden G (2008) Protein content in irrigation solutions in contact with pulp tissue. *Acta Odontol Latinoam* 21: 65-68.
9. Estrela C, Bammann LL, Pimenta FC, Pécora JD (2001) Control of microorganism in vitro by calcium hydroxide pastes. *Int Endod J* 34: 341-345.
10. Estrela C, Estrela CR, Hollanda AC, Decurcio D de A, Pecora JD (2006) Influence of iodoform of antimicrobial potential of calcium hydroxide. *J Appl Oral Sci* 14: 33-37.
11. Csukas Z, Ferenczi I, Nasz I, Banoczy J. Diffusion of metronidazole through the dentinal tubules of extracted teeth. *Acta Microbiol Hung.* 1987;34:121-4. [PubMed: 2894107]
12. Hoshino E, Kurihara-Ando N, Sato I, Uematsu H, Sato M, Kota K, et al. In-vitro antibacterial susceptibility of bacteria taken from infected root dentine to a mixture of ciprofloxacin, metronidazole and minocycline. *Int Endod J.* 1996;29:125-30. [PubMed: 9206436]
13. Ozan U, Er K. Endodontic treatment of a large cyst like periradicular lesion using a combination of antibiotic drugs: A case report. *J Endod.* 2005;31:898-900. [PubMed: 16306827]
14. Jung IY, Lee SJ, Hargreaves KM. Biologically based treatment of immature permanent teeth with pulpal necrosis: A case series. *J Endod.* 2008;34:876-87. [PubMed: 18571000]
15. Kusgoz A, Yildirim T, Er K, Arslan I. Retreatment of a resected tooth associated with a large periradicular lesion by using a triple antibiotic paste and mineral trioxide aggregate: A case report with a thirty-month follow-up. *J Endod.* 2009;35:1603-6. [PubMed: 19840657]