

Original Article

Clinicopathological Correlation of Non Infectious Erythematous Papulosquamous Lesions of Skin

Gurpal Kaur, K.S.Chahal, S.K. Malhotra

Department of Pathology, GMC Amritsar, Punjab, India

ABSTRACT:

Introduction: Papulosquamous diseases are a heterogeneous group of disorders which assume considerable importance because of their frequency of occurrence. The nosology of these disorders is based on a descriptive morphology of clinical lesions which are characterised by scaling papules or plaques as seen by dermatologist. Separation of each of these diseases becomes important because the treatment and prognosis for each tends to be disease specific. **Aim:** To analyse various clinical and histopathological patterns of non- infectious erythematous, papulosquamous lesions of the skin and to assess the correlation of provisional clinical diagnosis and histopathological diagnosis. **Material and methods:** This present study included 100 cases presenting with clinical features of non infectious, erythematous papulosquamous skin disorders were included in the study, irrespective of age and sex reporting in the Pathology Department, Govt. Medical College, Amritsar, after approval from Institutional Ethical Committee and after taking informed consent of the patient. History and clinical examination of each patient was recorded on a self designed proforma. Final diagnosis was made on the basis of the histopathological findings. **Results:** A total of 100 biopsies were taken. Mean age of the study population in this study came out to be 39.44 ±16.35 years and male predominance. Majority of cases (53%) were histopathologically diagnosed as Psoriasis. While 23% cases were of Lichen planus, 11% cases of lichen planus pigmentosum, 3% cases of lichen planus hypertrophicus, 1% cases of lichen nitidus, 4% cases of lichen chronicus, 1% of lichenoid drug reactions, 2% pityriasis rosea, 1% prurigonodularis, and 1% of pityriasis rubra pilaris. Overall a positive Correlation with the histopathological diagnosis was positive in 74% cases and negative in 26% cases. **Conclusion:** Clinicopathological correlation is mandatory as the pathologist's ability to render an accurate diagnosis depends on the available clinical information. Therefore, dermatopathology is important for more definite differentiation as Separation of each of these lesions becomes important because the treatment and prognosis for each tends to be disease specific.

Key words: Clinical features, Histopathological features, Papulosquamous lesions, Psoriasis, Lichen planus.

Received: 5 January 2019

Revised: 25 January 2019

Accepted: 28 January 2019

Corresponding Author: Dr. K.S.Chahal, Department of Pathology, GMC Amritsar, Punjab, India

This article may be cited as: Kaur G, Chahal KS, Malhotra SK. Clinicopathological Correlation of Non Infectious Erythematous Papulosquamous Lesions of Skin. J Adv Med Dent Sci Res 2019;7(2):131-135.

INTRODUCTION:

Papulosquamous diseases are a heterogeneous group of disorders whose etiology primarily is unknown. The nosology of these disorders is based on a descriptive morphology of clinical lesions which are characterised by scaling papules or plaques as seen by dermatologist.¹ These diseases assume considerable importance because of their frequency of occurrence. Separation of each of these diseases becomes important because the treatment and prognosis for each tends to be disease specific.²

The spectrum of clinical diseases related to non-infectious, erythematous, papular and squamous lesions are namely psoriasis, parapsoriasis, lichen planus, prurigo simplex, prurigo nodularis, pityriasis rosea, pityriasis rubra pilaris and many more. Few papulosquamous

conditions like psoriasis mimic diverse dermatological conditions as they present with numerous clinical variants and pose to be a diagnostic dilemma for the clinician.³

Therefore, keeping in mind the dilemma of diagnosis of these lesions, an attempt should be made to analyse various histopathological patterns of non- infectious erythematous, papulosquamous lesions of the skin based on the tissue reaction pattern and to assess the concordance of provisional clinical diagnosis and histopathological diagnosis.

Thus, the present study is an attempt to analyse various clinical and histopathological patterns of non- infectious erythematous, papulosquamous lesions of the skin and to assess the correlation of provisional clinical diagnosis and histopathological diagnosis.

MATERIAL AND METHODS:

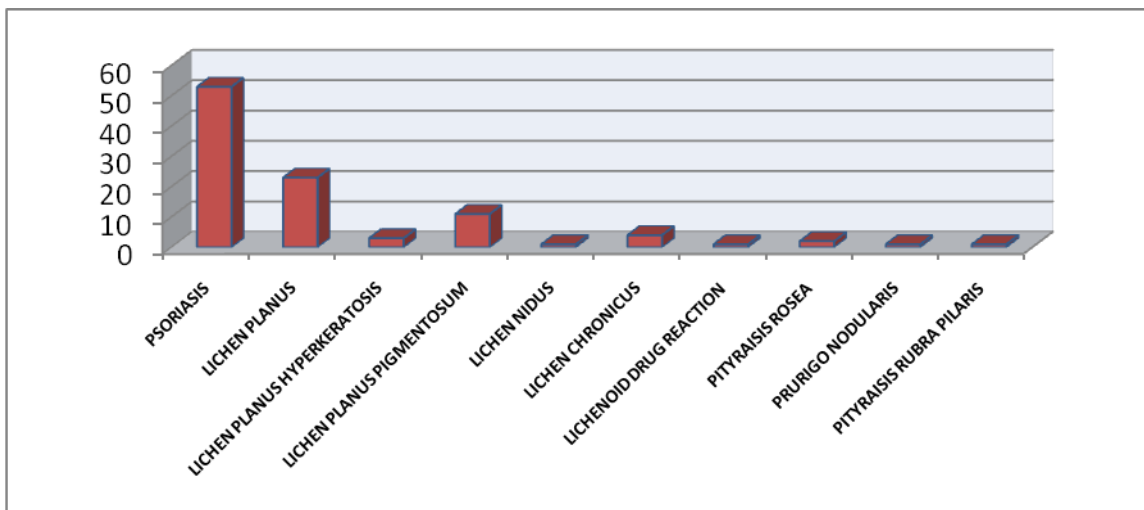
This study included 100 cases reporting in the Pathology Department, Govt. Medical College, Amritsar, after approval from Institutional Ethical Committee and after taking informed consent of the patient. History and clinical examination of each patient was recorded on a self designed proforma. All patients presenting with clinical features of non infectious, erythematous papulosquamous skin disorders were included in the study, irrespective of age and sex. Skin disorders with infective etiology and other skin lesions which were not papulosquamous disorders were excluded. Paraffin embedded tissue sections were stained with routine haematoxylin and eosin stain (H&E) and diagnosis was made on the basis of the histopathological findings.

RESULTS:

A total of 100 biopsies were taken from the study group. Mean age of the study population in this study came out to be 39.44 ±16.35 years, with maximum number of cases in the age group 21-30 years. Male: Female ratio in the study came to be: 1.2:1, thus showing male predominance.

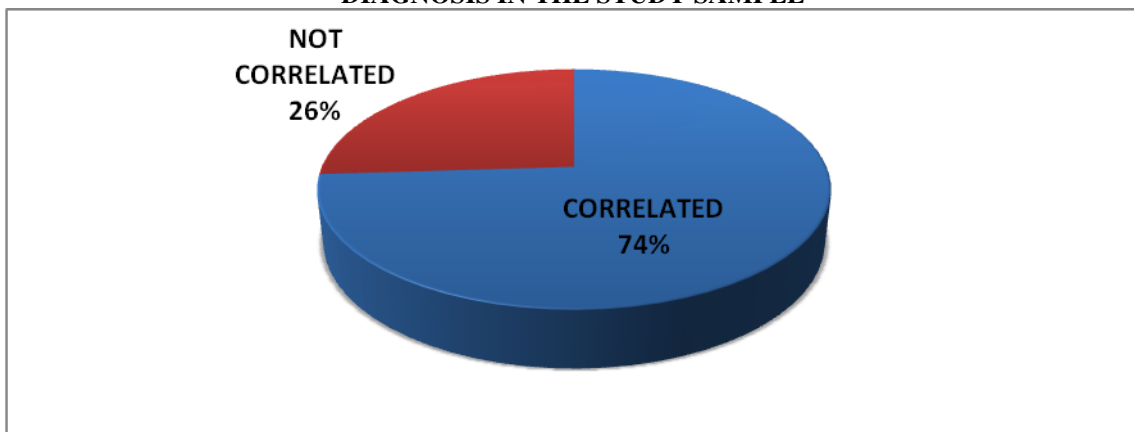
Out of total samples taken, majority of cases (53%) were histopathologically diagnosed as Psoriasis. While 23% cases were of Lichen planus, 11% cases of lichen planus pigmentosum, 3% cases of lichen planus hypertrophicus, 1% cases of lichen nitidus, 4% cases of lichen chronicus, 1% of lichenoid drug reactions, 2% pityriasis rosea, 1% prurigo nodularis, and 1% of pityriasis rubra pilaris.(graph 1)

GRAPH 1: DISTRIBUTION OF CASES OF PAPULOSQUAMOUS DISEASES IN THE STUDY



From the results, it was observed that 74% cases showed positive correlation with the clinical diagnosis where as 26% cases showed discordance within clinical and histopathological diagnosis.(graph 2)

GRAPH 2: CASES SHOWING CORRELATION OF CLINICAL DIAGNOSIS AND HISTOPATHOLOICAL DIAGNOSIS IN THE STUDY SAMPLE



Out of all the cases included under this category, 32.1 % cases of Psoriasis, 13.1 % cases of Lichen planus, 33.3 % cases of Lichen planus hypertrophicus, 9 % cases of Lichen planus pigmentosum, 100 % cases of Lichen nitidus, 50 % cases of Lichen chronicus and 100 % cases of Lichenoid drug reaction showed discordance with the clinical diagnosis.(table 1)

TABLE 1: LIST OF CASES SHOWING DISCONCORDANCE WITH HISTOPATHOLOGICAL DIAGNOSIS IN THE STUDY SAMPLE

S.No	HISTOLOGICALLY DIAGNOSED CASES	TOTAL NO OF CASES	NO. OF CASES SHOWING POSITIVE CLINICO-PATHOLOGICAL CORRELATION	NO. OF CASES SHOWING DISCONCORDANCE WITH HISTOPATHOLOGICAL DIAGNOSIS
1	PSORIASIS	53	36 (67.9%)	17 (32.1%)
2	LICHEN PLANUS	23	20 (86.9%)	3 (13.1%)
3	LICHEN PLANUS HYPERTROPHICUS	3	2 (66.6%)	1 (33.3%)
4	LICHEN PLANUS PIGMENTOSUM	11	10 (90.9%)	1 (9%)
5	LICHEN NIDUS	1	0	1 (100%)
6	LICHEN CHRONICUS	4	2 (50%)	2 (50%)
7	LICHENOID DRUG REACTION	1	0	1 (100%)
	TOTAL	96*	70 (72.91%)	26 (27.08%)

The most common diagnosis in our study was of psoriasis. It was seen that Out of 53 cases of psoriasis 36 were clinically diagnosed and confirmed histopathologically correctly. Rest 17 cases, confirmed histopathologically as Psoriasis showed different clinical presentations. 6 cases (35.2%) cases presented clinically as eczema, 4 cases (23.5%) as dermatitis herpatiformis and lichen planus each and 1 case (5.8%) as Bowens disease, lichenoid eruption and lichen simplex chronicus each. Also, only 2 cases which were clinically diagnosis as Psoriasis, showed a varied histopathological picture of lichen planus.

Out of 23 cases of Lichen planus in the present study, 20 cases were clinically diagnosed and confirmed histopathologically correctly. Rest 3 cases, confirmed histopathologically as Lichen planus showed different clinical presentations. 2 cases (66.6%) cases presented clinically as Psoriasis and 1 case (33.3%) presented as discoid lupus erythematosus. 4 cases which were clinically diagnosed as lichen planus, showed a varied histopathological picture of Psoriasis.

Out of 11 cases of Lichen planus pigmentosus, 10 cases were clinically diagnosed and confirmed histopathologically correctly. While rest 1 case, confirmed histopathologically as Lichen planus pigmentosus showed different clinical presentations of Discoid lupus erythematosus. Out of 4 cases of Lichen Simplex chronicus, 2 cases were clinically diagnosed and confirmed histopathologically correctly. While rest 2 cases, confirmed histopathologically as Lichen Simplex chronicus showed different clinical presentations of eczema and atrophic dermatitis.

Out of 3 cases of Lichen planushypertrophicus, 2 cases were clinically diagnosed and confirmed histopathologically correctly. While rest 1 case, confirmed histopathologically as Lichen planushypertrophicus showed a different clinical presentation of eczema. 1 case of Lichen nidus and 1 case of lichenoid drug reaction confirmed histopathologically in the present study, both presented as Lichen planus hypertrophicus clinically.

Thus over all our results showed that, in the present study Correlation with the histopathological diagnosis was positive in 74% cases and negative in 26% cases. The contribution of histopathology to the final diagnosis was significant.(Table 2)

Table 2: Overall Results

DESCRIPTION	NUMBER OF CASES	%AGE
Histopathology confirmed diagnosis	74	74%
Histopathology gave diagnosis	26	26%

DISCUSSION:

As its crucial to identify and classify these lesions, the present study was conducted to study the age, sex distribution and histopathological spectrum of non-infectious, erythematous, Papulosquamous Skin Diseases with clinico-histopathological correlation.

The age distribution pattern in the present study showed that mean age of the study population in this study came out to be 39.44 ±16.35 years with male predominance. Balaji C et al⁴ and Yonus et al³ also showed that majority of cases are seen in the age group of 21-30 years. Like wise D’Costa et al³ and Rajasekhar et al⁶ also reported male preponderance in their respective studies.

The results of the present study revealed that the most frequently encountered lesion out of total 100 samples was histologically diagnosed as Psoriasis (53%). While rest in descending order were: 23% cases were of Lichen planus, 11% cases of lichen planuspigmentosum, 4% cases of lichen chronicus, 3% cases of lichen planus hypertrophicus, 2% pityriasis rosea, 1% cases each of of lichen nitidus, lichenoid drug reactions, prurigonodularis, and pityriasisrubrapilaris. In accordance to our results, Younas M et al,⁵ Reddy et al⁶ and D’Costa and Bhamambe BM et al.³ also reported psoriasis to be the most predominant lesion in their studies.

Psoriasis:

In the present study, psoriasis showed a mean age of 30-40 years (38.11±18.23 years), with 58.45% males and 41.5% of female population.

Table 3: Age incidence and gender predominance of psoriasis as reported by other authors:

Study	Year	Age range	Gender predominance
Mani ⁷	2006	41-50 years	Female predominance
Dogra S et al ⁸	2010	30-40 years	-
D'Costa and Bharambe BM et al ³	2010	30-40 yeas	Male predominance
Karumbaiah K.P. et. al. ⁹	2017	21-30 years	Male predominance
Balaji et al ⁴	20018	31-40 years	-

In cases of psoriasis, We reported positive clinico-histopathological correlation in 67.79% cases while this correlation was absent in 32.1% cases.

Those cases of with histopathologically confirmed diagnosis of Psoriasis with different clinical presentation we came across in our study, presented most commonly as eczema, followed by dermatitis herpatiformis, lichen planus and least common were as Bowens disease, lichenoid eruption and lichen simplex chronicus. Mani et al reported that in their study only 1 case had no clinical suspicion of psoriasis, which was diagnosed as leprosy. While the most common differential diagnosis for psoriasis was contact dermatitis.⁷

In the present study, clinically diagnosed lichen planus (23%), showed a mean age of 42.56±16.39 years, with 47.8% males and 52.1% of female population. Many authors suggest that the common age group affected is 30-60 years, but cases have been reported at extremes of age.¹⁰

Reddy et al reported that Lichen planus constituted the highest percentage of cases i.e. (58.83%) followed by hypertrophic lichen planus (18.67%), lichen planus pigmentosus (12.50%) and lichen planopilaris (10%).⁶

In the present study positive clinico- histopathological correlation in 86.9% cases while this correlation was absent in 13.1% cases. Reddy et al, reported that in 24 cases of lichen planus, clinical and pathological correlation was seen in 21 cases (87.5% correlation). 3 non correlated cases were clinically diagnosed as Lichen simplex chronicus.⁶

Like our study Psoriasis was the commonest clinical differential in study by Maniet al.⁷ Guttate forms of psoriasis may be mistaken for LP.¹¹

Further, the results regarding age and gender predominance of lichen planus pigmentosum in our study showed that, lichen planus pigmentosum (11%) had a mean age of 38.55±10.52 years, with 36.3% males and 63.6% of female population. In the present study regarding lichen planus pigmentosum, positive clinic-histopathological correlation in 90.9% cases while this correlation was absent in 9% cases.

The results regarding age and gender predominance of lichen Simplex chronicus in showed that, clinically diagnosed cases of lichen chronicus (4%) showed a mean age of 55±1.76 years, with 50% male and 50% of female population. A positive clinic-histopathological correlation in 50% cases while this correlation was absent in 50% cases.

Lichen planus hypertrophicus cases (3%) showed a mean age of 44.33±19.85 years, with 100% male population. A

positive clinic-histopathological correlation in 66.6% cases while this correlation was absent in 33.3% cases.

In the present study after psoriasis and lichen planus and its variants remaining lesions constitute just 6% of these lesions. Among them were predominantly pityraisisrosea, followed by lichen nidus, lichenoid drug reaction, Prurigo Nodularis and Pityraisis rubra pilaris.

Thus over all our results showed that, in the present study Correlation with the histopathological diagnosis was positive in 74% cases and negative in 26% cases. The results given by various authors are as follows: Younas et al (76.30%)⁵, Reddy et al (86.25%)⁶, Grace et al (97.52%),³Balaji et al (68.72%)⁴, Sushmahosamane et al (46.67%)¹²,Chaudharyraju et al (68.72%)¹³ and Agarwal S e al (58%).¹⁴

Thus we can say from the results of this present study that the contribution of histopathology to the final diagnosis is definitely significant.

CONCLUSION:

To overcome the clinical confusion which may result in difficult diagnosis, recognition of these commonly encountered cutaneous problems, familiarity of clinical presentation and the diagnosis confirmed with histopathology which is the gold standard are important. Clinicopathological correlation is mandatory as the pathologist's ability to render an accurate diagnosis depends on the available clinical information. Therefore, dermatopathology is important for more definite differentiation as separation of each of these lesions becomes important because the treatment and prognosis for each tends to be disease specific.

REFERENCES:

1. Werner B. Skin biopsy and its histopathologic analysis: Why? What for? How? Part I. AnaisBrasileiros de Dermatologia. 2009 Aug;84(4):391-5.
2. Fox BJ, Odom RB. Papulosquamous diseases: a review. J Am AcadDermatol. 1985 Apr;12(4):597-624.
3. D' Costa G, Bharambe BM. Spectrum of non-infectious erythematous, papular and squamous lesions of the skin. Indian J Dermatol. 2010;55(3):225-8.
4. Balaji, Chowdari & Parvathi, Metta & Satish Kumar, Seeram & Divya Lekha, Gunta & Lavanya, Latchupatula & Vidya Soundarya Lahari, Mantripragada & Atla, Bhagyalakshmi. Clinicopathological study of papulosquamous skin lesions. Journal of Evidence Based Medicine and Healthcare 2018;5: 699-704.
5. Younas M, Haque A. Spectrum of Histopathological Features in Non Infectious Erythematous and Papulosquamous Diseases. International Journal of Pathology. 2004;2(1):24-30.

6. B. Rajasekhar Reddy, Nalini Krishna.M. Histopathological spectrum of non-infectious erythematous, papulo-squamous lesions . Asian Pac. J. Health Sci., 2014; 1(4S): 28-3
7. Anand M. Histological spectrum of papulosquamous lesions of skin, encountered at M.S. Ramaiah Medical College from January 2003 to December 2005. Unpublished Doctoral Dissertation of Rajiv Gandhi University. Bangalore 2006.
8. Dogra S, Yadav S. Psoriasis in India: prevalence and pattern. Indian Journal of Dermatology, Venereology and Leprology 2010;76(6):595-601
9. Karumbaiah K.P., ArshiyaAnjum, Mallikarjun M. A Histopathologic Study of Papulosquamous Lesions of Skin. Indian Journal of Pathology: Research and Practice Volume 6 Number 2, April - June 2017 (Part 2).
10. Kim WB, Jerome D, Yeung J. Diagnosis and management of psoriasis. Canadian Family Physician. 2017;63(4):278-285.
11. Gibson.LE, PerryHO. Papulo squamous eruptions and exfoliative dermatitis. In: Moschella SL, Hurley HJ, editors. Dermatology. 3rded. Philadelphia:WB Saunders Company;1992.p.607551.
12. Sushma Hosamane, MukthaPai, Thoppil Reba Philipose, Umaru Nayarmoole. Clinicopathological Study of Non-Infectious Erythematous Papulosquamous Skin Diseases Journal of Clinical and Diagnostic Research. 2016 Jun, Vol-10(6): EC19-EC22
13. ChaudharyRaju G., ChauhanAnkur P., Makwana Vaishali R., ModiKhushbu R Study of Clinico-histopathological Correlation of Papulosquamous Disorders at Tertiary Care Hospital. Sch. J. App. Med. Sci., 2015; 3(3B):1154-1158.
14. SonalAgrawal, K.B. Mishra, C.M. Gupta. Histopathological spectrum of non-infectious erythematous, papulosquamous lesions: at a tertiary care in situ. Int J Res Med Sci. 2018 Jun;6(6): 2072-2075

Source of support: Nil

Conflict of interest: None declared

This work is licensed under CC BY: *Creative Commons Attribution 3.0 License*.