

## Case Report

### Fixed Twin Block- A Clinically Effective Appliance in Growth Modification of Class II Malocclusion- Case Presentation

Kamna Srivastava<sup>1</sup>, Tripti Tikku<sup>2</sup>, Rohit Khanna<sup>3</sup>, Rana Pratap Maurya<sup>4</sup>, Sneha Lata Verma<sup>5</sup>, Anshul Srivastava<sup>6</sup>

<sup>1,4,5</sup>Reader, <sup>2</sup>Prof & HOD, <sup>3</sup>Professor, <sup>6</sup>Senior Lecturer

Department of Orthodontics and Dentofacial Orthopaedics, Babu Banarasi Das College of Dental Sciences (BBDCODS), BBDU, Lucknow, Uttar Pradesh, India

#### ABSTRACT:

Functional appliances have been used for decades in correcting skeletal Class II malocclusion in growing patients. This two phase therapy of growth modification and subsequent fixed orthodontic treatment is an accepted procedure with certain advantages like-better esthetics, ability to modify growth, fewer extractions, reduction in duration and difficulty of subsequent therapy, reduce if not eliminate the need for future surgery and reduction in trauma to flared incisors. Twin block appliance designed by Clark has been widely accepted. It brings about correction of sagittal discrepancy by skeletal changes and dentoalveolar compensation. As with any removable appliance compliance was a major concern in patients at the peak of or close to the end of pubertal growth spurt. Fixed twin block was designed to overcome these limitations. The clinical effectiveness of fixed twin block in correcting skeletal Class II malocclusion will be illustrated by three case presentations.

**Key words-** fixed, twin block, growth, class II malocclusion

Received: 22 December, 2019

Accepted: 21 January, 2020

**Corresponding author:** Dr. Kamna Srivastava, Reader, Department of Orthodontics and Dentofacial Orthopaedics, Babu Banarasi Das College of Dental Sciences (BBDCODS), BBDU, Lucknow, Uttar Pradesh, India

**This article may be cited as:** Srivastava K, Tikku T, Khanna R, Maurya RP, Verma SL, Srivastava A. Fixed Twin Block- A Clinically Effective Appliance in Growth Modification of Class II Malocclusion- Case Presentation. J Adv Med Dent Scie Res 2020;8(2):119-126.

#### INTRODUCTION

Class II Div 1 malocclusion is the commonly encountered problem in the orthodontic practice. There are many types of functional appliance designs available for use in the correction of Class II Div 1 malocclusion. In the recent years Twin block appliance designed by Clark in 1982 has gained worldwide acceptance for treating skeletal Class II malocclusion.<sup>1</sup>

The skeletal changes observed with successful twin block therapy were restraining effect on forward growth of maxilla, forward repositioning of mandible and increase in ramus height.<sup>2-11</sup> The dentoalveolar changes

observed were mesial movement of mandibular molars, proclination of lower incisors, distal movement of upper molars and retroclination of upper incisors.<sup>2-11</sup>

Many studies have proved the effectiveness of twin block appliance in treating Class II malocclusions.<sup>2-10</sup> The improved response of the Twin-block (and Herbst) appliances over other functional appliances was due to the fact that they are worn 24 hours a day<sup>6</sup>. Long term studies by Panchrez<sup>12</sup> on Herbst appliance have shown that changes observed during functional stage were temporary. But, in the study by Mills and McCulloch (1998)<sup>3</sup> it has been shown that results are stable. Mills

and McCulloch (2000)<sup>8</sup> in another study evaluated post treatment changes 3 years after successful correction achieved with twin block therapy. According to them, though there was a trend towards smaller mandibular growth increment after the treatment, much of the significant increase in mandibular length achieved was still present 3 years later. According to them settling of posterior occlusion occurring in twin block therapy decreased the chances of relapse compared to other functional appliances like Herbst.

Despite of clinically effective changes with Clark's twin block, patient's compliance was still a major concern. Hence, fixed version of twin block design was successfully used to treat Class II malocclusion in patients who reported for the treatment at the peak of or close to the end of pubertal growth spurt when compliance is a major concern for any growth modification procedure. The clinical effectiveness of fixed twin block in treating patients exhibiting Class II malocclusion will be demonstrated by three case presentations.

#### **DESIGN OF FIXED TWIN BLOCK DESIGN**

The basic design of fixed twin block is shown in Figure 1. Wire framework of 1mm S.S wire was adapted closely around premolars and erupted molars in the upper arch. Transpalatal wire of 1mm S.S was soldered to wire framework on both the sides to provide rigidity to the appliance. In the lower unit of twin block wire was adapted along the lingual surface of mandibular incisors and extended onto buccal and lingual aspect of first premolars. Blocks were made to be locked at 70° to the occlusal plane and lower blocks did not extend beyond distal marginal ridge of second premolars to allow for eruption of lower molars. Lower incisor capping was done to decrease proclination of lower incisors so as to maximize the skeletal correction of sagittal discrepancy.

#### **CASE 1**

##### **Diagnosis**

A female patient aged 12.7 years came with chief complaint of forwardly placed upper teeth. The dental and medical history was unremarkable. Clinical examination revealed convex profile with acute nasolabial angle, incompetent lips, deep mentolabial sulcus and retrusive mandible. The patient had Class II molar relationship on both the sides with spacing in the maxillary arch. The patient exhibited increased freeway space of 4mm.

The cephalometric parameters revealed orthognathic maxilla, retrognathic mandible with good chin form, horizontal growth pattern, decreased lower facial height, proclined maxillary incisors and upright mandibular incisors. Patient had increased increased overjet of 9mm and increased overbite of 6.5mm. Cervical vertebrae maturation stage was CVMS III ( Bacceti and McNamara,2002<sup>13</sup>).

#### **Treatment Objectives**

- To correct skeletal discrepancy to achieve balanced profile.
- To bring about leveling, alignment and coordination of arches.

#### **Treatment Alternatives**

1. Phase I treatment of growth modification using functional appliance followed by phase II treatment for detailing of occlusion.
2. Orthodontic camouflage with premolar extractions in the upper arch.
3. Surgical advancement of mandible after the growth is completed.

#### **Treatment Plan**

As the patient was circumpubertal, growth modification in the form of fixed twin block therapy was chosen. The esthetic appearance of the patient improved when mandible was postured forward. Intermolar width was within normal limits and on advancement no transverse discrepancy was observed. Mandible was advanced to 5mm with vertical opening of 5mm.

After achieving desired sagittal and vertical correction patient would be put on fixed appliance for final detailing of occlusion. This treatment plan obviated the need of premolar extractions in the upper arch.

#### **Treatment Progress**

Fixed twin block was designed as shown and cemented using glass ionomer cement.

The patient's compliance was good and did not report with breakages during the treatment except for occasional recementations. After 2 months of wear, upper twin block was removed using anterior band removing plier and trimmed to allow for eruption of lower molars. It was recemented after cleaning the tooth surfaces. At each visit upper twin block was trimmed to allow lower molars to erupt. This active phase of treatment was accomplished in 8 months followed by retentive phase for another 3 months. Patient was given anterior guide plane with labial bow during the retentive phase. Presently, patient is in Phase II for finishing and detailing of occlusion using preadjusted edge wise appliance (022 slot).

Pre and post functional photographs, lateral cephalogram and cephalometric superimpositions are shown in figure 2.

#### **Treatment Results**

The changes in various parameters are shown in Table 1. The custom made KJJ/CJM analysis<sup>3,8</sup> was used to find linear measurements to reference plane. Reference Plane (RP) was constructed at palatal plane perpendicular to Sella.

**TABLE 1: Cephalometric parameters for Case 1**

	PARAMETERS	PRE	POST	DIFF
<b>Skeletal Parameters</b>	SNA	80°	81°	1
	SNB	76°	79°	3
	ANB	4°	2°	2
	Mn Plane Angle (SN Go-Gn)	25°	25°	0
	Mn body length (Go-Gn)	73 mm	75mm	2
	Mn Unit Length (Co-Gn)	103 mm	107 mm	4
	Ar-Pog	97 mm	100 mm	4
	Mx base length (Co-PointA)	86 mm	86 mm	0
	Ramus height (Co-Go)	54 mm	57 mm	3
	Ant Facial Height	103 mm	106 mm	3
	Post Facial Height	71 mm	75 mm	4
<b>Dental Parameters</b>	Overjet	9 mm	3 mm	6
	Overbite	6.5mm	3.5mm	2.5
	Mx incisor to SN	110°	108°	2
	Mx Incisor to RP	75 mm	74.5 mm	0.5
	Mn Incisor to Go-Gn	102°	105° mm	3
	Mn incisor to RP	66 mm	68 mm	2
	Mx molar to Palatal Plane	20 mm	20 mm	0
	Mx Molar to RP	41 mm	40 mm	1
	Mn Molar to Go-Gn	25 mm	28 mm	3
	Mn Molar to RP	39 mm	45 mm	6

There was increase in SNB of 3°, increase in SNA of 1° and reduction in ANB from 4° to 2°. The maxillary base length remained the same. Articulare-Pog (Ar-Pog) distance increased by 4.5mm and mandibular unit length (condylion-gnathion) increased by 4mm. Mandibular body length (Go-Gn) showed an increase of 2mm. Ramus height increased by 3mm. Mandibular plane angle did not show any change as anterior facial height increased by 3mm whereas posterior facial height increased by 4mm. There was change in inclination of 2° in the upper incisors and they retracted 0.5mm in relation to RP. The proclination of lower incisors showed an increase of 3°. There was mesial movement of mandibular molars. There was overjet reduction of 6mm.

## CASE 2

A female patient 12.5 years old came with a chief complaint of forwardly placed teeth. Patient was skeletal Class II with orthognathic maxilla, retrognathic mandible with good chin form, decreased lower facial height and horizontal growth pattern. She had mildly proclined maxillary and upright mandibular incisors. She had end on molar and canine relationship bilaterally with increased overjet and overbite. Freeway space was adequate (4mm).

The patient was in CVM stage III as per cervical maturation stages<sup>13</sup>. As the patient was circumpubertal growth modification procedure in the form of fixed twin block was selected for her. Mandible was advanced by 5mm and vertical opening was kept at 5mm. Active phase of twin block lasted for 9 months followed by retentive phase for 3 months. After Phase I treatment, the patient was put on fixed appliance (preadjusted edgewise appliance, 0.22 slot) for alignment, leveling and coordination of arches.

The most notable changes were increase in SNB of 2°, reduction in SNA of 1°, reduction in ANB of 3°, increase in mandibular unit length of 5mm, increase in mandibular body length of 2.5 mm and increase in ramus height of 4mm. There was no change in maxillary base length. Anterior facial height increased by 4mm. Upper incisors showed lingual tipping of 1°. Lower incisors proclination increased by 2°. Mandibular molars moved mesially by 5.5mm. Overjet reduced by 5mm and overbite reduced by 4mm.

Pre and post functional photographs, lateral cephalogram and cephalometric superimpositions are shown in figure 3.

**Table 2** lists cephalometric parameters for this patient.

	PARAMETERS	PRE	POST	DIFF
<b>Skeletal Parameters</b>	SNA	83°	82°	1
	SNB	77.5°	79.5°	2
	ANB	5.5°	2.5°	3
	Mn Plane Angle (SN Go-Gn)	29°	31°	2
	Mn body length (Go-Gn)	74 mm	76.5mm	2.5
	Mn Unit Length (Co-Gn)	107 mm	112 mm	5
	Ar-Pog	99 mm	104 mm	5
	Mx base length (Co-PointA)	92 mm	92mm	0
	Ramus height (Co-Go)	50 mm	54mm	4
	Ant Facial Height	111 mm	115 mm	4
Post Facial Height	72.5 mm	75 mm	2.5	
<b>Dental Parameters</b>	Overjet	7mm	2mm	5
	Overbite	6.5mm	2.5mm	4
	Mx incisor to SN	108°	107°	1
	Mx Incisor to RP	67mm	67.5 mm	0.5
	Mn Incisor to Go-Gn	108°	110° mm	2
	Mn incisor to RP	63 mm	68 mm	5
	Mx molar to Palatal Plane	21 mm	21 mm	0
	Mx Molar to RP	33 mm	33 mm	0
	Mn Molar to Go-Gn	25 mm	28 mm	3
Mn Molar to RP	39 mm	45 mm	6	

**CASE 3**

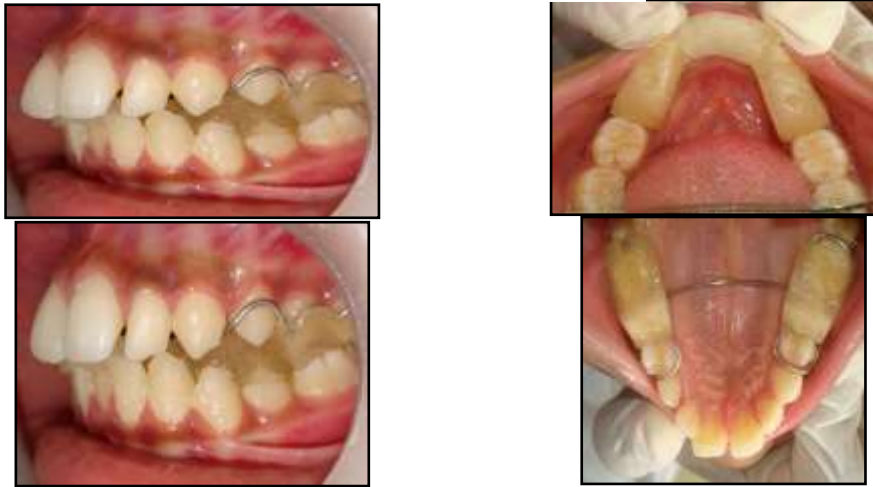A female patient aged 12 years and 9 months came with a chief complaint of forwardly placed upper teeth. Patient was skeletal class II with similar clinical findings. Patient had orthognathic maxilla, retrognathic mandible, reduced lower facial height, horizontal growth pattern, proclined maxillary incisors, upright mandibular incisors, increased overjet and overbite. As per cervical maturation stage, she was in CVM stage IV. As she was almost at the end of pubertal growth spurt, it was decided to carry out phase I therapy using fixed twin block. Active phase lasted for 9 months and retentive phase lasted for 3 months. Pre and post functional photographs, lateral cephalogram and cephalometric superimpositions are shown in figure 4.

**TABLE 3: Cephalometric parameters for CASE 3**

	PARAMETERS	PRE	POST	DIFF
<b>Skeletal Parameters</b>	SNA	81°	82°	1
	SNB	77°	80°	3
	ANB	4°	2°	2
	Mn Plane Angle (SN Go-Gn)	27°	30°	3
	Mn body length (Go-Gn)	75mm	77 mm	2
	Mn length (Co-Gn)	110 mm	114 mm	4
	Ar-Pog	99 mm	103 mm	4
	Mx base length (Co-Point A)	88 mm	89 mm	1
	Ramus height (Co-Go)	54.5 mm	57 mm	2.5
	Ant Facial Height	109 mm	114 mm	5
Post Facial Height	74.5 mm	77 mm	2.5	
<b>Dental Parameters</b>	Overjet	9 mm	3 mm	6
	Overbite	7mm	3mm	4
	Mx incisor to SN	112°	108°	4
	Mx Incisor to RP	67 mm	65.5 mm	1.5
	Mn Incisor to Go-Gn	99°	104°	5
	Mn incisor to RP	58.5 mm	61.5 mm	3
	Mx molar to Palatal Plane	19 mm	19 mm	1
	Mx Molar to RP	31 mm	30.5 mm	0.5
	Mn Molar to Go-Gn	29 mm	32 mm	3
Mn Molar to RP	31.5 mm	35 mm	3.5	


Most notable changes were increase in SNB by 3°, reduction in ANB by 2°, increase in mandibular unit length (Co-Gn) by 4mm, increase in ramus height by 2.5mm, increase in mandibular plane angle by 3.5° and increase in lower facial height by 5mm. Upper incisors proclination was decreased by 4° and proclination of lower incisors increased by 5°. Overjet reduced by 6mm and overbite decreased by 4mm. The correction of molar relationship was achieved by mesial movement of mandibular molars.

**FIG 1: APPLIANCE DESIGN**

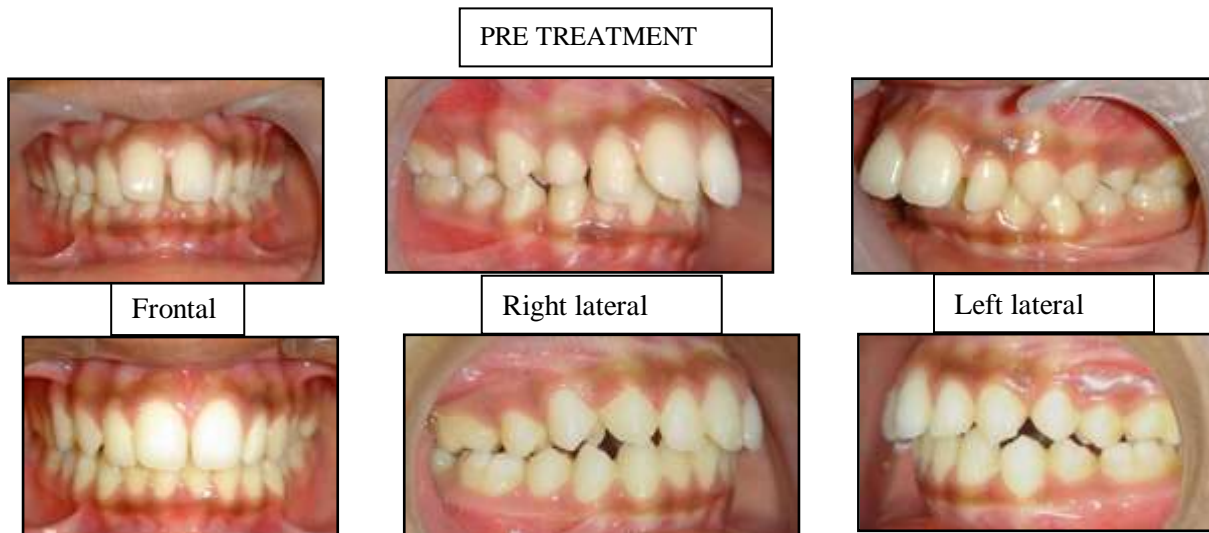


**CASE 1**

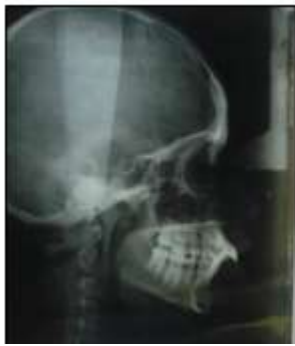**FIG : EXTRAORAL PHOTOGRAPHS**



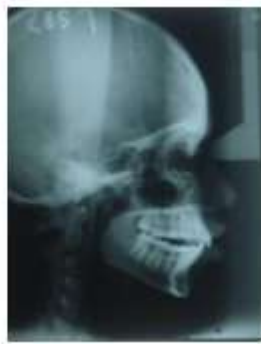**INTRAORAL PHOTOGRAPHS**



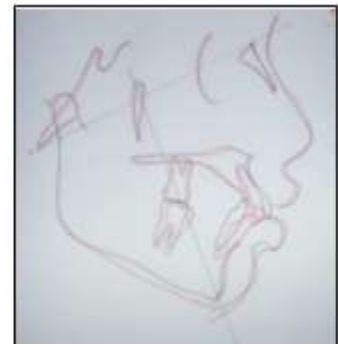**POST FUNCTIONAL INTRAORAL PHOTOGRAPHS**



**Pretreatment Lat Ceph**

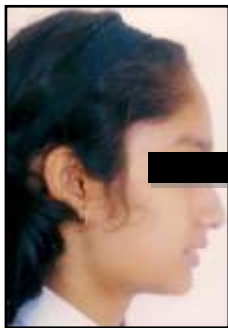

**Post functional Lat Ceph**

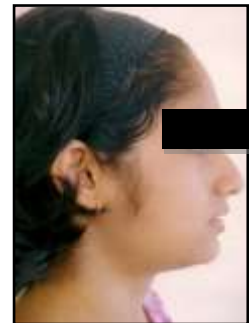

**Cephalometric Superimposition**

**FIG: EXTRAORAL PHOTOGRAPHS CASE 2**



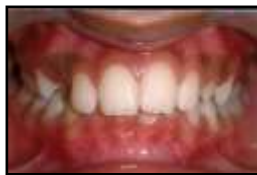**Pre**



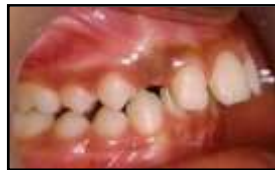**Post functional**

**Intral oral photographs**

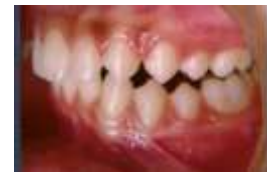**Pre-treatment**



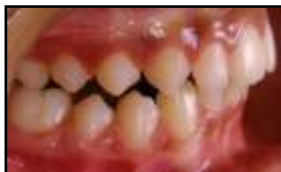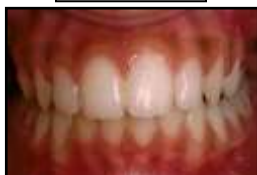**Frontal**



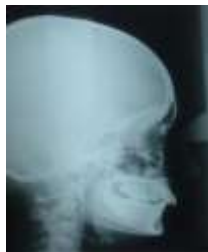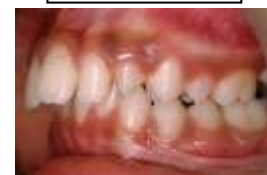**Right lateral**



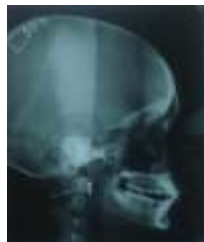**Left lateral**



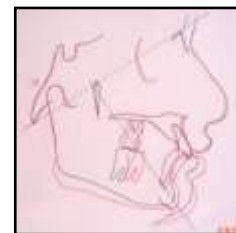**Post functional**



**Pre treatment Functional Lat Ceph**



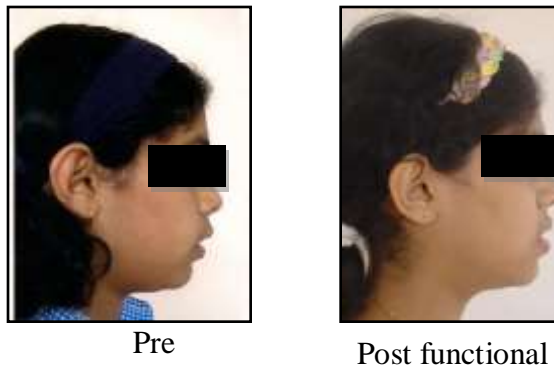
**Post Functional Lat Ceph**



**Ceph Superimposition**

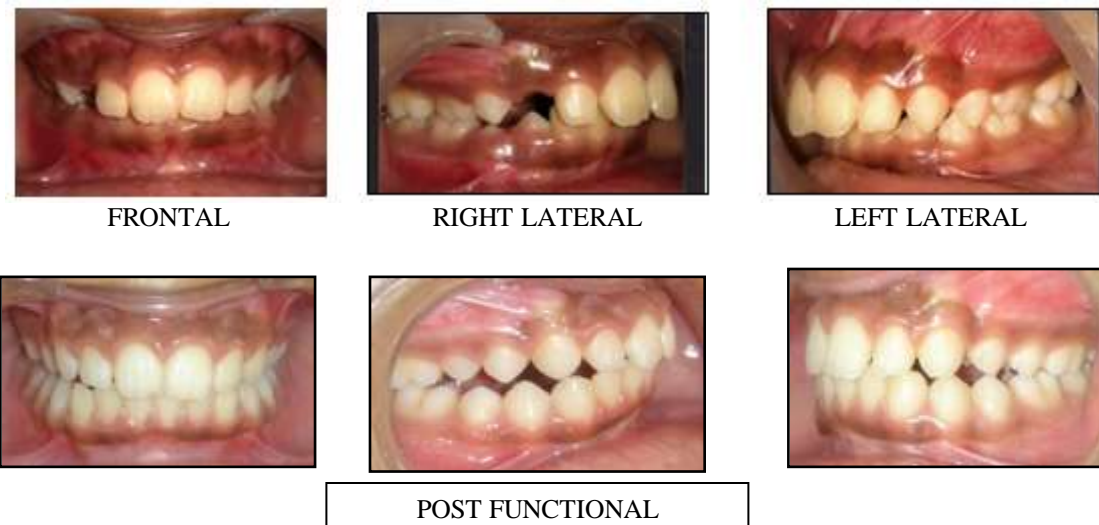**FIG: EXTRAORAL PHOTOGRAPHS CASE 3**

**PROFILE**



**INTRAORAL PHOTOGRAPHS**

**PRETREATMENT**



**CONCLUSION:**

Fixed twin block increased the likelihood of patient cooperation. The lack of palatal coverage by acrylic made the appliance more comfortable and lack of wire elements in the anterior region made it more esthetic for the patient. The skeletal and dental changes observed in three cases were similar to values obtained in the previous studies on removable twin block.<sup>2-10</sup> Saggital growth of maxilla was not restrained. The mandibular unit length (Co-Gn) increased by 4 to 5mm in three cases. This increase was much more in comparison to values obtained in untreated individuals with Class II malocclusions (2.3mm)<sup>14</sup>. About two third of this increase could be attributed to increase in ramus height (2.5-4mm) which was also more compared to growth in untreated individuals

(0.6mm)<sup>14</sup>. Another one third of increase was attributed to increase in mandibular body length of (2-2.5mm) which was more than increase in mandibular body length of 1.7mm in untreated individuals. An improvement in mandibular retrognathia could also be demonstrated by an increase in SNB.

The lingual tipping of upper incisors was seen only in case 3 as labial bow was used in retentive phase of twin block therapy. Lower incisor proclination was found to increase by 2o, 3o, and 4o in Case 1, 2 and 3 respectively. The correction of molar relationship to class I was achieved mainly by mesial movement of lower molars. Overjet reduction could be due to skeletal changes in mandible and to dental compensation in maxillary and mandibular incisors. Overbite reduction was observed because of lower

molar eruption, increase in ramus height and proclination of lower incisors.

It can be concluded fixed twin block appliance brought about skeletal and dental changes which helped in correction of Class II malocclusion. It allows an individual to gain its optimum growth potential. As Mills and McCulloch<sup>8</sup> stated intercuspation in posterior segment decreased the chances of relapse, the patients were put on fixed appliances for final detailing of occlusion. The benefits of two phase therapy like-better esthetics, ability to modify growth, fewer extractions, reduction in duration and difficulty of subsequent therapy, reduce if not eliminate the need for future surgery could be seen in these cases.

#### REFERENCES

1. Clark WJ. Twin block functional therapy: Applications in Dentofacial Orthopedics Turin: Mosby-Wolfe, 1995.
2. Lund DI and Sandler PJ. The effects of Twin Blocks: A prospective controlled study. *Am J Orthod Dentofacial Orthop.*1998; 113:104-110.
3. Mills CM and McCulloch KJJ. Treatment effects of the twin block appliance: A cephalometric study. *Am J Orthod Dentofacial Orthop.*1998; 114:15-24.
4. Illing HM, Morris DO, Lee RT. A prospective evaluation of Bass, Bionator and Twin Block appliances. Part 1-Hard tissues. *Eur J Orthod.*1998; 20:501-24.
5. Toth RL, McNamara JA. Treatment effects produced by the Twin-block appliance and the FR-2 appliance of Fränkel compared with an untreated Class II sample. *Am J Orthod Dentofacial Orthop.*1999; 116: 597-609.
6. O'Brien K, Wright J, Conboy F, Sanjie WE, Mandall N, Chadwick S, Connolly I et al. Effectiveness of treatment for class II malocclusion with Herbst Or Twin Block appliances: A randomized controlled trial. *Am J Orthod Dentofacial Orthop* 2003; 124: 128-137.
7. Trenouth MJ. Cephalometric evaluation of the Twin-block appliance in the treatment of Class II Division 1 malocclusion with matched normative growth data. *Am J Orthod Dentofacial Orthop* 2000; 117:54-9.
8. Mills CM and McCulloch KJJ. Post treatment changes following successful correction of class II malocclusion with the twin block appliance. *Am J Orthod Dentofacial Orthop* 2000; 118: 24-33.
9. Baccetti T, Franchi L, Toth RL, McNamara JA. Treatment timing for twin blocks therapy. *Am J Orthod Dentofacial Orthop.*2000; 118:159-170.
10. Šidlauskas A. Clinical Effectiveness of Twin Block Appliance in the treatment of Class II Division 1 Malocclusion. *Stomatologija, Baltic Dental and Maxillofacial Journal.* 2005; 7:7-10.
11. Sidlauskas A .The effects of the Twin-block appliance treatment on the skeletal and dentolaveolar changes in Class II Division 1 malocclusion. *Medicina (Kaunas)* 2005; 41(5): 392-399.
12. Pancherz H, Fackel U. The skeletofacial growth pattern in pre- and post-dentofacial orthopedics: A long-term study of Class II malocclusions treated with the Herbst appliance. *Eur J Orthod*1990; 12:209-18.
13. Baccetti T, Franchi L, McNamara JA. An improved version of the cervical vertebral maturation (CVM) method for the assessment of mandibular growth. *Angle Orthod* 2002; 72: 316-23.
14. Stahl F, Baccetti T, Franchi L, McNamara JA, Tollaro I. Longitudinal growth changes in untreated subjects with Class II Div 1 malocclusion. *Am J Orthod Dentofacial Orthop.*2008; 134: 125-37.