

ORIGINAL ARTICLE

Analysis of Small Bowel Obstruction in Patients Operated for Appendicitis- A Clinical Study

Manjush Kumar Srivastava¹, Ashwani Kumar Pandey²

¹Assistant Professor, ²Associate Professor, Department of Surgery, Mayo Institute of Medical Sciences Barabanki, U.P.

ABSTRACT:

Background: Appendectomy is one of the most common procedures performed which may be due to appendicitis or frequent pain in appendix. The present study was conducted to determine the cases of small bowel obstruction after appendectomy in study population. **Materials & Methods:** The present study was conducted on 58 cases of appendicitis of both genders who visited the department for the management of the same. In all patients, laproscopic appendectomy was planned. Patients were recalled regularly to note any kind of complication arising from the procedure. **Results:** Out of 58 patients, males were 38 and females were 20. The difference was significant (P- 0.5). Age group 20-30 years had 10 males and 8 females, 30-40 years had 9 males and 12 females and 40-50 years had 19 males and 10 females. The difference was significant (P- 0.01). In males, out of 58 cases, 2 cases were of SMO and in 1 female, SMO was observed in out of 20 cases. The prevalence rate found to be 5.17%. Macroscopic feature of appendix was phlegmonous in 1 case and gangrenous in 2 cases. The difference was significant (P- 0.01). **Conclusion:** Appendectomy is the frequently performed procedure in patients suffering from appendicitis. Small bowel obstruction is a complication which may be seen in few cases. In present study, the prevalence found to be 5.17%.

Key words: Appendectomy, Laproscopic, Small bowel

Corresponding Author: Dr. Ashwani Kumar Pandey, Associate Professor, Department of Surgery, Mayo Institute of Medical Sciences Barabanki, U.P., India

This article may be cited as: Srivastava MK, Pandey AK. Analysis of Small Bowel Obstruction in Patients Operated for Appendicitis- A Clinical Study. J Adv Med Dent Sci Res 2016;4(2):155-157.

INTRODUCTION

Appendectomy is one of the most common procedures performed which may be due to appendicitis or frequent pain in appendix. It is associated with various short and long-term morbidities. Few authors have demonstrated that laparoscopic approach for appendectomies has advantages over open technique such as decreased rate of wound infection and small bowel obstruction, shorter hospital stay, better cosmesis and less postoperative pain. Furthermore, it has also been observed diagnostic and therapeutic advantages with regard to the open technique, especially in fertile women. However, postoperative small bowel obstruction is considered as long term adverse effect of appendectomy. There is 0.2-10.7% prevalence rate of this complication.¹ They can have serious consequences for patients such as infertility, chronic abdominal pain or bowel obstruction. The management of intestinal adhesions depends on the symptoms and physical signs of the patients. Small bowel obstruction (SBO) is a pathological condition which occurs when the intestinal contents are prevented from moving along the length of the intestine. There are 2 types of small bowel obstruction, mechanical and neurogenic.² Mechanical SBO is due to physical occlusion,

either external or internal, of the gastrointestinal lumen. Neurogenic SBO (also known as adynamic ileus) results from intestinal paralysis. Jean et al³ in their study found 0.16% of small bowel obstruction following appendectomy. The present study was conducted to determine the cases of small bowel obstruction after appendectomy in study population.

MATERIALS & METHODS

The present study was conducted in the department of general surgery. It consisted of 22 cases of appendicitis of both genders who visited the department for the management of the same. All were informed regarding the study and written consent was obtained. Ethical clearance was taken before starting the study. General information such as name, age, gender etc. was recorded in cases history performa. In all patients, laproscopic appendectomy was planned. Patients were recalled regularly to note any kind of complication arising from the procedure. Results thus obtained were subjected to statistical analysis using chi-square test. P value less than 0.05 was considered significant.

RESULTS

Table I Distribution of patients

		Total- 58	
Males	Females		P value
38	20		0.5

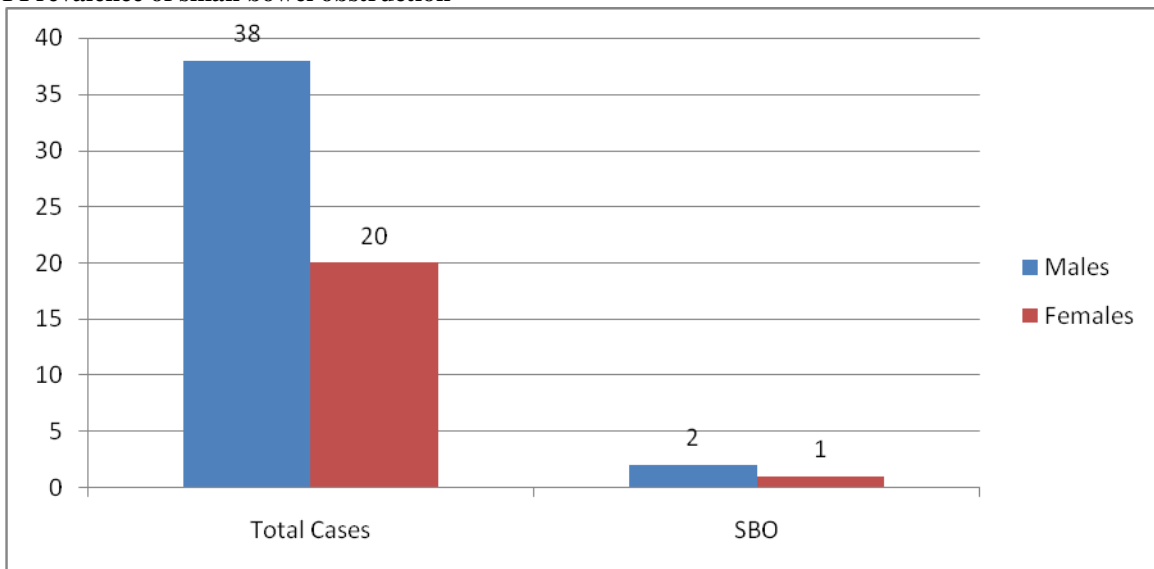
Table I shows that out of 58 patients, males were 38 and females were 20. The difference was significant (P- 0.5).

Table II Age wise distribution of patients

Age groups	Males	Females	P value
20- 30 years	10	8	0.01
30-40 years	9	12	
40- 50 years	19	10	
Total	38	20	

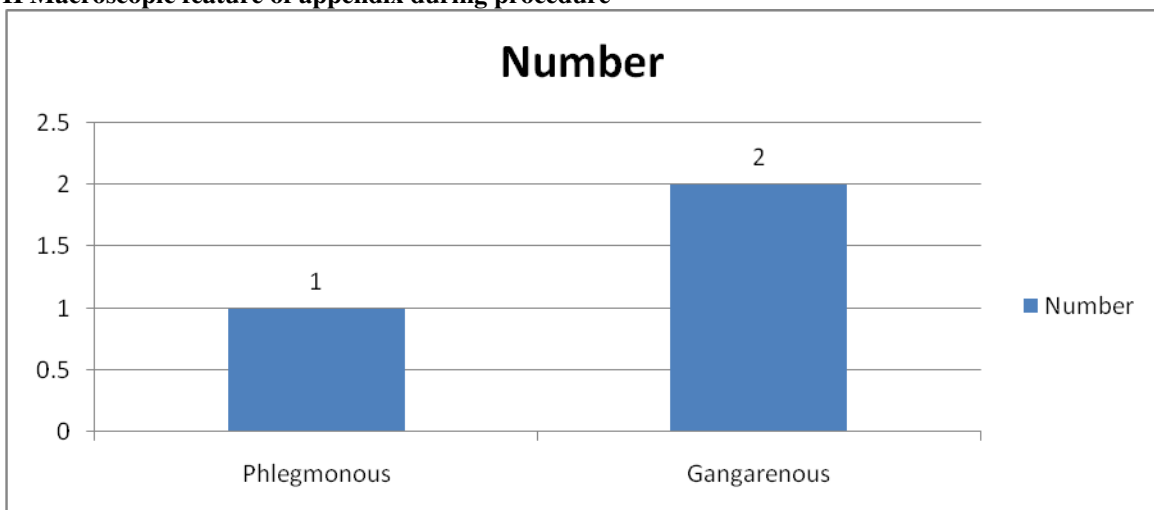
Table I shows that age group 20-30 years had 10 males and 8 females, 30-40 years had 9 males and 12 females and 40-50 years had 19 males and 10 females. The difference was significant (P- 0.01).

Graph I Prevalence of small bowel obstruction



Graph I shows that in males, out of 58 cases, 2 cases were of SMO and in 1 female, SMO was observed in out of 20 cases. The prevalence rate found to be 5.17%.

Graph II Macroscopic feature of appendix during procedure



Graph II shows that macroscopic feature of appendix was phlegmonous in 1 case and gangrenous in 2 cases. The difference was significant (P- 0.01).

DISCUSSION

Small bowel obstruction is a relevant clinical condition that can happen after an Intra-abdominal surgical intervention due to the development of peritoneal adhesions between abdominal tissues and organs. These adhesions are also called “flanges” by surgeons. Common pathophysiologic mechanisms leading to physical obstruction of the small bowel include postoperative adhesions, internal hernia, congenital bands, external hernia, post inflammatory adhesions, inflammatory bowel disease and carcinoma. Less common causes are foreign bodies, intussusception and tuberculosis. Carcinoma, diverticulitis and volvulus are major mechanisms of large bowel obstruction.⁴

In present study, we included 58 cases of appendectomy in which 38 were males and 20 were females. This is similar to Aden et al.⁵ Chakrabarty et al⁶ in their study revealed strangulated external hernia to be the most common etiology of intestinal obstruction.

In present study, age group 20-30 years had 10 males and 8 females, 30-40 years had 9 males and 12 females and 40-50 years had 19 males and 10 females. In a study by Khattar et al⁷, patients in delayed postoperative period were managed by conservative treatment in 7 cases and by open surgical intervention in 1 case. The mean onset of enteral feeding was 1.4 days and the mean of length of stay was 5.3 days. This complication was observed in a range of time intervals from 10 days to 9 years after the first surgical intervention.

We found that the prevalence rate was 5.17%. In males, out of 58 cases, 2 cases were of SMO and in 1 female, SMO was observed in out of 20 cases. Macroscopic feature of appendix was phlegmonous in 1 case and gangrenous in 2 cases. This is similar to Boyce et al.⁸ The use of different substances has significantly resulted in reduction of the formation of postoperative adhesion after an abdominal operation. Surgeons have tried experimentally to limit adhesion formation, despite the many different mechanisms involved. Attempts to remove fibrin exudate with proteolytic enzymes, prevent fibrin deposition with anticoagulants, or inhibit fibroblastic proliferation with steroids and antihistamines have not met with any great success. Various studies have documented the use of an off-the-shelf biomaterial which does not complicate the surgical procedure or impede healing. The ideal material would be easy to use in the operating environment, biocompatible, prevents adhesion during healing and would facilitate re-entry if required for subsequent surgery.⁹

Menzeles et al¹⁰, conducted a study on 1,734 patients, of which 17 patients developed bowel obstruction (1%). The mean age of the patients was 8.0 years. Overall, 70.6% were male and 29.4% were female. Bowel obstruction occurred in 12 patients in the immediate post-operative period, in 8 patients in the delayed post-operative period and in 3 patients in both periods.

Gamal et al¹¹ in their study found 6 patients developed SMO out of 607 patients who were treated with laproscopic appendectomy. Frequency of readmission of patients features of intestinal obstruction ranged from 1-6. In a study by Stewart et al¹², when the incidence curves were compared between appendectomy, splenectomy and cholecystectomy procedures, appendectomy indicated a statistically significant difference in the rate of small bowel obstruction for these three procedures.

CONCLUSION

Appendectomy is the frequently performed procedure in patients suffering from appendicitis. Small bowel obstruction is a complication which may be seen in few cases. In present study, the prevalence found to be 5.17%.

REFERENCES

1. Jackson HT, Kane TD. Advances in minimally invasive surgery in patients. *Adv Pediatr* 2014; 61(1):149-95.
2. Esposito C, Calvo AI, Castagnetti M, Alicchio F, Suarez C, Giurin I, et al. Open versus laparoscopic appendectomy in the study population: a literature review and analysis of complications. *J Laparoendosc Adv Surg Tech A* 2012; 22(8):834-9.
3. Jean, Lautz TB, Barsness KA. Adhesive small bowel obstruction-Acute management and treatment in adults. *Semin Pediatr Surg* 2014; 23(6):349-52.
4. Esposito C, Borzi P, Valla JS, Mekki M, Nouri A, Becmeur F, et al. Laparoscopic versus open appendectomy: A retrospective comparative study of 2,332 cases. *World J Surg* 2007;31(4):750-5.
5. Adden, Lautz TB, Raval MV, Reynolds M, Barsness KA. Adhesive small bowel obstruction in adolescents: operative utilization and factors associated with bowel loss. *J Am Coll Surg* 2011; 212(5):855-61.
6. Chakarwarty, Kravarusic D, Goldrat I, Steinberg R, Dlugy E, Baazov A, et al. The 16 golden hours for conservative treatment with postoperative small bowel obstruction. *J Pediatr Surg* 2010;45(5):966-8.
7. Khattar, Anderson SA, Beierle ED, Chen MK. Role of laparoscopy in the prevention and in the treatment of adhesions. *Semin Pediatr Surg.* 2014;23(6):353-6.
8. Boyce, Tsao KJ, St Peter SD, Valusek PA, Keckler SJ, Sharp S, Holcomb GW, et al. Adhesive small bowel obstruction after appendectomy in children: comparison between the laparoscopic and open approach. *J Pediatr Surg* 2007;42(6):939-42.
9. Molinaro F, Kaselas C, Lacreuse I, Moog R, Becmeur F. Postoperative intestinal obstruction after laparoscopic versus open surgery in the adult population: A 15-year review. *Eur J Surg* 2009;19(3):160- 2.
10. Mangelez, Zhang S, Du T, Jiang X, Song C. Laparoscopic appendectomy in patients with perforated appendicitis. *Surgery* 1990; 12: 521-527.
11. Gamal, Aken, Stui, Mena J. Postoperative small bowel obstruction in adults. *Ann Surg* 1982; 11: 580-583.
12. Stewart RM. The incidence and risk of early postoperative small bowel obstruction. *Am J Surg* 1987; 12: 643-647.