

Original Article

Guidelines for Safe Placement of Implant site assessing in both the Maxillary and Mandibular Jaw using CBCT- A third eye imaging

Santoshkumar P Mastud¹, Chaitra K², D M Sable³, Mahesh Chavan⁴, Sumit Bhateja⁵, Karan Bhargava⁶

^{1,4}Assistant Professor, ³Professor, Department of Oral Medicine and Maxillofacial Radiology, ²Associate Professor, Department of Orthodontics and Dentofacial Orthopaedics, ⁶Assistant professor Department of Conservative and Endodontics, Dr. D.Y.PATIL Vidhyapeeth (Deemed University), Dr. D.Y. Patil Dental College Sant tukaram nagar Pimpri -Pune -411018 Maharashtra, ⁵Associate professor, Department of Oral Medicine and Maxillofacial Radiology, College of Dental Sciences Indore, Madhya Pradesh, India

ABSTRACT:

Aim: To assess the maxillary & mandibular implant site with Cone Beam Computed Tomography (CBCT). **Methods:** The study was conducted on CBCT scans of 35 patients age groups was from 20-70 years, CBCT scans of patients was performed on i-CAT Next generation scanner machine. CBCT scans of patients needing replacement of missing teeth using implants. **Results:** 37 implants sites in both maxillary and mandibular anterior region, 10 implants sites in maxillary anterior region, 27 implants sites in mandibular anterior, 44 implants site in both maxillary and mandibular posterior, 18 implants sites in maxillary posterior region and 26 implants sites in mandibular posterior. **Conclusion:** In Males type A bone 29 sites, type B bone 6 sites, type C bone 7 sites and type D bone 2 sites. Females had 28 sites type A bone, 3 sites of type B bone, 5 sites of type C bone, 1 sites of type D bone. 18 maxillary sites, 9 sites are SA-1, 5 sites are SA-3, 2 sites are SA-4, and 2 sites are SA-2. 26 mandibular implant sites had alveolar bone height between crest and inferior alveolar nerve, 15 sites had 12mm of bone, 5 sites had 10-12mm of bone and 6 sites had 5-10mm of bone. Mandibular canal was visible in 17 sites and diffused in 9 sites. 81 sites had 56 sites (69.14%) presence of bony undercut and absent in 30.86% sites.

Key words: Hounsfield units (H.U), Dento-maxillofacial (DMF) imaging, Cone Beam computer tomography (CBCT), Implant site.

Received: 4 February, 2019

Revised: 24 February, 2019

Accepted: 27 February, 2019

Corresponding author: Dr. Chaitra K, Associate professor, Department of Orthodontics and Dentofacial Orthopaedics Dr. D.Y.PATIL vidhyapeeth (Deemed University), Dr. D.Y. Patil Dental College Sant tukaram nagar Pimpri-Pune.-411018 Maharashtra

This article may be cited as: Mastud SP, K Chaitra, Sable DM, Chavan M, Bhateja S, Bhargava K. Guidelines for Safe Placement of Implant site assessing in both the Maxillary and Mandibular Jaw using CBCT- A third eye imaging. J Adv Med Dent Scie Res 2019;7(3):123-131.

INTRODUCTION:

Dental implants boost the self esteem of the patients by replacing lost teeth. The advantage of the implants is that aesthetics is improved with proprioception. Patients with loss of teeth can be the victims of terrible social rejection, which includes loss of self confidence, and self esteem, resulting from the overshadowing aspect of endpoint atrophy of the maxillofacial skeleton.¹

Dental CT has disadvantage of high radiation dose. Osseous anatomy of oro- maxillofacial region can be produced with the Cone beam computed tomography (CBCT) with significantly lower effective radiation dose compared with CT. Introduction of this new technology in the field of dental radiology has made it possible for the

clinician to more accurately evaluate the anatomy of the dental structure.

AIM:

The assessment of the maxillary & mandibular implant site with Cone Beam Computed Tomography (CBCT).

OBJECTIVES-

1. To evaluate available ridge height & width of the implant site.
2. To identify & visualize proximity to maxillary sinus prior to implant placement.
3. To identify & visualize proximity to mandibular canal prior to implant placement.

4. To measure the bone density Hounsfield units (H.U) value at the sites of implant placement.
5. To assess radio graphically the presence or absence of bony undercuts.
6. To assess the ease of identification of mandible canal at the implant site.

MATERIAL AND METHODS:

The patients were randomly selected irrespective of gender, race, religion and socioeconomic status. The study was conducted on CBCT scans of 35 patients age groups was from 20-70 years, CBCT scans of patients was performed on a single machine at i-CAT Next generation Scanner (fig1) , all images were obtained with standard parameters of (120kVp; 5mA, Exposure time 4sec; Voxel spacing 0.4mm) the transmitted x-rays are detected by a sensor and the data is then sent to a computer and reconstructed into 3-d images by software (fig 2). CBCT scans of patients needing replacement of missing teeth using implants, Healing period of at least 3 months after tooth extraction; Good oral hygiene was included in the study

Measurement of the height and width of the available alveolar ridge

The images obtained are measured for height and width of the available alveolar ridge (fig 4) for implant placement.

1. Maxilla

For maxillary anterior region the height of the available ridge was calculated from the crest of ridge to inferior border of nasal fossa.

For maxillary posterior region, the height of the ridge was calculated from the superior border of crest of ridge to the inferior border of maxillary sinus.

2. Mandible

For mandibular anterior region the height of the ridge was calculated from the crest of ridge to inferior border of mandible.

For mandibular posterior region, the height of the ridge was calculated from the crest of ridge to superior border of inferior alveolar canal.

Buccolingual width of the ridge was calculated from the inner buccal and inner lingual cortical plates from the crest of ridge.

Measurements were done on the personal computer with the help of application tools used to measure the height and width.

3. Identification of anatomical structures

Important anatomical structures encountered during the evaluation of the scan i.e orthoradial and panoramic sections were noted both on computer.

These structures included

Maxilla:

- i. Maxillary sinus
- ii. Nasal fossa
- iii. Incisive/ nasopalatine canal

- iv. Pterygoid plates

Mandible:

- i. Inferior alveolar canal
- ii. Mandibular foramen with lingula
- iii. Mental foramen
- iv. Genial tubercles
- v. Groove for lingual artery
- vi. Digastric fossa

4. Proximity of maxillary sinus to implant site was assessed by measurement of available ridge height

5. Proximity of mandibular canal (fig 5) and to implant site was assessed by measurement of available ridge height.

6. Presence of bony undercuts and concavities was assessed by 360⁰ rotation around the implant site using scan.

7. Ease of identification of mandibular canal and nerve at mandibular site

The position of the mandibular canal was found by tracing the assumed path of the mandibular nerve by identifying opening of the mandibular foramen and lingula, on one side and the mental foramen on the other.

8. Measurement of bone density Hounsfield unit (HU) at proposed implant site

A square was formed at a height from the crest touching both the inner buccal and palatal/lingual cortical plates. After the formation of square with the help of software, HU units were observed.

Statistical Analysis: Commercially available statistical software was used to analyze the data. The descriptive analysis was presented as frequency, mean \pm standard deviation (SD), 95% confidence intervals (CI) and range.

RESULTS:

The study was conducted on CBCT scans of 81 implant sites in 35 patients with age groups between 20-70 years, requiring replacement of missing teeth with implant. CBCT scans of patients needing implants have been performed on a single machine at i-CAT Next generation scanner using standard parameters. Measurement was done on the personal computer from the compact disk obtained after the scan (fig 3). The following results were obtained.

Available bone type at implant sites

This study revealed a total of 81 implant sites in 35 patients. Depending upon the available height and width at the proposed implant sites (fig 5), it was divided into four categories

Distribution of the examined sites according to Chanavaz and Donazzan French Volumetric Classification (1986)

Category	Dimension	Other features	Number of sites	Percentage
A	Height:9mm Width:5mm	Abundant bone in all dimensions with intact basal bone.	63	77.78
B	Height:9mm Width: 3mm	Abundant bone except width, intact basal bone.Partially resorbed alveolar bone (After 5-9 year of extraction)	3	3.7
C	Inadequate bone	Totally resorbed alveolar bone. Intact basal bone	8	9.88
D	Severe bone atrophy	Totally resorbed alveolar bone. Partially resorbed basal bone except symphysis region and external oblique ridge	7	8.64

Total number of sites examined

Sites Examined	Number	Percentage
Maxillary anterior sites	10	12.35
Maxillary posterior sites	18	22.22
Mandibular anterior sites	27	33.33
Mandibular posterior sites	26	32.10
Total	81	100

DISCUSSION:

The present study was planned to asses an Imaging Modality in pre-implant placement. 35 patients with completely or partially edentulous 81 sites were selected. Patients wanted to replace their teeth with implant placement. The main aim was to evaluate the efficacy of CBCT as an Imaging Modality in pre- implant placement. Preoperative imaging is highly clinically relevant for 3D imaging for diagnosis and the treatment plan. Preoperative evaluation of bone quality is essential for the clinician to establish a treatment plan for implant restoration. Accurate information on bone density is important to identify suitable implant sites and determine implant design and surgical procedures.

Height and Width available at the implant sites:

Available bone is the amount of bone in the edentulous area considered for osseointegration of the implant. As a general guideline a distance of 1.5 mm is maintained for surgical error between the implant and any adjacent landmark.

Based on Chanavaz French Volumetric bone classification (1986), the available bone height and width was divided into 4 categories i.e category A, B, C and D. Study revealed a total of 81 implant sites out of which 63 sites of type A bone (77.78%); 3 sites of type B bone (3.7%) and 8 sites of type C bone (9.88%); 7sites of type D bone (8.64%) was present in this study.

Table 1 and Graph 1 showed the relationship between the available bone at implant site in anterior and posterior region of the jaws. Maxillary anterior region showed 10 implant sites of type A, while mandibular anterior showed 22 Type A and 4 of Type B bone. Type C bone which included inadequate bone for implant placement was seen in 1 case of mandible anterior implant sites.

In posterior implant sites, Type A bone was present at 9 implant sites in maxillary jaw and 16 implant sites in mandibular jaw. Type B bone was present at 2 implant sites in maxillary jaw and 3 implant sites in mandibular jaw. Type C bone was present at 4 implant sites in maxillary jaw and 7 implant sites in mandibular jaw. Type D bone was seen in only 3 maxillary implant sites.

According to the findings, in our study Table 2 and Graph 2 showed relationship between the gender of the patients and the available bone type at implant sites. Type A bone was seen 29 implant sites in male patients and 28 implant sites were present in female patients. Type B bone was present in 6 males and 3 females. Type C bone in 7 males and 5 in females. Type D bone 2 in males and 1 in females. According to Norbert et al³ females are more prone to osteoporosis due to the decreased estrogen level in female patients and subsequently there is faster resorption of bone. Hence adequate height and width may not be present.

The age associated bone loss is about 1 % in women and 0.5% in males every year. Women represent a greater percentage of patients with residual ridge resorbtion than men.

Implant sites over a wide age group Table 3 and Graph 3 showed relationship between age groups of the patients and type of available bone at implant sites, Maximum implant sites belonged to type A- 70.37% (41-50yrs) Beyond age group of 50 years, 14 implant sites showed type A bone and 6 implants site showed Type C bone reiterating the fact that prolonged loss of teeth without replacement cause disuse atrophy of alveolar bone. Literature states that the decrease in bone height begins in 4th decade and is linear.⁴

From 60-80 yrs there were 10 implant site showing Type A bone as observed in maxillary anterior region. Patient was a denture wearer and hence it can be considered that resorption had been slowed down due to

functional stimulation. Amount of bone loss occurring the 1st year after the tooth loss is 10 times greater than the following years.⁵

According to Table 4 and Graph 4, showed, 9 maxillary posterior implant sites were assessed, 9 sites (50 %) belonged to SA 1, 2 sites (11.11%) belonged to SA 2, 5 sites (27.78 %) implant sites belonged to SA 3, 2sites (11.11%) belonged to SA 4.

Table 5 and Graph 5 showed, A total of 26 Mandible implant site more than 12mm were in 15 sites closed to inferior alveolar nerve and about 10-12mm were in 5 sites, and 5-10mm were in 6 sites.

Table 6 and Graph 6, Visibility of the mandibular canal was assessed on cross sectional images of CBCT out of 26 mandibular posterior implant sites, at the implant site mandibular canal was not visible, but it was visible in subsequent images. In 2 implant sites (7.14%), mandibular canal was diffusely visible. Both sites were in male patients above age group of 40 years. This may be due to fact that with increasing age there is decrease in cortication around the mandibular canal. In 85.71 % canal was distinctly visible on the cross sectional images needs correction.

Bony Concavities:

Presence of bony concavities alters the pathway of implant placement. Its presence warns the surgeon to alter the orientation of implant to avoid cortical plate's perforation and be ready with augmentation procedures. Conventional radiography cannot predict the presence of bony undercuts /concavities.

CBCT detects these concavities clearly and helps the surgeon in planning the treatment. Table 7 and Graph 7 showed that in 56 implant sites (69.14%) concavities were detected. In remaining cases the concavities were absent.

Table 8 and Graph 8 showed that in present study bone densities were divided into 5 categories based on H.U values. 60.49% values were in D3 group, 20.99% in D4 group, 9.88% in D5 and 7.41 % in D2 group, 1.23% in D1 group.

Highest mean H.U value was 1290 HU. Highest mean H.U value in anterior maxilla was 852HU while in anterior mandible it was 1290HU. Similarly highest mean H.U value in posterior maxilla was 543HU and in posterior mandible it was 973HU The H.U value in this study ranged from 54 to 1290. It is possible that higher

H.U values were reported because of slight inclusion of cortical plates.

CBCT provides the clinician with Hounsfield values as an objective method of evaluating bone density for a proposed implant site. Haldun et al advocated use of CT for determining bone quality and quantity.⁶

H. U. Values are little controversial as density in CBCT scans varies as per the scanner, window setting and exposure parameters. The H.U variation observed in the same jaw scan reflect local bone density variations with lower H.U values for poor bone quality.⁷ Variability in values can alert the surgeon to modify the treatment plan so that primary stability in bone of less density is ensured and a longer healing period can then be planned.^{8,9}

FIGURE 1: I-CAT SCAN DEVICE

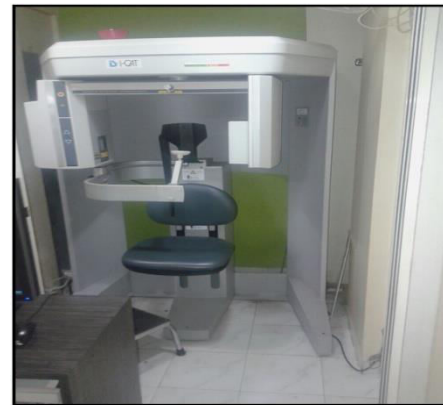

Figure 2: Cone beam computer tomography, a cone-shaped x-ray beam irradiates a patient's jaw. The transmitted x-rays are detected by a sensor. The data is then sent to a computer and reconstructed into 3-d images by software.

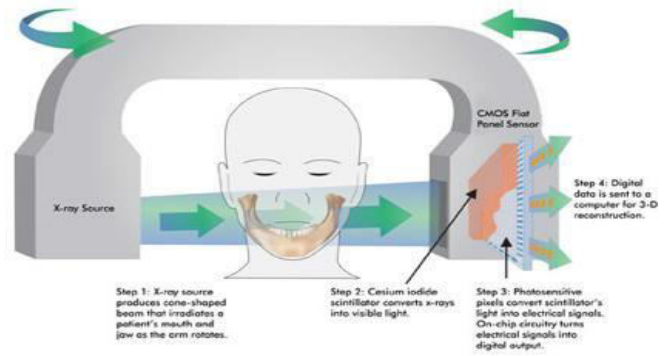


FIGURE 3: IMAGES OF PATIENTS FROM I-CAT SCANNER ON COMPUTER

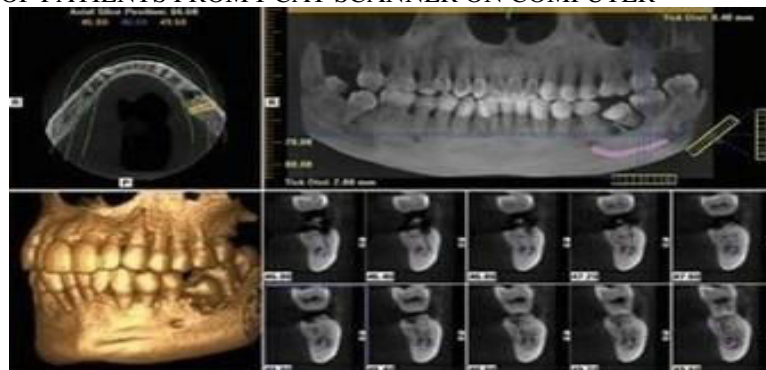


FIGURE 4: MEASUREMENT OF WIDTH, HEIGHT, BONE DENSITY IN HOUNSFIED UNITS

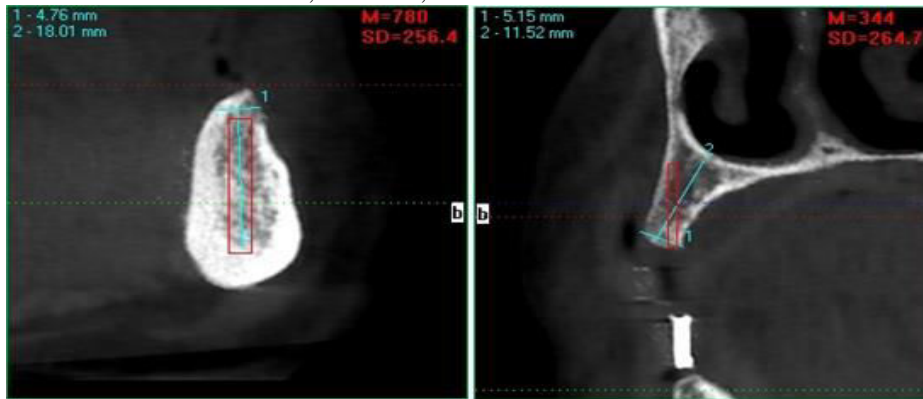


FIGURE 5: VISUALIZATION OF MANDIBULAR CANAL WITH NERVE

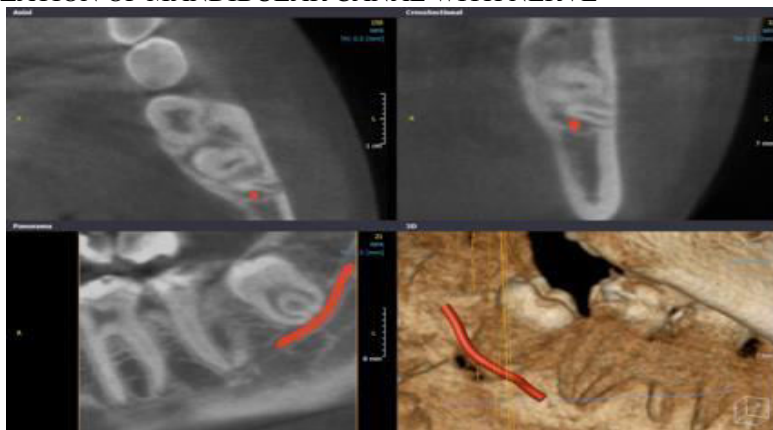


Table 1: Relationship between available bone at implant sites and anterior /posterior region of jaw.

	Anterior				TOTAL	Posterior				TOTAL
	A*	B*	C*	D*		A*	B*	C*	D*	
Maxilla	10	0	0	0	10	9	2	4	3	18
Mandible	22	4	1	0	27	16	3	7	0	26
Total (n=81)	32	4	1	0	37	25	5	11	3	44

A*B*C*D*: Types of available bone based on Chanavaz French Volumetric classification

Graph 1: Relationship between available bone at implant sites and anterior/ posterior region of jaw

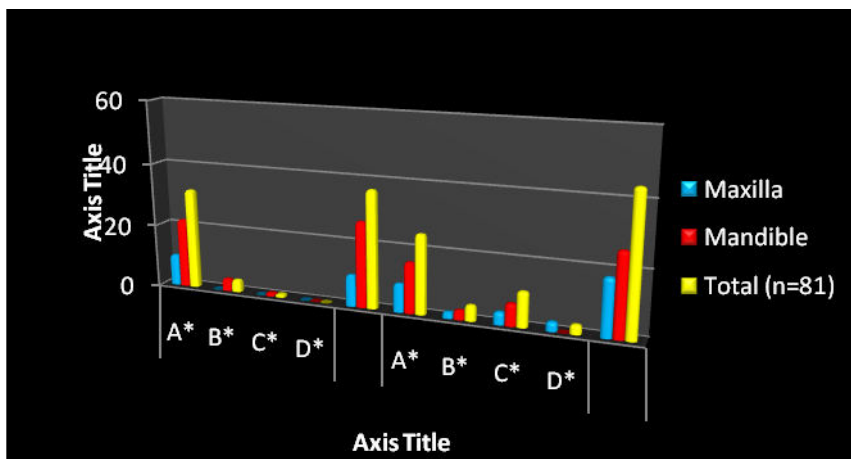


Table 2: Relationship between available bone type at implant sites and Gender of the patient.

Gender of the patient	A*	B*	C*	D*
Male	29	6	7	2
Female	28	3	5	1
Total (n=81)	57	9	12	3

Graph 2: Relationship between available bone type at implant sites and gender of the patient.

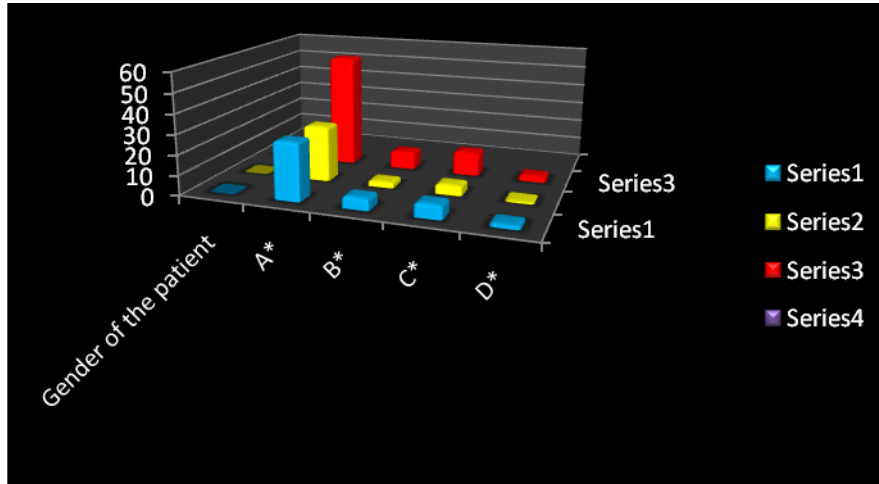


Table 3: Relationship between available bones according to age groups

Age group (years)	A*	B*	C*	D*
10-20 yrs	1	0	1	0
21-30 yrs	11	2	0	1
31-40 yrs	5	1	0	0
41-50 yrs	16	1	2	1
51-60 yrs	14	4	6	0
61-70 yrs	4	1	1	1
71-80 yrs	6	0	2	0
Total(n=81)	57	9	12	3
%	70.37%	11.11%	14.81%	3.70%

Graph 3: Relationship between available bones according to age groups

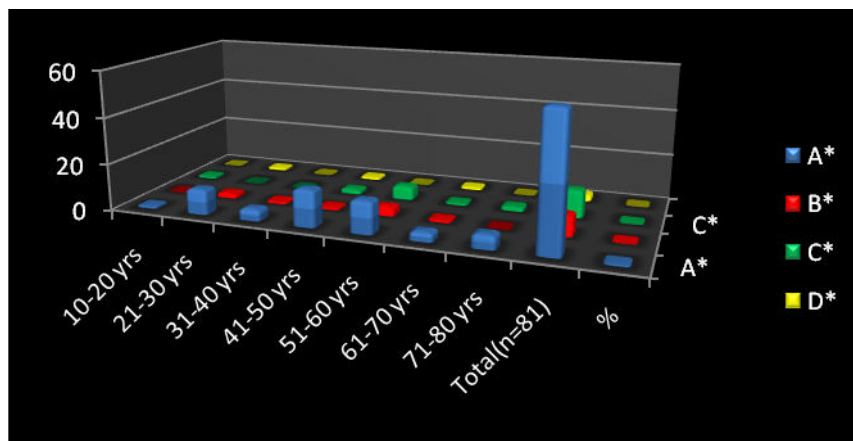


Table 4: Proximity of the maxillary posterior implant sites to the maxillary sinus.
SA^{*} : Subantral treatment option

Groups	Height available at the implant site (mm)	Number of sites	Percentage
SA 1	> 12 mm	9	50%
SA 2	10-12 mm	2	11.11%
SA 3	5 – 10 mm	5	27.78%
SA 4	< 5 mm	2	11.11%
Maxillary posterior sites		18	100

Graph 4: Proximity of the maxillary posterior implant sites to the maxillary sinus.

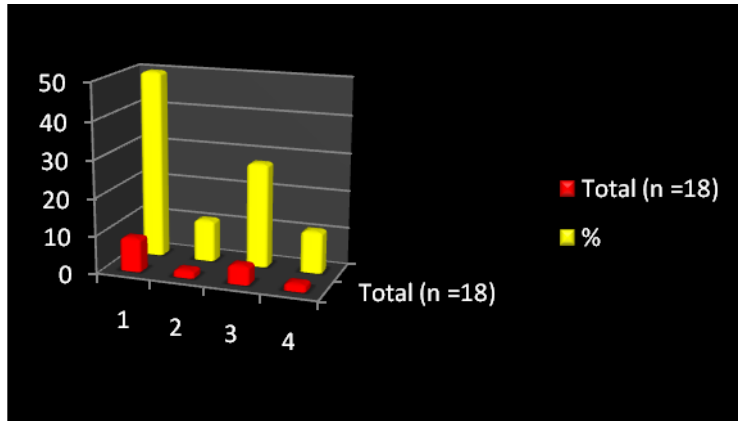


Table 5: Proximity to mandibular posterior implant sites to the inferior alveolar canal

Implant sites	>12 mm	10-12 mm	5-10 mm	< 5mm
Total (n=26)	15	5	6	0
%	57.69	19.23	23.08	0

Graph 5: Proximity to mandibular posterior implant sites to the inferior alveolar canal

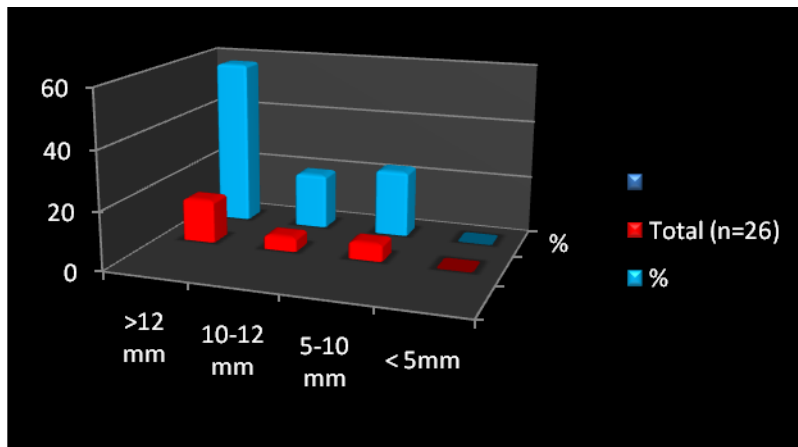


Table 6: Mandibular Canal Visibility

Total number	Visible	Diffused	Non Visible
26	17	9	0

Graph 6: Mandibular Canal Visibility

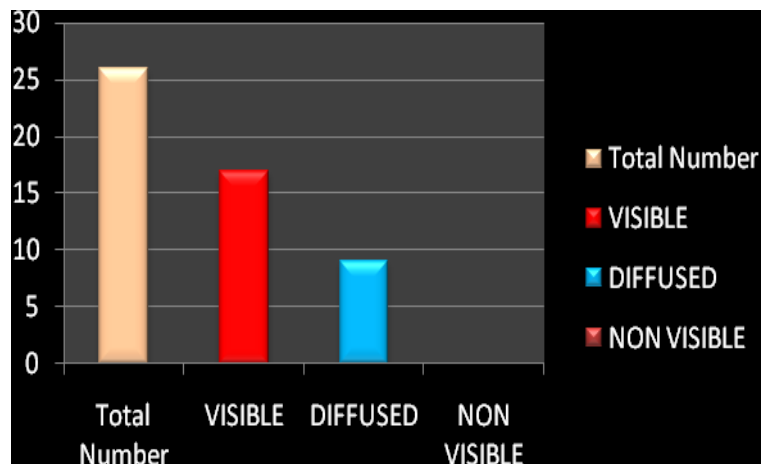


Table 7: Distribution of the examined sites according to Presence of bony concavities at implant sites

Bony Undercuts	Number of sites	Percentage
Absence	25	30.86
Presence	56	69.14

Graph 7: Distribution of the examined sites according to Presence of bony concavities at implant sites

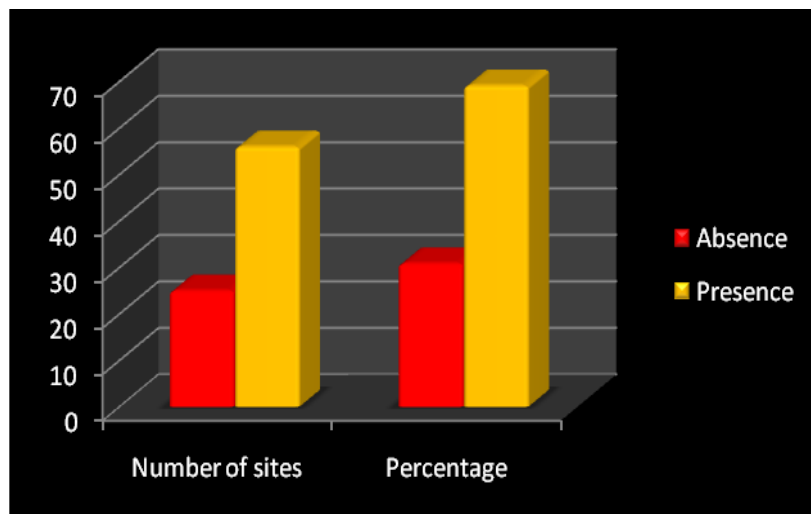
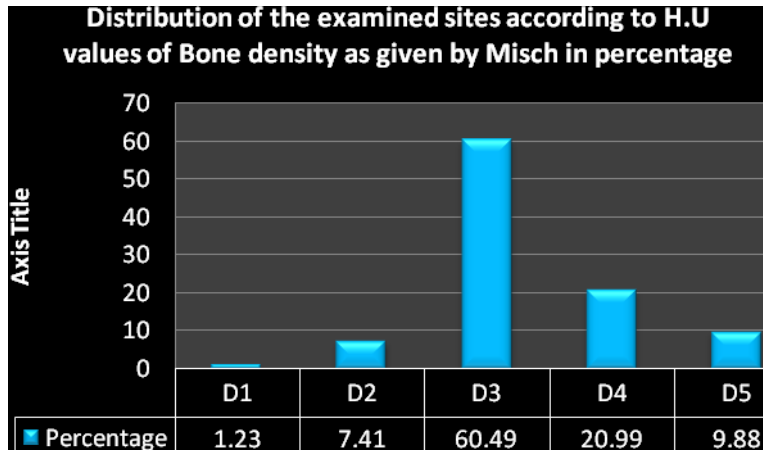


Table 8: Distribution of the examined sites according to H.U values of Bone density as given by Misch- D1* D2* D3* D4* D5*: Bone density

CATEGOR Y	CRITERIA	Number of sites	Percentage
D1	> 1250 HU, dense cortical bone	1	1.23
D2	850-1250 HU, thick dense cortical bone on crest and coarse trabecular bone within	6	7.41
D3	350-850 HU, thin porous cortical bone on crest, and fine trabecular bone within	49	60.49
D4	150-350 HU, fine trabecular bone	17	20.99
D5	< 150 HU, immature non-mineralized bone	8	9.88

Graph 8: Distribution of the examined sites according to H.U values of Bone density as given by Misch- D1* D2* D3* D4* D5*: Bone density



CONCLUSION:

The present study was conducted on CBCT scans 81 sites of 35 patients who requiring replacement of missing teeth with implant and patients were selected randomly irrespective of gender, race, religion and socio-economic status with age group of 20-70 yrs. The following conclusions obtained were as follows:

- 37 implants sites were present in both maxillary and mandibular anterior region, out of which 10 implants sites were present in maxillary anterior region, 27 implants sites were presents mandibular anterior.44 implants site were present in both maxillary and mandibular posterior, out of which 18 implants sites were in maxillary posterior region and 26 implants sites were present in mandibular posterior.
- 44 Males sites and 37 Females sites, In Males type A bone is 29 sites, type B bone in 6 sites, type C bone in 7 sites and type D bone in 2 sites. Females had 28 sites type A bone, 3 sites of type B bone, 5 sites of type C bone, 1 sites of type D bone
- Type A bone was 70.37% and was highest at age group between 41-50yrs followed by Type C bone was 14.81% and was highest at 51-60 yrs, followed by Type B bone of 11.11% and was highest at 51-60 yrs, and Type D bone was 3.70%.
- Among 18 maxillary sites, 9 sites are SA-1, 5 sites are SA-3, 2 sites are SA-4, and 2 sites are SA-2.
- Of the total 26 mandibular implant sites studied to evaluate bone height between crest and inferior alveolar nerve, 15 sites had 12mm of bone, 5 sites had 10-12mm of bone and 6 sites had 5-10mm of bone.
- A total of 26 mandibular sites the mandibular canal was visible in 17 sites and diffused in 9 sites.
- A total of 81 sites had 56 sites (69.14%) presence of bony undercut and was absent in 30.86% in sites.
- A total of 49 sites had D3 type of bone (60.49%) followed by D4 type in 17 sites (20.99%), 8 sites had

D5 bone (9.88%), 6 sites had D2 bone (7.41%) and only 1 site had D1 bone (1.23%) dense cortical bone. A larger study has to be conducted to evaluate the efficiency of CBCT as aid in treatment planning of implant cases.

REFERENCES:

1. Prashant P Jaju: Cone beam computed Tomography-A clinician guide to 3D imaging, Jaypee publisher, chapter 5; page 34.
2. Tetradis S Anstey P, Graff-Radford S cone beam computed tomography in the diagnosis of dental disease. J Calif Dent Assoc 2010; 38 (1): 27-32.
3. Atwood DA: Some clinical factors related to the rate of resorption of residual ridge. J Prosth Dent, 1962; 12: 441-450.
4. Norbert B: Imaging in oral implantology and restorative dentistry. Gerard MS,Carl EM, Klaus UB (Eds). Martin Dunitz Ltd, pages: 178-196, 2001.
5. Tallgren A: The continuing reduction of the residual alveolar ridges in complete denture wearers- A mixed longitudinal study covering 25 years. J Prosth Dent 1972; 27:120-132.
6. Haldun I, Kivanc A,Murat C: The use of computerized tomography for diagnosis and treatment planning in implant dentistry. J Oral Implant 2002; 28:29-36.
7. Reinhilde J: Preoperative radiologic planning of implant surgery in compromised patients. Periodontology 2000, 2003; 33:12-25.
8. Tannaz S ,Petros DD,Gary MR,Terrence JG,William MR: Quantitative evaluation of bone density using the Hounsfield index. Int J Oral Maxillofac Implants.2006; 21:290-297.
9. Turkyilmaz TF, Tozum C, Tumer: Bone density assessments of oral implant sites using computerized tomography. Journal of Oral Rehabilitation, 2007 34; 267-272.

Source of support: Nil **Conflict of interest:** None declared
 This work is licensed under CC BY: **Creative Commons Attribution 3.0 License.**