

## Original Article

### Evaluation of results of non-united humerus shaft fractures treated with external fixator augmented by intramedullary rod and autogenous iliac crest bone graft

Basant Rai<sup>1</sup>, Jaspal Singh<sup>2</sup>, Bharat Singla<sup>3</sup>, Dinesh Kumar<sup>3</sup>, H.S. Sohal<sup>4</sup>

<sup>1</sup>Assistant Professor, <sup>2</sup>Associate Professor, <sup>3</sup>Junior Resident, <sup>4</sup>Professor & Head, Department of Orthopaedics, Govt. Medical College, Amritsar

#### ABSTRACT:

**Background:** Humeral shaft fractures account for approximately 3 percent of all fractures and results in a significant burden to society from lost productivity and income. Management of humeral shaft fractures has historically been largely conservative. These days humeral shaft fractures are usually treated either by plating or by intramedullary nailing which sometimes results in non Union of these fractures. We planned the present study to evaluate the results of non-united humerus shaft fractures treated with external fixator augmented by intramedullary rod and autogenous iliac crest bone graft(ICBG) . **Materials & methods:** The present study included assessment of results of non-united humerus shaft fractures treated with external fixator augmented by intramedullary rod and autogenous iliac crest bone graft. A total of 20 patients were included in the present prospective study. All the patients underwent operative procedures for the treatment. The patients were allowed to use his/her arm and to do active exercises of all joints. Follow-up X-rays were obtained after very three weeks and then every month until radiographic bone healing and graft incorporation occurred. External fixator was removed after radiological healing of the fracture. All the results were evaluated by ULCA score. All the results were analyzed by SPSS software. **Results:** A total of 20 patients were included in the present study. The mean age of the patients was 40.15 years. Closed primary fracture occurred in 75% of the cases. Complications occurred in 40 percent of the cases. Satisfactory results were obtained in 85 percent of the patients at the time of final follow-up. **Conclusion:** The use of external fixation augmented by IM rods together with routine use of ICBG is viable option to treat humeral shaft non-union following failed implant surgery.

**Key words:** External Fixator, Humerus, Intramedullary, Shaft

Received: 20 November 2017

Revised: 30 December 2017

Accepted: 2 January 2018

**Corresponding Author:** Corresponding author: Dr. Jaspal Singh, Associate Professor, Department of Orthopaedic, Govt. Medical College, Amritsar, Email ID: drjaspalsingh87@gmail.com

**This article may be cited as:** Rai B, Singh J, Singla B, Kumar D, Sohal HS. Evaluation of results of non-united humerus shaft fractures treated with external fixator augmented by intramedullary rod and autogenous iliac crest bone graft. J Adv Med Dent Sci Res 2018;6(2):5-8.

## INTRODUCTION

Humeral shaft fractures account for approximately 3 percent of all fractures and results in a significant burden to society from lost productivity and income.<sup>1</sup> These are mostly caused by high energy trauma such as road traffic accidents, fall from a height or assault. Management of humeral shaft fractures has historically been largely conservative. A significant body of literature has shown that even functional bracing may achieve greater than 90 percent union rates and acceptable functional

outcomes. Reamed locked intramedullary nailing or plating with bone grafting is the preferred treatment for most diaphyseal non-unions for several reasons.<sup>2-4</sup> bone grafts alone provide no stability to the fracture site. Unless the non-union is inherently stable, you may also need more surgical procedures to improve stability.<sup>5, 6</sup> Hence; we planned the present study to evaluate the results of non-united humerus shaft fractures treated with external fixator augmented by intramedullary rod and autogenous iliac crest bone graft.

**MATERIALS & METHODS**

The present study was conducted in the department of orthopaedics of Govt. Medical College, Amritsar and included assessment of results of non-united humerus shaft fractures treated with external fixator augmented by intramedullary rod and autogenous iliac crest bone graft. Ethical approval was taken from institutional ethical committee and written consent was obtained from all the patients after explaining in detail the entire research protocol. A total of 20 patients were included in the present prospective study. Inclusion criteria for the present study included:

- Patients more than 18 years of age,
- Both sexes
- History of fracture of more than 6 months duration

Exclusion criteria for the present study included:

- Patients of less than 18 years of age,
- Patients with history of fracture of less than 6 months of duration,
- Patients with multiple co-morbidities,
- Fracture due to pre-existing pathologies

Complete clinical and radiological examination was done in all the patients. The patients were then assessed medically. For clinical evaluation- preoperative and postoperatively UCLA score was used which allocates points for pain, function, movement, muscle power and patient satisfaction and has maximum score of 35 points. All the patients underwent operative procedures for the treatment. The patients were allowed to use his/her arm and to do active exercises of all joints. Follow-up X-rays were obtained after very three weeks and then every month until radiographic bone healing and graft incorporation occurred. External fixator was removed after radiological healing of the fracture. All the results were evaluated by ULCA score. All the results were analyzed by SPSS software.

**RESULTS**

A total of 20 patients were included in the present study. The mean age of the patients was 40.15 years with 55 percent of the patients less than 40 years of age. Out of 20, 14 patients were males while remaining were females. In our study, we had more of right sided cases than left sided ones. The maximum patients had non-union since 16 to 20 months followed by those with 10 to 15 months of non-union and more than 20 months of non-union. Road traffic accident was the mode of injury in 75 percent of the cases. Closed primary fracture occurred in 75% of the cases. Complications occurred in 40 percent of the cases with pin-track infection being the most common complication encountered in 20 percent of the patients. Satisfactory

results were obtained in 85 percent of the patients at the time of final follow-up.

Table 1: Distribution of subjects according to age

Age group (years)	No. of patients	Percentage
20- 30	7	35
31- 40	4	20
41- 50	3	15
51 and above	6	30
Mean age	40.15	

Table 2: Type of intramedullary rod used

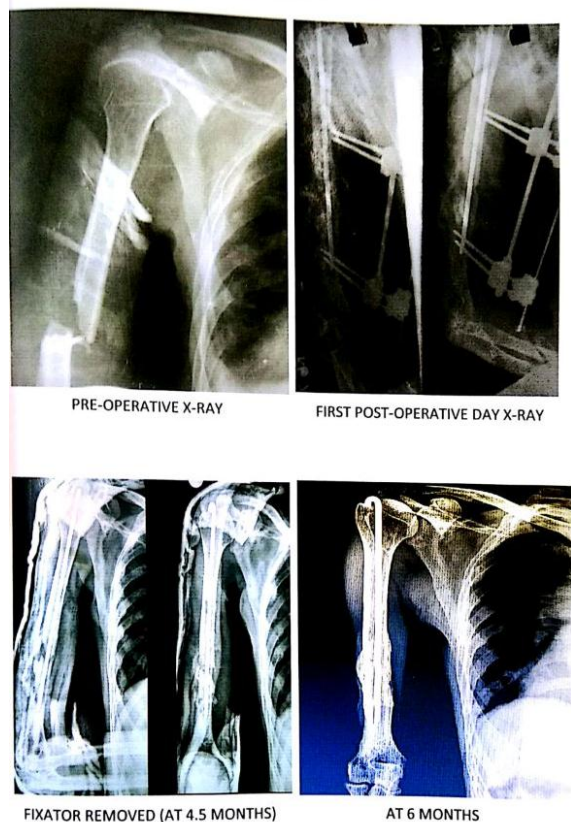
Intramedullary rod type	No. of patients	Percentage
k-Nail	8	40
Rush rod	10	50
Interlocking nail	2	10

Table 3: Complication

Complications	No. of patients	Percentage
Pin-track infection	4	20
Deep infection	0	0
Angulation	1	5
Shortening	3	15
Neurovascular injury	0	0

Table 4: Results at final follow-up as per UCLA scoring

Results	No. of patients	Percentage
Satisfactory	17	85
Unsatisfactory	3	15



## DISCUSSION

Although the great majority of fractures of the mid-third of the humeral shaft heal uneventually when treated nonoperatively, nonunion is not an infrequent condition. The prevalence of nonunion as a complication of both nonoperative and operative treatment has been reported to be as high as 13%. Although plate fixation remains one of the most valid techniques for the treatment of these nonunion cases, poor bone quality or a deficient plate technique may lead to nonunion.<sup>7-9</sup> Delayed union or nonunion of fracture of the humerus is a debilitating complication, but open reduction and internal fixation combined with autologous bone grafting can result in reliable healing of these nonunion cases; however, there is morbidity associated with the bone graft donor site.<sup>10</sup> Hence; we planned the present study to evaluate the results of non-united humerus shaft fractures treated with external fixator augmented by intramedullary rod and autogenous iliac crest bone graft.

In the present study, we included a total of 20 patients; out of which majority were males. Mean age of the patients was 40.15 years. In our study, as per ULCA score, the functional outcome was satisfactory in 85 percent of the cases. In three cases, the functional outcome was unsatisfactory. El-Rosasy MA evaluated the results of using external fixator

augmented by intramedullary rod and autogenous iliac crest bone grafting (ICBG) for the treatment of humerus shaft nonunion following previously failed surgical treatment. Eighteen patients with atrophic nonunion of the humeral shaft following previous implant surgery with no active infection were included in the present study. The procedure included exploration of the nonunion, insertion of intramedullary rod (IM rod), autogenous ICBG and application of external fixator for compression. Ilizarov fixator was used in eight cases and monolateral fixator in ten cases. The monolateral fixator was preferred for females and obese patients to avoid abutment against the breast or chest wall following the use of Ilizarov fixator. The fixator was removed after clinical and radiological healing of the nonunion, but the IM rod was left indefinitely. The evaluation of results included both bone results and functional outcome using the University of California, Los Angeles (UCLA) rating scale. The mean follow-up was 35 months. Bone union was obtained in all cases. The functional outcome was satisfactory in 15 cases and unsatisfactory in 3 cases due to joint stiffness. The time to bone healing averaged 4.2 months. The external fixator time averaged 4.5 months. Superficial pin tract infection occurred in 39% of the pins. No cases of nerve palsy, refracture, or deep infection were encountered. The proposed technique is effective in treating humeral nonunion especially in the presence of osteoporosis and short bone segments.<sup>11</sup>

Al-Sayyad MJ treated 30 consecutive nonunion cases of the midpart of the humeral shaft with open reduction and internal fixation by a single surgeon. The series included 14 female patients and 16 male patients with an average age of 42 years (range 19-57 years). The patients were followed up for an average of 28 months (range 24-56 months). The time from diagnosis of nonunion to their treatment of the nonunion was 9 months. According to the Stewart and Hundley Criteria, the functional postoperative result was excellent or good in 24 (73%) cases and fair in six (27%) cases. One year after surgery, all patients had an essentially normal range of motion of the ipsilateral elbow and shoulder. According to the scoring system of Constant and Murley the postoperative average score was 90. Surgical compression plating and autologous bone grafting of humeral diaphyseal nonunions resulted in 100% union rate and mostly excellent or good functional results without significant morbidity.<sup>12</sup>

## CONCLUSION

Under the light of above results, the authors conclude that the use of external fixation augmented by IM rods together with routine use of ICBG is viable option to treat humeral shaft non-union following failed implant surgery. However; we recommend future studies for better exploration of this field of orthopaedic sciences.

## REFERENCES

1. Catagni MA, Guerreschi F, Probe RA. Treatment of humeral nonunions with the Ilizarov technique. Bull Hosp Jt Dis Orthop Inst. 1991;51:74–83.
2. Livani B, Belangero W, Medina G, Pimenta C, Zogaib R, Mongon M. Anterior plating as a surgical alternative in the treatment of humeral shaft non-union. Int Orthop. 2010;34:1025–31
3. Pugh DM, McKee MD. Advances in the management of humeral nonunion. J Am Acad Orthop Surg. 2003; 11: 48–59.
4. Su JC, Liu XW, Yu BQ, Li ZD, Li M, Zhang CC. Shape memory Ni-Ti alloy swan-like bone connector for treatment of humeral shaft nonunion. Int Orthop. 2010;34:369–75.
5. Marti RK, Verheyen CC, Besselaar PP. Humeral shaft nonunion: Evaluation of uniform surgical repair in fifty-one patients. J Orthop Trauma. 2002;16:108–15.
6. Patel VR, Menon DK, Pool RD, Simonis RB. Nonunion of the humerus after failure of surgical treatment. Management using the Ilizarov circular fixator. J Bone Joint Surg Br. 2000;82:977–83.
7. De Bastiani G, Aldegheri R, Renzi Brivio L. The treatment of fractures with a dynamic axial fixator. J Bone Joint Surg Br. 1984;66:538–45.
8. Lavini F, Renzi Brivio L, Pizzoli A, Giotakis N, Bartolozzi P. Treatment of non-union of the humerus using the Orthofix external fixator. Injury. 2001;32(Suppl 4):SD35–40.
9. Marsh JL, Mahoney CR, Steinbronn D. External fixation of open humerus fractures. Iowa Orthop J. 1999;19:35–42.
10. Clement H, Pichler W, Tesch NP, Heidari N, Grechenig W. Anatomical basis of the risk of radial nerve injury related to the technique of external fixation applied to the distal humerus. Surg Radiol Anat. 2010;32:221–4.
11. El-Rosasy MA. Nonunited humerus shaft fractures treated by external fixator augmented by intramedullary rod. Indian J Orthop. 2012 Jan;46(1):58-64.
12. Al-Sayyad MJ. Functional outcome after surgical plating for humeral shaft nonunion. Egypt Orthop J 2014;49:267-72.

**Source of support:** Nil

**Conflict of interest:** None declared

This work is licensed under CC BY: *Creative Commons Attribution 3.0 License.*