

Original Article

A Comparative Evaluation of Height of Interdental Papilla around Noris Tuff TT and Nobel Active Dental Implants placed in Maxillary Anterior Region

Nitin Ahuja¹, Ritika Arora², Vaibhav Kumar³, Johnson Raja James⁴

¹MDS - Oral and Maxillofacial Surgery, Private practitioner and Implantologist, Dentistry Dental Clinic, Oberoi splendour D-205, Andheri East, JVL R, Mumbai - 400060

²Professor and Head, Department of Periodontics, Vadik Dental College and Research Centre, Daman,

³Lecturer, Department of Public Health Dentistry, Terna Dental College, Navi Mumbai.

⁴MDS Periodontology, Professor & Vice Principal, Rajas Dental College & Hospital, 4/ 148, Shanthi Nagar, Palayamkottai, Tirunelveli - 627002

ABSTRACT:

Background: Interdental papilla height is important as esthetic factor for dental implant success. The present study was conducted to compare the amount of soft tissues around Noris Tuff TT and Nobel Active dental implant systems. **Materials & Methods:** The present study was conducted on 28 patients (males- 13, females- 15) who received 32 dental implants in maxillary anterior region. Group I patients received Nobel Active dental implants and Group II patients received Noris Tuff TT dental implants. In all patients, interdental papilla was evaluated using JEMT index. The amount of bone loss in both groups was evaluated using paired and unpaired t-test. **Results:** The amount of bone loss around dental implants in both groups did not show significant difference ($P > 0.05$). There was non-significant correlation between bone loss and papilla index in both groups ($P > 0.05$). **Conclusion:** The amount of interdental bone loss and papilla profile in the maxillary anterior region around Noris Tuff TT when compared to that around Nobel Active dental implants was non-significant. **Clinical significance:** The preservation of interdental papilla is of paramount importance for the successful dental implant therapy.

Key words: Bone loss, Noris Tuff TT implants, Nobel Active implants, Interdental papilla, JEMT index.

Received: 12 September 2018

Revised: 23 October 2018

Accepted: 25 October 2018

Corresponding author: Dr Nitin Ahuja, MDS - Oral and Maxillofacial Surgery, Private practitioner and Implantologist, Dentistry Dental Clinic, Oberoi splendour D-205, Andheri East, JVL R, Mumbai - 400060

This article may be cited as: Ahuja N, Arora R, Kumar V, James JR. A Comparative Evaluation of Height of Interdental Papilla around Noris Tuff TT and Nobel Active Dental Implants placed in Maxillary Anterior Region. J Adv Med Dent Scie Res 2018;6(11):5-9.

INTRODUCTION

Maxillary anterior region is common site for tooth loss. The causes may be trauma, cysts or tumors etc. The prime most reason to replace missing anterior teeth is esthetics and functions. Dental implants are considered options for replacing single tooth. This treatment modality has advantages over Fixed Partial Denture (FPD) or Removable Partial Denture (RPD). There is no need to prepare adjacent teeth as in cases of FPD. The clasps of RPD may lead to trauma to tooth as well as to soft tissues. Thus dental implants are useful in restoring function and esthetics.¹

Studies have revealed high success rate of 95% over 10 years for dental implants. The process of osseointegration promotes union of dental implant with bone, ensuring better attachment and success rate. Apart from it, the soft tissues around dental implant play an important role in long term survival. Interdental papilla and labial gingiva add beauty to dental implants.^{2,3}

Factors such as periodontitis, over contoured restoration, flossing technique, improper alignment prosthetic part of dental implant and abnormal tooth morphology may affect interdental papilla. The level of bone around dental implant and adjacent teeth determines the future outcome

of treatment. Therefore, the height of interdental papilla may be regarded as deciding parameter for successful implant therapy. Literature has shown that there is variation in height of interdental papilla on distal and mesial side of dental implant.⁴ The present study was conducted to compare the amount of soft tissues around Nobel Active and Noris TuffTT dental implant system.

MATERIALS & METHODS

The present three years retrospective study was conducted in a Mumbai, India (*Aesthetic Smiles Dental Clinic*). EC approval was obtained from an Independent Review Board. A non-probability convenience sample comprising of 28 patients (Males- 13, Females- 15) who received 32 dental implants in the maxillary anterior region was fixed as the study sample. Inclusion criteria were patients with dental implant in maxillary anterior region in last three years, no systemic diseases, non- smokers, pocket depth <3mm and no bone loss. Patients with poor quality radiographs, uncooperative, pregnant women, patients with systemic diseases and on steroid therapy or those unwilling to give written informed consent were excluded from the study.

All the subjects recruited for the study were informed regarding the same and written consent was obtained. The patients were divided into 2 groups. Group I patients comprised of those who received Nobel Active dental implants (Nobel Biocare) and Group II patients received Noris TuffTT dental implants (Noris Medical Pvt. Ltd.). The reason why these two implant systems were chosen in the purview of the study, among the pool of various other systems available can be attributed to the fact that these two systems have similar external geometry of thread design.

All the dental implant were inserted by same clinical team comprising of a faciomaxillary surgeon (NA) and periodontist (RA) following standardized operating surgical protocols. The prosthetic part was prepared by the same technician (*R.R. Dental Lab*). Following the dental implant insertion, Intraoral Periapical Radiographs (IOPAR) were taken with the same calibrated machine following the paralleling technique using size 2 x- ray films. The patients were recalled periodically in accordance to the Merin's classification of patient scheduling and radiographs of the same site were obtained after 2 years.

Upper edge of the implant shoulder in initial radiograph and the distance between abutment and implant was regarded as reference line. In initial radiographs, the distance from the contact point of the implant and bone to the reference line and the distance from the CEJ of the adjacent tooth to the contact point of the crestal bone and tooth were measured. In follow up radiographs, the distance from the contact point of the crestal bone and implant to the reference line and the distance from the CEJ

of the adjacent tooth to the contact point of the crestal bone and tooth were measured. The distance from the contact point of the implant restoration and the adjacent tooth to the crestal bone was also calculated.

JEMT index (*Figure 1*) was used to measure presence of interdental papilla between implant and adjacent teeth in follow up period (after 2 years). All the measurements were performed by two independent clinicians following astute training of the examiners (RA and VK). Cohen's Kappa (unweighted) statistic yielded a strong level of agreement (0.90) between the two examiners. The mean of their values was considered to further overcome interobserver bias. A digital Vernier caliper was used for measurements in mm.

Papilla index (PI) grading was used. Score 0 depicted no papilla in the interproximal space, score 1 was presence of less than 50% of the papilla height, score 2 had presence of at least 50% of the papilla height but not all the interproximal space, score 3 showed the papilla completely fills the interproximal space and is coordinated by the adjacent papilla with a favorable gingival contour and score 4 had the hyperplastic papillae that covers too much of the single implant restoration and/or the adjacent tooth, with unfavorable gingival contour was used.

The data was compiled in Microsoft Excel spreadsheet and subjected to necessary statistical analysis. The normality of the data was assessed using Shapiro-Wilk test and the data was found amenable to parametric inferential statistics. Intergroup comparisons were analyzed using the paired t-test and the intragroup comparisons were judged using the Student's t-test. The level of significance (α) was set a-priori, at 5% ($p < 0.05$) with the power of the study ($1 - \beta$) at 80%.

RESULTS

The results are elaborated in Table I and III. Group I, mean distances from the implant shoulder to the crestal bone on mesial side was 1.22 mm initially and 1.8 mm after 2 years. On distal side, it was 0.82 initially and 2.3 mm after 2 years. In group II, mean distances from the implant shoulder to the crestal bone on mesial side was 1.8 mm initially and 3.1 mm after 2 years. On distal side, it was 1.6 mm initially and 2.2 mm after 2 years. The difference was significantly ($P < 0.05$) on distal side in group I. The mean distance between the CEJ of the adjacent tooth and the crestal bone in group I initially on mesial side was 2 mm and 2.6 mm after 2 years, on distal side it was 2.2 mm initially and 2.4 mm after 2 years. In group II, it was 2.1 mm initially and 2.5 mm after 2 years on mesial side. It was 2.5 mm initially and 2.7 mm after 2 years on distal side. The difference was non- significant ($P > 0.05$) (Graph I). Mean bone loss adjacent to implant shoulder in group I was 1.34 mm and 0.72 mm in group II. The difference was non- significant ($P > 0.05$).

Figure 1:

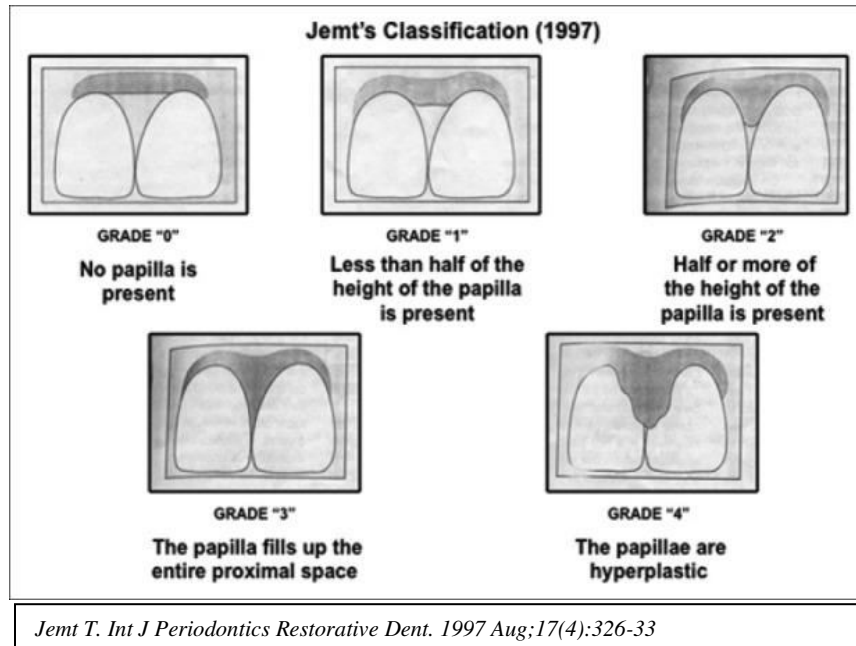


Table I : Intragroup comparison of mean distances (mm) from the implant shoulder to the crestal bone

Group I (Nobel Active)	Mesial	1.22	1.8	0.5
	Distal	0.82	2.3	0.01*
Group II(Noris Tuff)	Mesial	1.8	3.1	0.08
	Distal	1.6	2.2	0.1

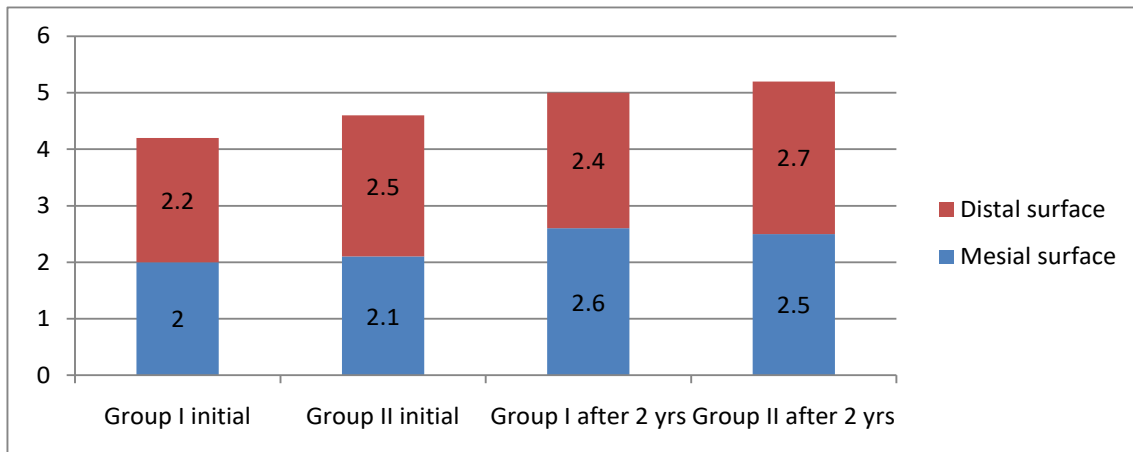
Paired t-test. * Indicates Statistical Significance. (p > 0.05)

Table II : Intergroup comparison of mean distances (mm) from the implant shoulder to the crestal bone

	Interdental papilla height (mm)	Group I (Nobel Active)	Group II (Noris Tuff)	P value
Initial IOPAR	Mesial	1.22	1.8	0.2
	Distal	0.82	1.6	0.3
2 Years	Mesial	1.8	3.1	0.5
	Distal	2.3	2.2	0.07

Unpaired Student t-test.

Graph I Comparison of the mean distance between the CEJ of the adjacent tooth and the crestal bone



DISCUSSION

Teeth are lost due to various reasons such as a result of trauma, dental caries, and periodontitis or due to orthodontic reasons. Dental implant therapy is widely used nowadays. The higher survival rate is one of the reasons for its popularity. The successful implant therapy is based on its ability to restore esthetics as well as functions.⁵ It should mimic the natural teeth and perform all required functions such as eating, biting, chewing etc. Maxillary anterior tooth region is favorable site for dental implant. The presence of sufficient bone height in this region favours dental implant therapy. Moreover, maxillary anterior region shows type I bone which is suitable for dental implants. Dental implants in maxillary anterior region are less subjected to occlusal forces. The height of interdental papilla also determines the dental implant success rate.⁶ Many studies have been conducted which evaluate factors affecting bone loss around dental implants. Very few studies have been performed so far which shows importance of dental papilla as key factor in deciding outcome of dental implants.^{7,8} Considering this, the present study was conducted to compare the amount of soft tissues around Nobel Active and Noris Tuff TT dental implant systems.

Chang M *et al*⁹ in their study revealed that interdental papilla formation is greatly depends on distance between dental implant and natural teeth and anatomy of adjacent teeth. Grunder U¹⁰ suggested that bone level around dental implant determines the presence of interdental papilla between implant and natural teeth.

In present study we included 28 patients of both genders having 32 dental implants. All were the cases of maxillary anterior region. We used Nobel Active dental implants in group I and Noris Tuff TT dental implants in group II. We observed that the mean distances from the implant shoulder to the crestal bone was 1.22 mm initially which become 1.8 mm after 2 years in group I on mesial side. It was 0.82 initially and 2.3 mm after 2 years on distal side. Similarly, the mean distance from the implant shoulder to the crestal bone was 1.8 mm initially and 3.1 mm after 2 years on mesial side and 1.6 mm initially and 2.2 mm after 2 years on distal side. Our results are in accordance to the study of Henriksson K *et al*.¹¹ In their study, the height of interdental papilla around dental implants was compared.

In present study, there was no significant bone loss in either of dental implant systems. Our results are in tandem with the study by Bratuet *al*¹² who performed a prospective study to evaluate the level of bone loss around micro- threaded dental implants and found that there was significantly less bone loss in dental implants having micro- threads. Studies have demonstrated that micro- threaded dental implants tend to deliver stress at crestal bone. It was found that rough dental implants with micro- threads are helpful in maintaining crestal bone level as compared to non- threaded dental implants.^{13,14}

We observed that on mesial side the mean distance between the CEJ of the adjacent tooth and the crestal bone was 2 mm initially and 2.6 mm after 2 years whereas on distal side it was 2.2 mm initially and 2.4 mm after 2 years in group I. In group II, it was 2.1 mm initially and 2.5 mm after 2 years on mesial side. It was 2.5 mm initially and 2.7 mm after 2 years on distal side. However, the difference in both groups found to be non- significant. Kan JY *et al*¹⁵ in their study on 6 dental implant system found that interdental papilla are greatly affected by the around of crestal bone level in adjacent teeth.

Choquet *et al*¹⁶ in their study assessed the level of interdental papilla around single maxillary anterior dental implant both clinically as well as radiographically. Authors found that in cases where there was >6mm distance between alveolar crest and contact point, the interdental papilla was seen in all cases whereas when it was <5mm, only half of cases showed interdental papilla.

Ozdemir *et al*¹⁷ in their study included 33 immediate dental implants and adjacent implants. The level of interdental papilla height was measured using Pink esthetic score at 1 week, 1 month and 4 months. Authors concluded that immediate dental implants and loading are effective in maintaining soft tissue health such as interdental papilla. Similarly, the study by Mankoo *et al*¹⁸ in their 2-7 years follow up study on 10 dental implants placed in esthetic zone suggested the role of labial tissue thickness and tissue biotype in dental implant therapy in maxillary anterior region.

The limitation of the study was small sample size. Only Noble Active and Noris Tuff TT types of dental implants were included. Further studies are warranted to elucidate fortified results in different study settings and populations. Keeping the congruency of the gingival biotype and studies depicting survival analysis data could prove to be a cornerstone in research within this paradigm and vista.

CONCLUSION

Authors found relation between presence of papilla and the distance of the contact point of the implant restoration and the adjacent tooth to the crestal bone. The amount of bone loss in both groups was not significant.

CLINICAL SIGNIFICANCE

The preservation of interdental papilla is of paramount importance for predictable results and successful dental implant therapy.

REFERENCES

1. Grey E B, Harcourt D, O'Sullivan D, Buchanan H, Kilpatrick N M. A qualitative study of patients' motivations and expectations for dental implants. *Br Dent J* 2013; 214: 1.
2. Fardal, Grytten J. A comparison of teeth and implants during maintenance therapy in terms of the number of disease-free years and costs-an in vivo internal control study. *J Clin Periodontol* 2013; 40: 645-651.

3. Clementini M, Rossetti P H, Penarrocha D, Micarelli C, Bonachela W C, Canullo L. Systemic risk factors for peri-implant bone loss: a systematic review and meta-analysis. *Int J Oral Maxillofac Surg* 2014; 43:323–334.
4. Gatti C, Gatti F, Chiapasco M, Esposito M. Outcome of dental implants in partially edentulous patients with and without a history of periodontitis: a 5-year interim analysis of a cohort study. *Eur J Oral Implantol* 2008;1(1):45-51.
5. Turkylmaz I, McGlumphy EA. Influence of bone density on implant stability parameters and implant success: a retrospective clinical study. *BMC Oral Health* 2008;8:32.
6. Chow YC, Wang HL. Factors and techniques influencing peri-implant papillae. *Implant Dentistry*. 2010; 19: 208–219.
7. Bruno V, Badino M, Sacco R, Catapano S. The use of a prosthetic template to maintain the papilla in the esthetic zone for immediate implant placement by means of a radiographic procedure. *Journal of Prosthetic Dent*. 2012; 108: 394-397.
8. Salama H, Salama M, Garber D, Adar P. Developing optimal peri-implant papillae within the esthetic zone: guided soft tissue augmentation. *J Esthet Dent* 1995;7(3):125-9.
9. Chang M, Wennstrom JL, Odman P, Andersson B. Implant supported single-tooth replacements compared to contralateral natural teeth. Crown and soft tissue dimensions. *Clin Oral Implants Res*. 1999;10(3):185-94.
10. Grunder U. Stability of the mucosal topography around single-tooth implants and adjacent teeth: 1-year results. *Int J Periodontics Restorative Dent*. 2000;20(1):11-7.
11. Henriksson K, Jemt T. Measurements of soft tissue volume in association with single-implant restorations: a 1-year comparative study after abutment connection surgery. *Clin Implant Dent Relat Res*. 2004;6(4):181-9.
12. Bratu EA, Tandlich M, Shapira L. A rough surface implant neck with microthreads reduces the amount of marginal bone loss: a prospective clinical study. *Clin Oral Implants Res*. 2009; 20(8):827-32.
13. Pradeep AR, Karthikeyan BV. Peri-implant papilla reconstruction: realities and limitations. *J Periodontol*. 2006;77(3):534-44.
14. Schrottenboer J, Tsao YP, Kinariwala V, Wang HL. Effect of microthreads and platform switching on crestal bone stress levels: a finite element analysis. *J Periodontol*. 2008;79(11):2166-72.
15. Kan JY, Rungcharassaeng K. Interimplant papilla preservation in the esthetic zone: a report of six consecutive cases. *Int J Periodontics Restorative Dent*. 2003;23(3):249-59.
16. Choquet V, Hermans M, Adriaenssens P, Daelemans P, Tarnow DP, Malevez C. Clinical and radiographic evaluation of the papilla level adjacent to single-tooth dental implants. A retrospective study in the maxillary anterior region. *J Periodontol* 2001;72(10):1364-71.
17. Ozdemir E, Yener Oguz. The effect of immediate implant placement and immediate loading on interdental papillae heights in single implants and adjacent implants. *OHDM* 2015; 14 (2): 104- 108.
18. Mankoo T. Maintenance of interdental papillae in the esthetic zone using multiple immediate adjacent implants to restore failing teeth – a report of ten cases at 2 to 7 years follow-up. *Eur J Esthet Dent* 2008;3:304–322.

Source of support: Nil

Conflict of interest: None declared

This work is licensed under CC BY: *Creative Commons Attribution 3.0 License*.