(e) ISSN Online: 2321-9599
(p) ISSN Print: 2348-6805

Index Copernicus Value [ICV] = 80.90

ORIGINAL RESEARCH

Accuracy of ultrasonography in detection of kidney stones

Dr. Arun Kumar Sandhu[1], Dr. Sankalp Dwivedi[2]

[1]Associate professor Department of Radiodiagnosis, M.M. institute of Medical Sciences & Research Mullana, Ambala Haryana 133207;
[2]Professor Department of Surgery, M.M. institute of Medical Sciences & Research Mullana, Ambala Haryana 133207

ABSTRACT:
Background: Clinicians in a range of medical specialties will encounter patients with kidney stones. The present study was conducted to assess cases of kidney stones using USG. **Materials & Methods:** 82 cases with kidney stones of both genders. All underwent US examinations using transmit frequency of 2.5 to 6.0 MHz. **Results:** Out of 82 patients, males were 50 and females were 32. <4 mm stones were seen in 48 and >4 mm in 34 patients. The difference was significant (P< 0.05). Echo findings found to be marked in 42, slight in 30 and indistinct in 10. **Conclusion:** Echo findings found to be marked, slight and indistinct.
Key words: Kidney stones, Echo, USG

Corresponding author: Dr. Sankalp Dwivedi, Professor Department of Surgery, M.M. institute of Medical Sciences & Research Mullana, Ambala Haryana 133207, India

This article may be cited as: Sandhu AK, Dwivedi S. Accuracy of ultrasonography in detection of kidney stones. J Adv Med Dent Scie Res 2017;5(8):111-113.

INTRODUCTION

Clinicians in a range of medical specialties will encounter patients with kidney stones. As many as one in 11 Americans develop nephrolithiasis, and over the past 15 years the prevalence has increased by almost 70%.[1] The number of imaging studies ordered to evaluate for kidney stones is also increasing: from 1992 to 2009 the use of CT for imaging patients with kidney stones tripled[3]. Imaging of patients presenting with suspected kidney stones facilitates diagnosis and provides the first step in management by establishing the size and location of stones.[2]

Pain in abdominal may be due to abnormalities in gall bladder, kidneys, pancreas, stomach, duodenum, spleen etc. Kidney stone disease (urolithiasis) is when a solid piece of material (kidney stone) occurs in the urinary tract. Kidney stones typically form in the kidney and leave the body in the urine stream.[3]

Ultrasonography (US) is an accessible, relatively inexpensive imaging method that comes without the risks of exposure to ionizing radiation entailed by CT.[4] Stafford et al[5] reported the ability to detect stones as small as 2 mm using US imaging in a porcine model more than 30 years ago. With an ability to demonstrate radiopaque and radiolucent stones, hydronephrosis, renal inflammation, ruptured fornices, ureteric jets and resistive index, US can provide valuable clinical information. The present study was conducted to assess cases of kidney stones using USG.

MATERIALS & METHODS

The present study comprised of 82 cases with kidney stones of both genders. All accepted to participate in the study and gave their consent.

Data such as name, age, gender etc. was recorded. All underwent US examinations using transmit frequency of 2.5 to 6.0 MHz. Color Doppler USG was performed using a red and blue color map and power Doppler USG using a pink color map with a standardized Doppler protocol to detect the twinkling artifact. The gray-scale US appearance of urinary stones was analyzed for size, echo difference between stone and adjacent tissue, and posterior acoustic shadowing. Stone size was determined on gray-scale US alone. Results thus obtained were subjected to statistical analysis. P value less than 0.05 was considered significant.

RESULTS

Table I Distribution of patients

Total- 82		
Gender	**Males**	**Females**
Number	50	32

Table I shows that out of 82 patients, males were 50 and females were 32.

Table II Distribution of patients based on size

Size	Number	P value
<4 mm	48	0.05
>4 mm	34	

Table II shows that <4 mm stones were seen in 48 and >4 mm in 34 patients. The difference was significant (P< 0.05).

Table III Assessment of Echo in patients

Echo	Number	P value
Marked	42	0.01
Slight	30	
Indistinct	10	

Table III, graph I shows that echo findings found to be marked in 42, slight in 30 and indistinct in 10.

Graph I Assessment of Echo in patients

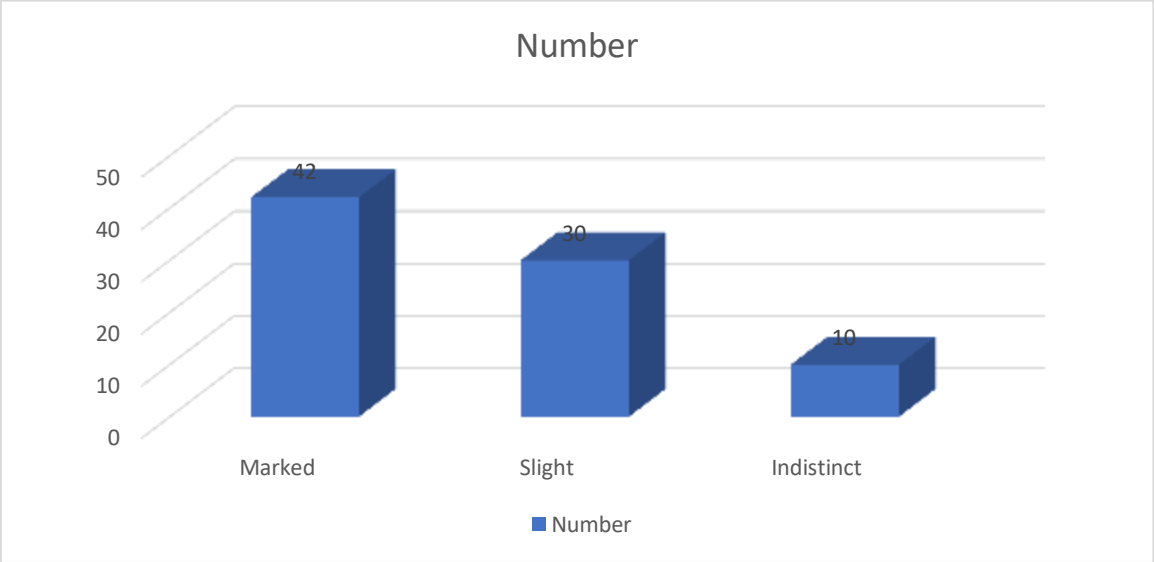

DISCUSSION

Renal stones are common disease in both developed and developing countries. This pathology has become more common over the past few decades as a result of the rapid variations in dietary habits and the increasing standard of living.[6] Changes in socioeconomic conditions over time have affected not only the incidence but also the site and chemical composition of calculi.[7] Renal stones, composed of ammonium urate and calcium whereas renoureteral calculosis featuring mainly calcium oxalate and phosphate is currently more frequent in economically developed countries. Chronic kidney disease (CKD) is becoming a major public health problem worldwide.[8] The present study was conducted to assess cases of kidney stones using USG.

In present study, out of 82 patients, males were 50 and females were 32. We observed that <4 mm stones were seen in 48 and >4 mm in 34 patients. Hanchate et al[9] in their study out of 40 patients, 22 were males and 18 were females. The difference was non - significant (P > 0.05). Renal stones with size < 4mm were 28 and ureteral stones were 18. Renal stones with size > 4mm were 20 and ureteral stones were 6. Gray scale USG detected 60% of stones with size < 4mm and 80% with size > 4mm. Color Doppler USG detected 95% with stones < 4mm and 100% with stones > 4mm. The difference was significant (P < 0.05). Echo difference in renal stones was marked (30), slight (4) and indistinct (14) and in ureteral stones was marked (13), slight (3) and indistinct (8). The difference was significant (P < 0.05). In marked posterior shadowing in renal stones 30 had strong intensity and in ureteral stones had 13 had strong intensity.

We observed that echo found to be marked in 42, slight in 30 and indistinct in 10. Sometimes it is difficult to determine whether a urinary stone is present because of its indistinct echogenicity and indiscrete posterior acoustic shadowing.[10] Indistinct echogenicity of stones results from surrounding echogenic tissue, such as prominent renal sinus fat, mesenteric fat, and bowel. When a renal stone is poorly distinguished from echogenic renal sinus fat and has an indiscrete posterior acoustic shadowing.[11]

Ganesan et al[12] retrospectively identified all patients at our institution with a diagnosis of nephrolithiasis who underwent US followed by non-contrast computed tomography (CT) within 60 days. A total of 552 US and CT examinations met the inclusion criteria. Overall, the sensitivity and specificity of US was 54 and 91%, respectively. There was a significant association between sensitivity of US and stone size ($P < 0.001$), but not with stone location ($P = 0.58$). US significantly overestimated the size of stones in the 0–10 mm range ($P < 0.001$). Assuming patients with stones 0–4 mm in size will be selected for observation and those with stones ≥5 mm could be counselled on the alternative of intervention, we found that in 14% (54/384) of cases where CT would suggest observation, US would lead to a recommendation for intervention. By contrast, when CT results would suggest intervention as management, US would suggest observation in 39% (65/168) of cases. An average of 22% (119/552) of patients could be inappropriately counselled. Stones classified as 5–10 mm according to US had the highest probability (43% [41/96]) of having their management recommendation changed when CT was performed. The use of plain abdominal film of kidney, ureter and bladder and US increases sensitivity (78%), but 37% (13/35) of patients may still be counselled inappropriately to undergo observation.

CONCLUSION

Authors found that echo findings found to be marked, slight and indistinct. Using USG to guide clinical decision-making for residual or asymptomatic calculi is limited by low sensitivity and inability to size of the stone accurately.

REFERENCES

1. Pinto A, Caranci F, Romano L, Carrafiello G, Fonio P, Brunese L: Learning from errors in radiology: a comprehensive review. Semin Ultrasound CT MR. 2012; 33: 379-82.
2. Lee JY, Kim SH, Cho JY, Han D: Color and power Doppler twinkling artifacts from urinary stones: clinical observations and phantom studies. AJR Am J Roentgenol. 2001; 176: 1441-5.
3. Sheafor DH, Hertzberg BS, Freed KS, Carroll BA, Keogan MT, Paulson EK, et al. Nonenhanced helical CT and US in the emergency evaluation of patients with renal colic: prospective comparison. Radiology. 2000; 217: 792-7.
4. Aytac SK, Ozcan H: Effect of color Doppler system on the twinkling sign associated with urinary tract calculi. J Clin Ultrasound. 1999; 27: 433-9.
5. Kane RA, Manco LG: Renal arterial calcification simulating nephrolithiasis on sonography. AJR Am J Roentgenol. 1983; 140: 101-4.
6. Ramello A, Vitale C, Marangella M. Epidemiology of nephrolithiasis. J Nephrol. 2000; 13:45-50.
7. Coresh J, Selvin E, Stevens LA, Manzi J, Kusek JW, Eggers P, et al. Prevalence of chronic kidney disease in the United States. J. Amer. Dent. Assoc. 2007; 298: 2038-47.
8. Frymoyer PA, Scheinman SJ, Dunham PB, Jones DB, Hueber P, Schroeder ET. X-linked recessive nephrolithiasis with renal failure. N Engl J Med. 1991; 325: 681-6.
9. Leumann EP. Primary hyperoxaluria: an important cause of renal failure in infancy. Int J Pediatr Nephrol 1985; 6: 13-6. 5. Gambaro G, Favaro S, D'Angelo A. Risk for renal failure in nephrolithiasis. Am J Kidney Dis 2001; 37: 233-43.
10. Foley RN, Collins AJ. End-stage renal disease in the United States: an update from the United States Renal Data System. J Am Soc Nephrol. 2007; 18: 2644-8.
11. Hanchate V. Twirkling sign in detection of renal and ureteral stone: A clinical study. J Adv Med Dent Scie Res 2017;5(1):146-148.
12. Ganesan V, De S, Greene D, Torricelli FC, Monga M. Accuracy of ultrasonography for renal stone detection and size determination: is it good enough for management decisions?. BJU international. 2017 Mar;119(3):464-9.