

Original Article

Assessment of Outcome Measures of Bipolar Hip Arthroplasty for Atraumatic Hip Disorders: A Clinical Study

Yogesh Kumar Agarwal, Medical Officer (Orthopaedics), RBM Hospital, Bharatpur, Rajasthan, India.

ABSTRACT:

Background: The bipolar hip arthroplasty was originally proposed for femur neck fracture in aged patients. Gradually, indications were implied for conditions involving acetabulum like osteoarthritis rheumatoid arthritis, and even avascular necrosis of the femoral head. **Materials and methods:** Study was conducted in 25 such patients who were diagnosed of bipolar hip arthroplasty, which involved acetabulum. That may be because of primary osteoarthritis, rheumatoid arthritis, avascular necrosis of the femoral head. A tight 'equatorial' or 'rim' fit of the prosthesis were devised for acetabulum. A 1 mm larger prosthesis was selected with respect to the maximum size of reamer to be used. Accordingly, in case of marked osteoporosis or wide medullary canal cement was used in the femur. During the post-operative follow-up all patients were screened for post-operative pain, extent of movement, protrusion of the acetabulum, loosening of the prosthesis and radiographic evaluation of the movement in the two bearings of the prosthesis. **Results:** On an average, results so achieved ranged from good to excellent in 75% of the patients. **Conclusion:** The overall satisfactory results achieved and are comparable to complete hip arthroplasty. The procedure is low cost, simple and easy for future corrections.

Key words: Rheumatoid arthritis, bipolar hip arthroplasty, Osteoarthritis.

Received: 15 April, 2018

Revised: 28 April, 2018

Accepted: 29 May, 2018

Corresponding Author: Dr. Yogesh Kumar Agarwal, Medical Officer (Orthopaedics), RBM Hospital, Bharatpur, Rajasthan, India.

This article may be cited as: Agarwal YK. Assessment of Outcome Measures of Bipolar Hip Arthroplasty for Atraumatic Hip Disorders: A Clinical Study. J Adv Med Dent Scie Res 2018;6(6):105-108.

INTRODUCTION:

The use of a bipolar implant in hip reconstruction is used primarily in cases of fresh fractures for the aged patients, conditions like aseptic necrosis and non-union of the femoral neck. Which was proposed by Bateman in the year 1974.¹ In addition to this, contributions have been made based upon the use of the femoral head implant prosthesis in conditions like aseptic necrosis and trauma. This marked success involving the bipolar prosthesis in the fractures of the femur neck gave a new outlook and chance of its use in conditions of the hip which were traditionally treated with total hip arthroplasty.² Such conditions are namely: (A) Advanced osteoarthritis of hip, (B) Primary or Secondary cases of rheumatoid arthritis, (C) Avascular necrosis involving the femoral head, (D) Even cases like acetabular dysplasia. To reduce the occurrence of conditions like protrusio-acetabuli and stem loosening the design of the bipolar hip prosthesis is such that it reduces the shear stress in the system, leading to its marked success and versatile use.^{3,4} It is interesting to note that the acetabulum is more secure as the bipolar prosthesis is designed to absorb stress way better than the traditional prosthesis.⁵ Increased range of motion and less

chances of dislocation are another added advantages of the bipolar design providing more stability than traditional prosthesis.⁶ The present study was conducted with the aim to study the outcome of bipolar hip arthroplasty amongst subjects reporting to the hospital.

MATERIALS AND METHODS:

The study was conducted in the Department of orthopaedics and it included the subjects with mean age of 55 years. A total of 25 patients were studied. Out of which 14 patients suffering from rheumatoid arthritis, 8 cases of avascular necrosis of femoral head involvement and 3 cases of primary osteoarthritis were marked as study material. A pre-operative radiographic evaluation of the patients was conducted which involved antero-posterior view in internal rotation of the pelvis showing both hips and lateral view of the hip involving the anomaly. Harris hip score was used for clinical evaluation of the patient. During the planning phase it was established that articulated (fixed) bipolar prosthesis would be used in patients more than 63 years of age, rest in younger patients i.e. less than 63 years of age a modular prosthesis would be used. During the procedure

postero-lateral approach was made to the hip joint, dislocating the joint capsule along with the base of the neck. As the pre-determined condition, the neck of the femur was osteotomised at the position defined pre-operative.⁷To create tight-fit the dimensions of the neck are made to select the prosthesis of the same dimensions. Reaming is necessary as to remove loose cartilage and tidy-up the acetabulum concentric. Interestingly the size of outer head of the selected prosthesis is kept 1mm bigger than the acetabular reamer, which was last used to get the desired tight fit. Now bringing post-operative care into consideration the reduced position of the prosthesis was radio-graphically established. A special triangular pillow was placed between the legs of the patient to maintain abduction movement while transferring patient to the ward, which was replaced by a long knee brace which was mandatory for a period of 10 days to 3 weeks. Mobilization that to in the bed was allowed after 2 days followed by active and active assisted physiotherapy for 5 days. Subsequently on the 5th day, the wound was dressed and the patients were made to walk with the help of walker. All sutures were removed on the tenth day and full weight bearing was permitted with walker. Now patients were discharged on the day 12. With an advice not to squat or sit cross-legged, along with use of chair commode for toilet. Gradually the walker is withdrawn within 4 - 6 weeks, with an advised to use cane from the opposite side to increase the life of the prosthesis. Patients were regularly followed-up every 15 days for a

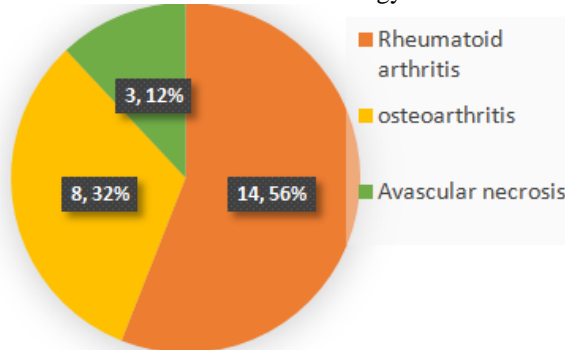
period of 4 months and later on biannually continuing for 3 years' time. Each time Harris hip score was evaluated and any evidence of protrusion-acetabuli and stem loosening were evaluated alongside. Radiographs were each time made to compare the movement of cups with respect to each other. All the data was arranged in a tabulated form and analysed using SPSS software.

RESULTS:

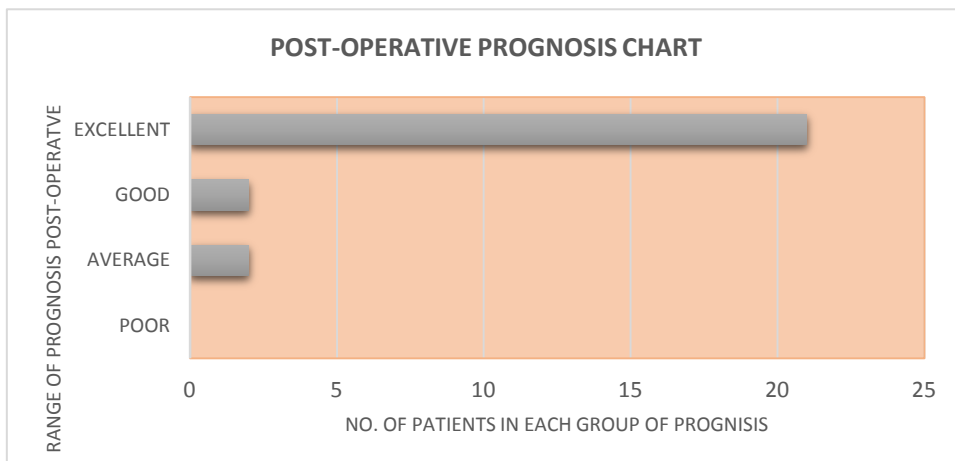
Graph 1 shows the number of patients involved with the commonly associated aetiology. There were 3 cases of avascular necrosis and 8 cases of osteoarthritis. Majority of subjects i.e. 14 had rheumatoid arthritis.

Graph 2 shows the prognosis of the subjects. The post-operative assessment was evaluated on Harris hip score and marked as excellent, good, fair and poor. Around 21 of the total 25 patients had good- to- excellent results of the bipolar hip arthroplasty. Not a single case of protrusion of acetabula was observed. Also the prosthesis had ossified up to 2 to 4 mm was seen in each cases of rheumatoid arthritis and also bone cement was not used, not affecting the function of the hip clinically. No occurrence of dislocation or infection at all. Heterotrophic pattern of ossification was seen in one patient suffering with primary osteoarthritis. There was only one poor results in rheumatoid case where the un-cemented prosthesis loosened in femoral canal slightly more than 2mm. This patient was advised corrective surgery.

Graph 1: The number of patients involved and the most common aetiology



Graph 2: Postoperative prognosis chart



DISCUSSION:

Total hip arthroplasty is an established choice of treatment in severe cases of (a) rheumatoid arthritis, (b) avascular necrosis and (c) osteoarthritis of the hip. The procedure has very good success rate with rare failures. Prime drawback is the loosening of the acetabular component and mal-alignment resulting in instability and dislocation causing difficulty in revision. Looking at the studies of Bateman closely, a count of 760 degenerative hips followed in a time of 15 years have yielded favourable results on Harris hip score (from 51-87).^{8,9} A healthy acetabular bone preservation is observed along with gradual acetabular floor formation. According to McConville et al in their 100 routine patients of degenerative arthritis were treated with bipolar hip arthroplasty.¹⁰ They also established it to be an alternative method to total hip arthroplasty especially in cases where complications related to acetabulum were almost none. In this case 93 out of 96 good-to-excellent results have been established in case of osteoarthritis.^{11,12,13} A Bipolar hip arthroplasty has also been tried in avascular necrosis of femoral head for few number of years.^{14,15} Patients diagnosed with severe rheumatoid arthritis involving multiple joints are weak and cannot bear multiple soft tissue and complete joint replacement procedures in short time period. In situations like this, bipolar hip arthroplasty is an alternative surgery option which is less invasive yet showing promising results. In the studies conducted in our trial one rheumatoid hips showed loosening of femoral stems over a period of 5 year. In this case a unique mono-block prosthesis was used along with the un-cemented stems. There has been a constant variation in views about use of cement in bipolar hip arthroplasty. In our study cases we had used cement wherever or not femoral canal was wide or osteoporotic irrespective of the age of the patient. Wherever good bone stock was observed un-cemented fixation was done. Considering the calcar to canal isthmus (CC) ratio as given by Dorr for the use of cement, any ratio more than 75% is recommended as a contraindication of non-cemented arthroplasty.¹⁶ There was no incidence of dislocation of the prosthesis in our study. Also bipolar prosthesis has a self-aligning acetabular part, which corrects orientation on its own. Severe problems like, subluxation and dislocation is taken care, rather in complete hip arthroplasty is dislocation occurs quite commonly it requires extensive corrective surgery.¹⁷ Formation of ectopic para-articular bone after total hip arthroplasty in patients with osteoarthritic hips is common i.e. up to 60-80%.^{18,19,20} In about 5-10% cases function was impaired in complete hip arthroplasty.^{21,22} The bipolar hip arthroplasty shows least chances of failures and post-operative complications, as allows minimal bone preparation and minimal exposure of the capsule. Considering and comparing the side effects of bipolar hip arthroplasty, incidence of groin pain and thigh pain have been observed. In certain cases groin pain can be as high up to 42%. Also poor fitting prosthesis led to cartilage necrosis. Concluding the discussion for bipolar hip arthroplasty has emerged as a

popular and safe alternative to more extensive complete hip arthroplasty in cases where prognosis was always questionable and doubtful i.e. avascular necrosis of femur, osteoarthritis. But in case of rheumatoid arthritis it needs more elaborated study. In addition the procedure is simple and cost effective. Considering a surgeons point of view it is less demanding and has a rapid learning curve. Loss of blood and operating time is also less as compared to complete hip arthroplasty with minimal chances of infection. It is worth noticing that the in bipolar hip arthroplasty no chances of complications are present in the acetabular component (outer head) as it is independent while chances of complications pertaining to total hip arthroplasty are more as acetabular component is fixed leading to cementing, mal-alignment, instability, loosening and dislocation. Art is in selecting correct bipolar implant to ensure that the bipolar outer head is provided with concentric tight fit in acetabulum. Selecting a stem which provides complete fit and fill of the medullary cavity of the femur bone. Correction of bipolar arthroplasty is easily preformed as compared to the correction of total hip arthroplasty. In the end we would like to add that the bipolar hip arthroplasty is a procedure which a qualified orthopaedic surgeon can master with help of proper training and knowledge. Least chances of complications pertain to cup placement are observed which is one of the major complications seen in total hip replacement.

CONCLUSION

From the above study we can conclude that, satisfactory results achieved which are comparable to complete hip arthroplasty. The procedure is low cost, simple and easy for future corrections. This can be used in future for the economically weaker sections with good prognosis.

REFERENCES

1. Bateman JE: Single-assembly total hip: Preliminary report. *Orthop Digest*. 1974; 2: 15.
2. Bateman JE: Experience with a multiple bearing implant in hip joint reconstruction. *Orthop Trans*. 1981; 5: 421.
3. Devas M, Hinves B: Prevention of acetabular erosion after hemiarthroplasty
4. Scott RD: Use of a bipolar prosthesis with bone grafting in acetabular reconstruction. *Contemp Orthop*. 1984; 9: 35.
5. Giliberty RP: Bipolar endoprosthesis minimizes protrusioacetabuli, loose stems. *Orthop Rev*. 1985; 14: 27.
6. Drinker H, Murray WR: The universal proximal femoral endoprosthesis. *J Bone Joint Surg (Am)*. 1979; 61: 116-7.
7. Lestrnage NR: Bipolar arthroplasty for 496 hip fractures. *Clin Orthop*. 1990; 251: 7.
8. Dudani BG, Azam SM, Madhukeshwar GV: Bipolar hemiarthroplasty for fractures of the neck of femur in the elderly. *Ind J Orthop*. 2004; 38: 12-15.
9. Lestrnage NR: Bipolar arthroplasty for 496 hip fractures. *Clin Orthop*. 1990; 251: 7.
10. Bateman JE, Berenji AR, Bayne O, and Greyson ND: Long term results of bipolar arthroplasty in osteoarthritis of hip. *Clin Orthop*. 1990; 251: 54-66.
11. McConville OR, Bowman AJ Jr, Kilfoyle RM, McConville JF, Mayo RA: Bipolar hip arthroplasty in degenerative arthritis of the hip. *Clin Orthop* 1990; 251: 67

12. Vazquez-vela G, Vazquez-vela E, Dobarganes FG: The Bateman bipolar prosthesis in osteoarthritis and rheumatoid arthritis - a review of 400 cases. ClinOrthop 1990; 251: 82.
13. Pandit R. Bipolar femoral head arthroplasty in osteoarthritis. A prospective study with a minimum 5-year follow-up period. J Arthroplasty, 1996; 11:560-4
14. Fantasia L, Cornacchia D, La Foresta P : Bipolar Arthroplasty as a treatment in osteoarthritis of the hip - preliminary report. International Bipolar News, 1996
15. Kindsfater KA, Spitzer AI, Schaffer JL, Scott RD: Bipolar hip arthroplasty for primary osteoarthritis of the hip - a review of 41 cases with 8 to 10 years of follow up. Orthopaedics 1998; 21(4): 425 (ISSN: 01477447).
16. Cabanela ME: Bipolar versus total hip arthroplasty for avascular necrosis of the femoral head. A comparison ClinOrthop. 1990; 261, 59-62.
17. Floren M, Lester D: Outcomes of total hip arthroplasty and contralateral bipolar hemiarthroplasty: a case series. J Bone Joint Surg (Am). 2003 ;85-A(3):523-6
18. International Bipolar News: The Uses of the Bipolar Cup in Trauma and Degenerative Pathologies. Meeting Report 11-12th April 1997; Foggia, Italy
19. Chan Y, Shih C: Bipolar versus total hip arthroplasty for hip osteonecrosis in the same patient. ClinOrthop. 2000; 379: 169-177.
20. Hiroshi I, Matsuno T, Kaneda K: Bipolar hip arthroplasty for osteonecrosis of the femoral head - a 7 to 18 years follow up. Clin Orthop2000; 374: 201.
21. Mess D, Barmada R: Clinical and motion studies in Bateman bipolar prosthesis in osteonecrosis of the hip ClinOrthop 1990; 251: 44-47.
22. Bhan S: Bipolar Concept and its utility. Recent advances in Orthopaedics. Jaypee Publishers (P) Ltd, New Delhi, 1993; 69-92.

Source of support: Nil

Conflict of interest: None declared

This work is licensed under CC BY: ***Creative Commons Attribution 3.0 License.***