

## *Original Article*

### **Efficacy of Antibiotic Prophylaxis after Removal of Impacted Mandibular Third Molar**

M. Vinoth<sup>1</sup>, Navaneeth Yerragudi<sup>2</sup>, Neila Mendonca<sup>3</sup>, Vignesh Prabhu T<sup>4</sup>, G. Anbu Selvan<sup>5</sup>, Maishori Hidangmayum<sup>6</sup>

<sup>1</sup>Associate Consultant in Maxillofacial and Plastic Surgery, Apollo Hospital, Bangalore, Karnataka, India,

<sup>2,4</sup>Associate Consultant Oral and Maxillofacial Surgeon, Rangadore Memorial Hospital, Bangalore, Karnataka, India,

<sup>3</sup>Associate Consultant Oral and Maxillofacial Surgeon, Silicon city Hospital, Bangalore, Karnataka, India,

<sup>5,6</sup>Post Graduate Student, Department of Oral and Maxillofacial Surgery, AECS Maaruti College of Dental Sciences, Bangalore, Karnataka, India

#### **ABSTRACT:**

**Background:** Removal of impacted teeth is a very common surgical procedure performed by dentists. The importance of the patient's discomfort from the surgical removal of third molar impaction is the post-operative complications infection. The antibiotics have been utilized to prevent or reduce the occurrence of those incidences. So the present was aimed to evaluate the efficacy of antibiotic prophylaxis after removal of impacted mandibular third molar. **Materials and Methods:** A double-blind clinical study was done on 30 healthy out-patients (12 females and 18 males) age range of 18 to 28 years with impacted mandibular third molars were taken for the study. A total of 30 patients were randomly allocated into two study groups comprising of 15 study participants in each group. Group 1: 625 mg of combined amoxicillin and clavulanic acid tablet + 400 mg metronidazole tablet for 5 days Group 2: No antibiotic prophylaxis. Both the groups were assessed postoperatively on the 1st, 2nd, 5<sup>th</sup> and 7<sup>th</sup> day by the same observer for post operative mouth opening (interincisal distance), pain and presence of a purulent discharge at the site of surgery. Vernier caliper was used to record the post operative mouth opening in millimeters. Post operative pain was assessed by using a four-point Visual Analogue Scale (VAS). **Results:** The severity of pain recorded using VAS score showed no statistically significant differences between the study groups on day 1. But, the number of study participants with severe pain was observed to be more in group 1. On day 2, the number of study participants with severe pain was slightly reduced in the group 1 as compared with group 2. On day 5, patients with no pain were more in group 1 followed by group 2 which was statistically significant. Pain was completely reduced at 7<sup>th</sup> day in both the study groups. On 2<sup>nd</sup>, 5<sup>th</sup> and 7<sup>th</sup> day mouth opening was slightly more in group 1 study participants (25.42±1.80, 30.68±0.96, 33.60±1.42mm) respectively. And there was a statistically significant difference observed between the study groups on day 5. On day 5 and 7 there was a slightly more purulent discharge in group 2 (5 participants & 2 participants) compared to group 1 (3 subject & 1subject) respectively. **Conclusion:** On conclusion, administration of an antibiotic prophylaxis showed no significant differences in the degree of postoperative complications that occur after surgical removal of impacted mandibular third molars.

**Key words:** antibiotic prophylaxis, mouth opening, purulent discharge, third molar surgery.

Received: 4 August 2018

Revised: 28 August 2018

Accepted: 29 August 2018

**Corresponding Author:** Dr. M. Vinoth, Associate Consultant in Maxillofacial and Plastic Surgery, Apollo Hospital, Bangalore, Karnataka, India

**This article may be cited as:** Vinoth M, Yerragudi N, Mendonca N, T Prabhu V, Selvan GA, Hidangmayum M. Efficacy of Antibiotic Prophylaxis after Removal of Impacted Mandibular Third Molar. J Adv Med Dent Scie Res 2018;6(9):107-110.

## **INTRODUCTION:**

The most common post-operative complications after surgical procedures is infection. It might inevitably occur which sometimes cause severe morbidity to the patients. From the biological point of view; improper patient's immunity, imbalance of biology at surgical site and microorganism imbalance would be the cause of infection in patient undergone surgery, furthermore, 60 to 95% of the oral and maxillofacial infection was the cause of mixed bacteria.<sup>1</sup>

Removal of impacted teeth is a very common surgical procedure performed by dentists. Owing to the complexity of this surgical procedure, extensive skills and training are required in order to reduce the risk of complications that may arise during or after surgery.<sup>2</sup> In addition, adequate knowledge regarding the diagnostic and treatment modalities is essential in order to achieve optimum results for the patients.

Complications associated with third molar surgery can be classified as either infection or non-infection related. Non-infection related complications usually feature pain, swelling and erythema due to the normal inflammatory process following surgical trauma, while complications that occur with infection include alveolar osteitis, osteomyelitis, lymphadenopathy (localized/generalized) and fascial space involvement.<sup>3</sup>

The use of antibiotic therapy is well established in the treatment of identified infections caused by susceptible microorganisms and for prophylaxis in clean contaminated or contaminated surgery and in the prevention of sub acute bacterial endocarditis after intraoral procedures in patients after total joint implantation and in the prevention of infection in the immunocompromised patient. The potential drawbacks of antibiotic overprescribing, including the development of hypersensitivity or allergic reactions, and the emergence of resistant microorganisms, might exceed the risk of infection.<sup>4</sup> However although third molar surgery may usually be considered clean-contaminated and occasionally contaminated surgery, the use of routine antibiotic prophylaxis in patients undergoing such surgery is a controversial topic. It is common practice in oral and maxillofacial surgery to use antibiotics after third molar surgery. In some offices it is a universal practice to prescribe them for all patients having routine removal of impacted third molars.<sup>5</sup> Hence present study was conducted to evaluate the efficacy of antibiotic prophylaxis after removal of impacted mandibular third molar.

## **MATERIALS AND METHODS:**

The present double-blind clinical study was conducted on 30 healthy out-patients (12 females and 18 males) age range of 18 to 28 years with impacted mandibular third molars were taken for the study. Patients with a doubtful medical history or acute infection were excluded. Each subject was informed of the potential risks and benefits of the experimental procedure, and consent was obtained from

those who elected to participate. Participants were enrolled based on the presence of impacted mandibular third molars that were confirmed radiographically.

## **Surgical Method:**

All the patients underwent surgical extraction of the impacted mandibular third molars under strict aseptic techniques. Care was taken to ensure that only very minimal trauma is caused to the surrounding tissues. Local anesthesia of 2% lignocaine with 1:200,000 adrenaline was used to administer the inferior alveolar, lingual, and long buccal nerve blocks. Envelope mucoperiosteal flap elevation with osteotomy was achieved using a surgical scalpel blade no. 15. Osteotomy was performed using a crosscut tapered fissure bur mounted on a straight handpiece. The tooth was sectioned appropriately where necessary depending on the surgeon's judgement whilst trying to achieve minimal surgical invasion And suturing done.

A total of 30 patients were randomly allocated into two study groups comprising of 15 study participants in each group.

**Group 1:** 625 mg of combined amoxicillin and clavulanic acid tablet + 400 mg metronidazole tablet for 5 days

**Group 2:** No antibiotic prophylaxis

Patients were prescribed with 400mg of Ibuprofen as analgesics and postoperative instructions of care were given, which included rinsing with warm saline three times daily starting from the day after surgery.

Both the groups were assessed postoperatively on the 1st, 2nd, 5<sup>th</sup> and 7th day by the same observer for post operative mouth opening (interincisal distance), pain and presence of a purulent discharge at the site of surgery.

Vernier caliper was used to record the post operative mouth opening in millimeters. Post operative pain was assessed by using a four-point Visual Analogue Scale (VAS):

0 = no pain,

1 = mild pain (pain being reported only in response to questioning and without any behavioural signs),

2 = moderate pain (pain being reported in response to questioning and accompanied by signs, or pain being reported spontaneously without questioning),

And 3 = severe pain (a strong vocal response or a response which was accompanied by grimaces, withdrawal of the arm, or tears). Purulent discharge at the site of surgery was recorded as present or absent.

## **Statistical Analysis:**

Data were tabulated in Microsoft Excel and analyzed for statistical difference between the two groups by the two-tailed Fisher's exact test with a 95% confidence interval using SPSS version 18.0 (SPSS 18 developed by IBM, Chicago, USA).

**RESULTS:**

Table 1 shows that, the severity of pain recorded using VAS score showed no statistically significant differences between the study groups on day 1. But, the number of study participants with severe pain was observed to be more in group 1. On day 2, the number of study participants with severe pain was slightly reduced in the group 1 as compared with group 2. On day 5, patients with no pain were more in group 1 followed by group 2 which was statistically significant. Pain was completely reduced at 7<sup>th</sup> day in both the study groups.

Table 2 depicts comparison of mouth opening among study participants. On 2<sup>nd</sup>, 5<sup>th</sup> and 7<sup>th</sup> day mouth opening was slightly more in group 1 study participants (25.42±1.80, 30.68±0.96, 33.60±1.42mm) respectively. And there was a statistically significant difference observed between the study groups on day 5. Graph 1 reveals the purulent discharge among the study participants. On day 5 and 7 there was a slightly more purulent discharge in group 2 (5 participants & 2 participants) compared to group 1 (3 subject & 1subject) respectively. There was no significant difference between the groups.

**Table 1: Comparison of Pain (VAS) among study groups**

Duration and groups		No pain	Mild pain	Moderate pain	severe pain	Fischer exact test
Day 1	Group 1	0	5	6	4	$\chi^2 = 5.320$ p = 0.412
	Group 2	0	5	7	3	
Day 2	Group 1	0	8	5	2	$\chi^2 = 8.452$ p = 0.241
	Group 2	0	6	6	3	
Day 5	Group 1	4	10	1	0	$\chi^2 = 10.886$ p = <b>0.02*</b>
	Group 2	3	7	4	1	
Day 7	Group 1	13	2	0	0	$\chi^2 = 8.964$ p = 0.681
	Group 2	14	1	0	0	

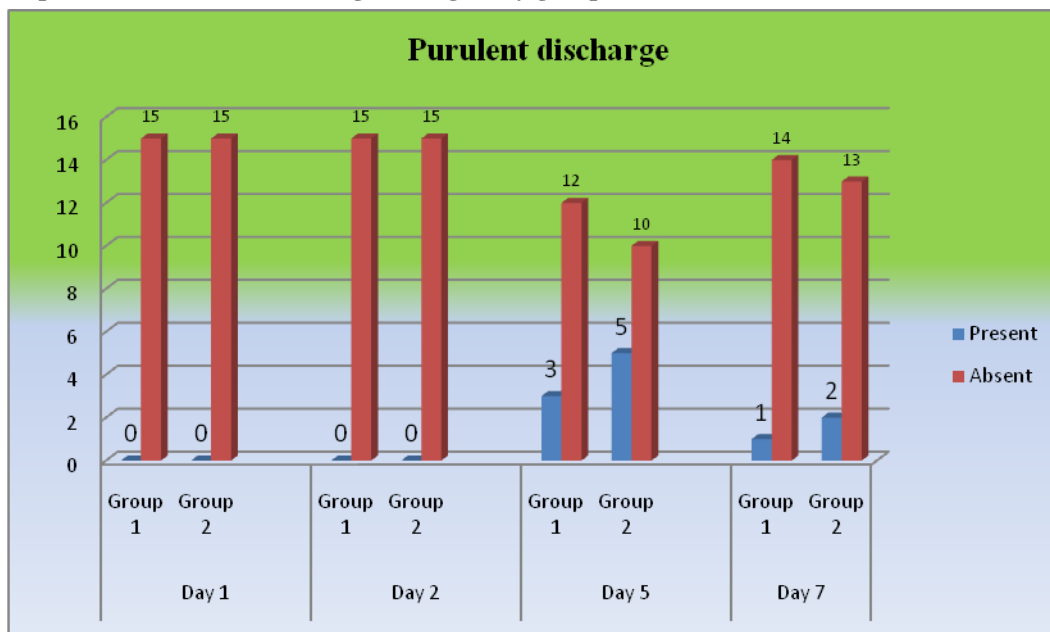
\*Statistically Significant

**Table 2: Comparison of mouth opening among study groups**

Duration	Groups	Mean±SD	t value	p value and significance
Day 1	Group 1	21.36±1.34	0.924	0.476
	Group 2	22.12±1.08		
Day 2	Group 1	25.42±1.80	2.102	0.128
	Group 2	23.36±1.78		
Day 5	Group 1	30.68±0.96	6.204	<b>0.012 *</b>
	Group 2	27.95±1.10		
Day 7	Group 1	33.60±1.42	1.357	0.266
	Group 2	33.10±1.18		

\*Statistically Significant

**Graph 1: Comparison of Purulent discharge among study groups**



## DISCUSSION:

The importance of the patient's discomfort from the surgical removal of third molar impaction is the postoperative complications infection. The antibiotics have been utilized to prevent or reduce the occurrence of those incidences. There were many previous studies showed the concern of the use of antibiotics for prevention and reduction of the postoperative lower third molar removal complications at the surgical site infection and alveolar osteitis.<sup>6</sup> our analysis from the previous articles supported the antibiotics use and also indicated that amoxicillin did significantly reduce the occurrence of postoperative complications infection.<sup>7</sup>

The most common form of antibiotic prophylaxis which is still being used is systemic administration,<sup>8</sup> although the use of antiseptic mouthwashes and placement of antibiotics in extraction socket have been shown to be partially effective in prevention of postoperative infections. More recently, attention has turned to utilization of drugs which are narrow spectrum and active only against causative pathogens. A specific anaerobicidal, metronidazole, has been shown to be effective in preventing complications which followed third molar surgeries<sup>9</sup> In the present study, oral route of administration of antibiotics was used. 625 mg of combined amoxicillin and clavulanic acid tablet + 400 mg metronidazole tablet for 5 days were prescribed for treatment group 1. Trismus that has resulted as a sequel to inflammation settles by itself in time, not needing any intervention. On the contrary, trismus prolongs for a longer duration and, worse still, it may even exacerbate when there is an infection. This complication can be limited by prescribing appropriate antibiotics.<sup>10</sup> The present study shows that there was a statistically significant difference between the study groups with regard to mouth opening, on day 5. Patients with no pain were significantly more in group 1 followed by group 2 on day 5. In contrast to the studies done by Sekhar et al<sup>11</sup> and Kaczmarzyk et al,<sup>12</sup> no statistically significant difference was found among the study groups in terms of pain and mouth opening. Therefore, routine prescription and the use of preoperative or postoperative antibiotics during extraction of the third molars fail to show any advantage.

The prevention of wound infection is one of the major goals of every surgeon. When infection does occur, increased patient morbidity and suffering result, with consequent additional expenses, increased antibiotic usage, and a delayed recovery. Principles of infection prevention have been clearly defined, which, when applied, can reduce infection rates to near zero.<sup>13</sup> and even few studies suggests in order to achieve the optimal antibiotics concentration in serum, the appropriate pre-operative time for the antibiotic administration should be up to two hours orally or up to 1 hours parenterally.<sup>14,15</sup> Rud proposed that the relative rarity of serious infections which followed third molar surgeries and the improvement of postoperative morbidity, which were observed over the past two decades, were caused more

likely due to improved patient management, better instrumentation and surgical techniques, and a greater awareness on the importance of strict asepsis.<sup>16</sup>

## CONCLUSION:

On conclusion, administration of an antibiotic prophylaxis showed no significant differences in the degree of postoperative complications that occur after surgical removal of impacted mandibular third molars.

## REFERENCES:

1. Stavropoulos MF, Shugars DA, Phillips C, Conrad SM, Fleuchaus P, White RP Jr. Impact of topical Minocycline with third molar surgery on clinical recovery and health-related quality of life outcomes. *J Oral Maxillofac Surg* 2006; 64: 1059-65.
2. Ness GM, Peterson LJ. Impacted teeth In: Miloro M, Ghali GE, Larsen PE, Waite PD, editors. *Peterson's Principles of Oral and Maxillofacial Surgery*. 2nd edition. Ontario: BC Decker: 2004: Chapter 8: 139-56.
3. Martin MV, Kanatas AN, Hardy P. Antibiotic prophylaxis and third molar surgery. *British Dental J*. 2005; 198: 327-30.
4. Al-Asfour A. Postoperative Infection after Surgical Removal of Impacted Mandibular Third Molars: An Analysis of 110 Consecutive Procedures. *Med Princ Pract* 2009; 18: 48-52.
5. Soodan K S et al. Prophylactic Antibiotics for Third Molar Surgery: An Enigma or Panacea? *IOSR Journal of Dental and Medical Sciences (IOSR-JDMS)* 2014;13(8):58-61.
6. Salmerón-Escobar JI, del Amo-Fernández de Velasco A. Antibiotic prophylaxis in Oral and Maxillofacial Surgery. *Med Oral Patol Oral Cir Bucal* 2006; 11: e292-6.
7. Pirasut Rodanant, Natthapong Athikijrungruang, Natthamet Wongsirichat. Is prophylactic antibiotic effective in lower third molar surgery?: article analysis *M Dent J* 2015 ; 35 ( 1):57-67.
8. Poeschl PW, Eckel D, Poeschl E. Postoperative prophylactic antibiotic treatment in third molar surgery – A necessity? *J Oral Maxillofac Surg*. 2004; 62: 3-8.
9. Kaziro GSN. Metronidazole and arnica montana in the prevention of post- surgical complications, a comparative, placebo controlled clinical trial. *Br J Oral Maxillofac Surg*. 1984; 22: 42-9.
10. Rohit S, Reddy BP. Efficacy of postoperative prophylactic antibiotic therapy in third molar surgery. *J Clin Diagn Res* 2014 May;8(5):ZC14-ZC16.
11. Sekhar CH, Narayanan V, Baig MF. Role of antimicrobials in third molar surgery: Prospective, double blind, randomized, placebo-controlled clinical study. *Br J Oral Maxillofac Surg* 2001 Apr;39(2):134-137.
12. Kaczmarzyk T, Wichlinski J, Stypulkowska J, Zaleska M, Panas M, Woron J. Single-dose and multi-dose clindamycin therapy fails to demonstrate efficacy in preventing infectious and inflammatory complications in third molar surgery. *Int J Oral Maxillofac Surg* 2007 May;36(5):417-422.
13. Peterson LJ. Antibiotic prophylaxis against wound infections in oral and maxillofacial surgery. *J Oral Maxillofac Surg*. 1990; 48: 617-20.
14. Foy SP, Shugars DA, Phillips C, Marciani RD, Conrad SM, White RP. The Impact of Intravenous Antibiotics on Health-Related Quality of Life Outcomes and Clinical Recovery After Third Molar Surgery. *J Oral Maxillofac Surg* 2004; 62: 15- 21.
15. Bergdahl M, Hedstrom L. Metronidazole for the prevention of dry socket after removal of partially impacted mandibular third molar: a randomized controlled trial. *Br J Oral Maxillofac Surg* 2004; 42: 555-8.
16. Rud J. Removal of impacted lower third molars with acute pericoronitis and necrotizing gingivitis. *Br J Oral Surg*. 1970; 7: 153-60.