

## Case Report

### Endodontic management using Cone Beam Computed Tomography of maxillary molar having C-Shaped Anatomy: A Case Report

Aabha<sup>1</sup>, Ruchi Singla<sup>2</sup>, Vivek Kapoor<sup>3</sup>, Amandeep Singh Uppal<sup>4</sup>

<sup>1-4</sup>Department of Conservative Dentistry and Endodontics, Dr. Harvansh Singh Judge Institute of Dental Sciences, Panjab University, Chandigarh

#### ABSTRACT:

While performing endodontic treatment, every case is a new case, presenting new challenges. The internal anatomy of a tooth is very complex, more than what is evident on a radiograph. The advantages of CBCT imaging over conventional radiography in endodontic diagnosis is well documented. C-shape morphology presents special challenge to the endodontist as it is difficult to shape, clean, fill. This type of morphology is most common in the mandibular second molars and very rare in the maxillary molars. This case report presents a unique case of managing a patient with C-shape canal in maxillary first molar.

**Key words:** Endodontics, management, C-shape canal, maxillary molar, CBCT

**Received:** 04/06/2020

**Modified:** 22/07/2020

**Accepted:** 25/07/2020

**Corresponding Author:** Dr. Aabha, Post graduate student, Department of Conservative Dentistry and Endodontics, Dr. Harvansh Singh Judge Institute of Dental Sciences, Panjab University, Chandigarh.

**This article may be cited as:** Aabha, Singla R, Kapoor V, Uppal AS. Endodontic management using Cone Beam Computed Tomography of maxillary molar having C-Shaped Anatomy: A Case Report. J Adv Med Dent Sci Res 2020;8(8):123-126.

#### INTRODUCTION

A C-shaped root canal for the first time was depicted in the transverse cross-sections of a molar of a Neanderthal individual.<sup>[1]</sup> But the first documentation of the C-shaped anatomy was done by Cooke in 1979.<sup>[2]</sup> Such canals are also referred to as gutter-shaped root canals. Generally speaking a C-shaped root canal is a canal which in transverse section resembles like the letter 'C'. However, these root canals are not always C-shaped extending from orifice to apical foramen. Therefore, a C-shaped root canal is described as a canal which resembles the shape of the English letter 'C' at any arbitrary level. However, the morphology of a C-shaped canal, at various levels cannot be estimated on the basis of shape of the canal orifice.<sup>[1]</sup> Melton and his co-workers in the year 1991, first classified the C-shape anatomy. Later based on their work, Fan introduced an anatomic classification<sup>[3]</sup>

1. Category I (C1) - continuous C-shaped root canal from the orifice to the apex of the root;
2. Category II (C2) -one main root canal and a smaller one;
3. Category III (C3) – two or three root canals;
4. Category IV (C4) - an oval or a round canal;

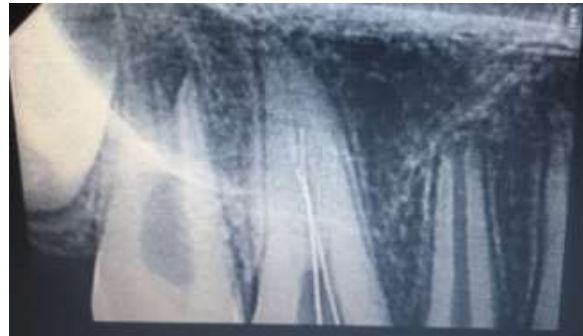The prevalence of a C-shaped canal in the maxillary molars is extremely rare. It is, according to De Moor, about 0.091% in the maxillary first molar.<sup>[4]</sup> The C-shape morphology is most prevalently seen in mandibular second molars.<sup>[5]</sup> The complexity of C-shaped anatomy poses difficulties in its diagnosis, shaping, cleaning and obturation. The proper diagnosis will build the basis of effective endodontic treatment.<sup>[6]</sup> The role of Cone Beam Computed Tomography in diagnosing the internal anatomy of the tooth is well established and documented. The superiority of the technique is because it is a 3 dimensional imaging modality which is not confounded by several factors that decrease the image quality as in the conventional radiographic technique. The two most important factors which cause a lower quality image, thereby decreasing the diagnostic importance of conventional radiography are the compression of a 3 dimensional structure onto a 2 dimensional film and superimposition of surrounding anatomic structures on the structure of interest.<sup>[7]</sup> This article highlights the importance of the use of CBCT in diagnosis and treatment planning and treatment execution of C shape canal in maxillary first molar.

## CASE REPORT

A 13 year old female patient reported to The Department of Conservative Dentistry and Endodontics at Dr. Harvansh Singh Judge Institute Of Dental Sciences and Hospital, Panjab University, Chandigarh. The chief complaint of the patient was pain on having hot food and drinks which was aggravated during the night time while lying down on the bed. The patient had a history of pain for the past 1 month but increased in intensity over the past 2 weeks which lead to her visit to the hospital. The mother of the patient expressed concern about the impaired sleep cycle of the patient due to the pain and wanted to begin with the treatment as soon as possible. On an intraoral examination, it was noted that the tooth number 16 (right maxillary molar) had extensive occlusal caries. The tooth was not tender to percussion and had normal mobility. The gingiva surrounding the tooth had normal probing depth. There were no associated signs of swelling and the patient also did not give a history of previous swelling or the development of a sinus tract. An IOPA radiograph was advised. The periapical radiograph revealed occlusal caries which involved the enamel and dentin to approach the pulp chamber. Although the pulp chamber was clearly visible, the root canal anatomy was not very clear. The periapex was however normal. A diagnosis of irreversible pulpitis was made for the patient. An access opening was done on this very visit to relieve the symptoms of the patient. Two prominent orifices we located, one buccal and one palatal. During the next visit, the chamber floor was extensively explored and a third (disto-buccal) orifice was found. While determining the working length, radiographically, it was difficult to assess the location and shape of the root canals as all files seemed to be entering one canal despite being introduced from different orifice [figure 1]. Due to many failed attempts to decipher the root canal anatomy via IOPA radiographs, a CBCT scan was advised to the patient.

The scan revealed that the tooth had 2 roots, one buccal, one palatal and three orifices i.e. mesio-buccal, disto-buccal and palatal. C-shape anatomy was observed between the mesio-buccal and disto-buccal canal. However, the two canals exited from different foramina at the apex. The tooth was diagnosed to have a C2 type of canal anatomy [figure 2]. In the patient's third visit, working length was taken using an electronic apex locator (E-pex pro, Orikam Healthcare India). The mesio-buccal and disto-buccal canals were shaped to 25 (4%) using NeoEndo flex file sytem (Orikam Healthcare India), while the palatal canal was filed till 40 (4%) file. Irrigation was done using 3% sodium hypochlorite (Prime Dental Products, India) which was activated using Manual Dynamic Irrigation Technique using frequency of 100 strokes/min. after every filing. The fourth visit was scheduled after 2 days during which the root canals were obturated. The sealer used was

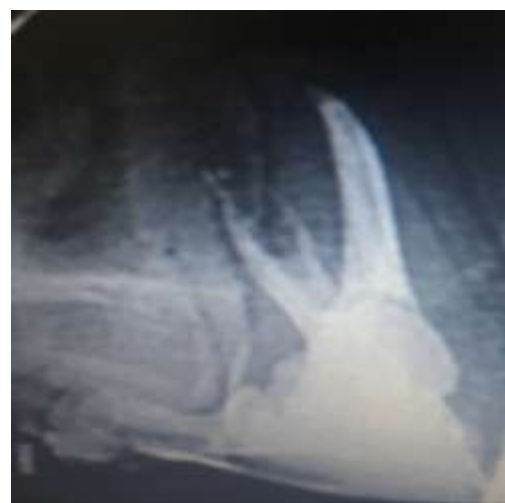Sealapex (Kerr, Orange, California, USA).A temporary restoration was given. A post obturation radiograph, [figure 3] and a second CBCT scan were done to verify the obturation. The CBCT scan and the radiograph revealed satisfactory obturation of all the 3 canals including the communication present between the mesio-buccal and the disto-buccal canal. Transverse sections [figures 4a, 4b, 4c, 4d] and axial sections [figures 5a, 5b, 5c] of the CBCT scan show adequate fill. A permanent composite was done soon after. And the patient was called after 1 week and was found to be asymptomatic.



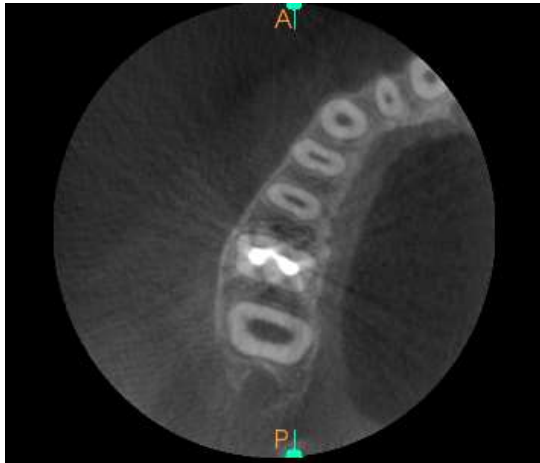
**FIGURE 1.** A digital periapical radiograph of tooth number 16. Showing an attempt in taking the working length of the tooth. The root canal anatomy is not very clear.



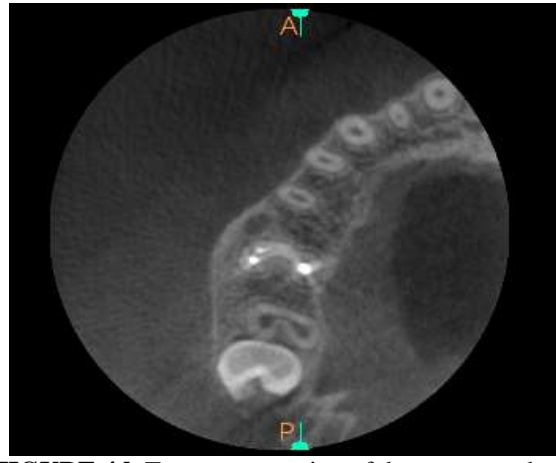
**FIGURE 2.** Axial sections of tooth 16, depicting the C2 internal morphology



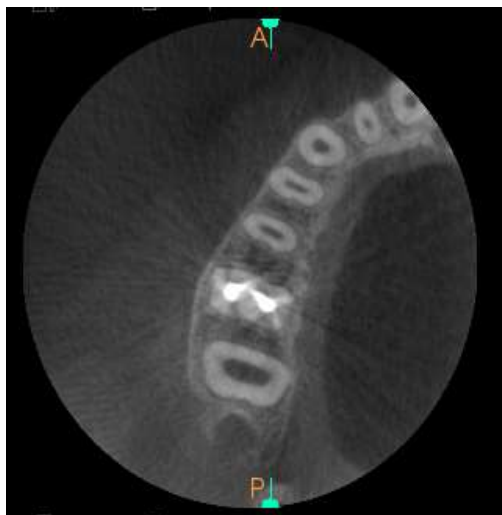
**FIGURE 3.** Digital periapical radiograph after obturation.



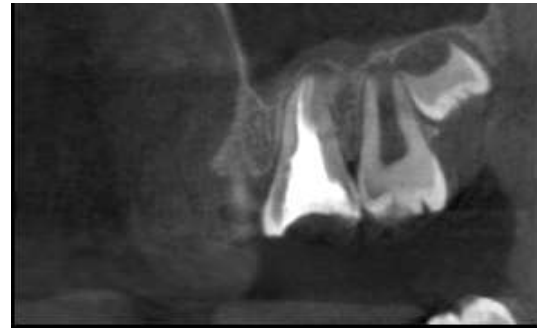**FIGURE 4a.** Transverse section of the root at the coronal third.



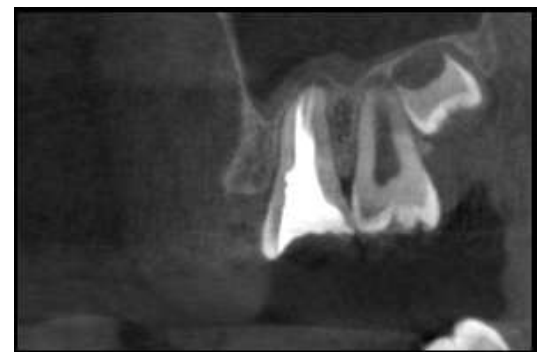
**FIGURE 4d.** Transverse section of the root near the apex showing different portals of exit for all the three canals.



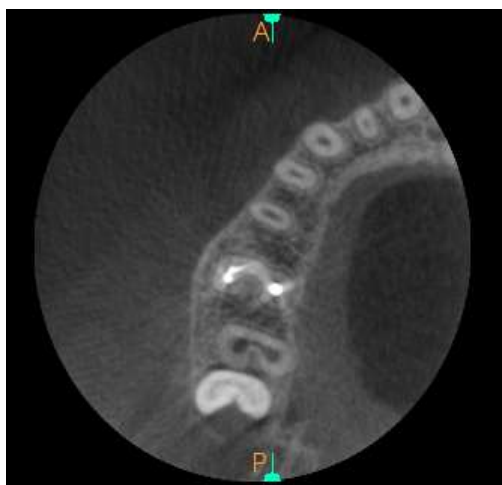
**FIGURE 4b.** Transverse section of the root at the middle third



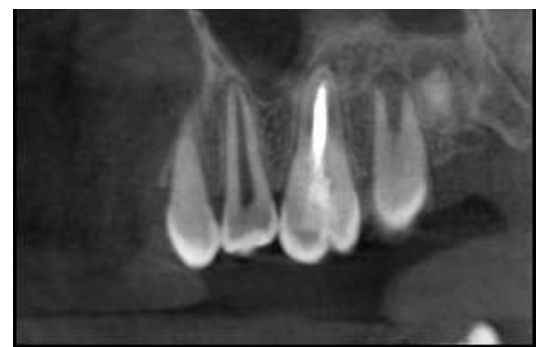**FIGURE 5a.** Axial section of the tooth showing mesio-buccal canal fill.



**FIGURE 5b.** Axial section showing both mesio-buccal and disto-buccal canal fill.



**FIGURE 4c.** Transverse section of the root at the apical third



**FIGURE 5c.** Axial section showing palatal canal fill.

## DISCUSSION

The conventional radiography technique is limited by several factors such as display of a three dimensional structure on to a two dimensional film, geometric distortion, anatomic noise and the inability to produce accurate and standardized radiographs and therefore three dimensional imaging is preferred.<sup>[8]</sup> Small volume CBCT is of greater importance to endodontics. The scan time is also comparable to panoramic imaging.<sup>[9]</sup> Conventional radiography can reveal up to 55% of the root canal variations while in contrast, the CBCT technique can detect up to 93.3% of these variations, immensely contributing to the success of the endodontic treatment.<sup>[10]</sup>

In conclusion, we would like to impress upon everyone the importance of the use of CBCT for detection of aberrant root canal anatomy and also encourage everyone to not be hesitant in taking this approach to imaging for endodontic diagnosis. Having said that, we also would like to emphasize the importance of using CBCT according to the regional guidelines to prevent any unnecessary exposure to the patient.

## REFERENCES

1. Kato A, Ziegler A, Higuchi N, Nakata K, Nakamura H, Ohno N. Aetiology, incidence and morphology of the C-shaped root canal system and its impact on clinical endodontics. *International endodontic journal*. 2014 Nov;47(11):1012-33.
2. Raisingani D, Gupta S, Mital P, Khullar P. Anatomic and diagnostic challenges of C-shaped root canal system. *International journal of clinical pediatric dentistry*. 2014 Jan;7(1):35.
3. Kirilova J, Topalova-Pirinska S. C-Shaped Configuration of the Root Canal System—Problems and Solutions. *Journal of IMAB—Annual Proceeding Scientific Papers*. 2014 Jun 20;20(1):504-9.
4. De Moor RJ. C-shaped root canal configuration in maxillary first molars. *International endodontic journal*. 2002 Feb;35(2):200-8.
5. Melton DC, Krell KV, Fuller MW. Anatomical and histological features of C-shaped canals in mandibular second molars. *Journal of Endodontics*. 1991 Aug 1;17(8):384-8.
6. Sinanoglu A, Helvacioğlu-Yigit D. Analysis of C-shaped canals by panoramic radiography and cone-beam computed tomography: root-type specificity by longitudinal distribution. *Journal of endodontics*. 2014 Jul 1;40(7):917-21.
7. Sharma S, Sharma V, Grover S, Mittal M. CBCT diagnosis and endodontic management of a maxillary first molar with unusual anatomy of two palatal canals: A case report. *Journal of conservative dentistry: JCD*. 2014 Jul;17(4):396.
8. Patel S, Dawood A, Whaites E, Pitt Ford T. New dimensions in endodontic imaging: part 1. Conventional and alternative radiographic systems. *International endodontic journal*. 2009 Jun;42(6):447-62.
9. Durack C, Patel S. Cone beam computed tomography in endodontics. *Brazilian dental journal*. 2012;23(3):179-91.
10. Kiarudi AH, Eghbal MJ, Safi Y, Aghdasi MM, Fazlyab M. The applications of cone-beam computed tomography in endodontics: a review of literature. *Iranian endodontic journal*. 2015;10(1):16.