

Review Article

Self Customized Lingual Orthodontics- Simplified

CH. Sudheer Kumar¹, Abin Mohammed B.N², Preeti Singh³, Praveen Kalai⁴, Sharad Kumar Sinha⁵

¹Professor and Head, ^{2,3,4,5}Post graduate student, Department of Orthodontics, Triveni Institute Of Dental Science, Hospital and Research Center, Bodri Bilaspur (CG).

ABSTRACT:

On account of morphological variations of lingual dental surfaces, difficulty in direct vision, variation in labio lingual thickness etc, indirect bonding is pivotal for success in lingual orthodontics. There are various laboratory technique available for indirect positioning and bonding of lingual brackets. But all these are cost effective and require specialized laboratory equipments for fabrication. This article describes the guidelines of self customized laboratory procedure for making customized lingual transfer tray based on modification of hiro technique and Kommon base technique

Keywords- Lingual orthodontics, Hiro technique, Kommon base technique, Archwire template.

Received: 09 December 2018

Revised: 20 January 2019

Accepted: 22 January 2019

Corresponding author: Dr. Abin mohammed B.N, TC 67/3008(3), We One Nagar, Ambalathara Poonthura P.O , Thiruvananthapuram Kerala, Pin- 6950026

This article may be cited as: Kumar CS, BN Mohammed A, Singh P, Kalai P, Sinha SK. Self Customized Lingual Orthodontics- Simplified. J Adv Med Dent Scie Res 2019;7(2):107-110.

INTRODUCTION:

Lingual orthodontics started in 1970's when Fujita in Japan and Kurz in the USA used lingual brackets for the first time. It made a sensational debut as lingual brackets were invisible and the number of initiated cases increased exponentially. A few years later, the number of lingual orthodontic cases decreased greatly. The reason was very clear; most doctors could not achieve satisfactory results with lingual orthodontics. Following this, initial development and expansion of lingual orthodontics in the 1990s, interest, particularly in the United States, decreased, probably due to the poor results of completed cases.¹ As time passed and problem-solving associated with lingual orthodontics was improved, lingual orthodontics expanded around the world, specifically in European and Asiatic countries².

Today lingual orthodontics is no longer a technique for limited number of orthodontist.

The indirect bonding technique is pivotal for success in lingual orthodontics³ because of difficulty in direct vision, variation in the morphology of lingual surface of tooth, variation in labio-lingual thickness, transfer of labial and buccal torque on the lingual surface and smaller inter bracket system. There are different laboratory techniques available for indirect positioning and bonding of lingual brackets. The HIRO system is one of the most used and easy to perform.

Dr. Hiro developed at the beginning of 1990 a laboratory system and indirect bonding technique that was published in 1998 . The author described this technique as the Resin Core Indirect Bonding System (RCIBS). This technique had a great impact in the lingual orthodontic world and was called the HIRO System^{3,4}

This article describes the guidelines of self customized laboratory procedure for making customized lingual transfer tray based on modification of Hiro technique and Kommon base technique.

Laboratory procedures:

Impression

Detailed impression was made by alginate.

Study model

Impression was poured with hard plaster and study models were prepared. **Figure 1**

Kesling set up⁵

Setup model was done by sectioning the individual tooth and replacing them on the base to simulate the treatment result. The sectioned teeth were trimmed and to create a root shape simulating a complete tooth. **Figure 2**. This trimming helps in building the manual setup without any contact interference. If posterior teeth has no discrepancy

then no need for sectioning the posterior teeth, keep teeth in that particular occlusion for maintaining proper vertical height. If posterior teeth has discrepancy then articulate the model with proper vertical height.

Maintain tip and torque

Setting anterior teeth with proper tip and torque can be achieved with the help of “guiding templates,” which help in orienting teeth to the occlusal plane. It helps in building the manual setup to a prescribed value of individual tooth rather than depending on visual judgments.⁶ **figure 3 & figure 4.** Finally, all the teeth were waxed up from base to cervical margin and the wax flow onto the crown was removed. **Figure 5**

It is very important to clean up the lingual surface of teeth, as any residual wax would cause an error in customization.

Fabrication of archwire template:

Once the setup has been finished with wax, full dimension 0.018-0.025” stainless steel arch wire was used for fabrication of archwire template. To achieve the correct distance between lingual surface of the teeth and arch wire template, the right and left central incisor brackets were secured to archwire template with elastic module. Then right and left canine bracket were secured and archwire template was checked for close adaptation of lingual surface. First inset bend was given just distal to canine bracket and another small inset bend were given between premolar and molars on both side. **figure 6.** Avoid adding any undesired torque in the archwire template and must follow the lingual arch form.

Bracket placement:

The brackets must be positioned in the gingival or inferior third of the tooth. Secured the bracket in to the archwire template with elastic module starting from central incisor to 2nd premolar and it should passively sit on setup. Molar tubes were inserted in to the archwire template and the position of molar tubes were marked on the lingual surface of the teeth. **Figure 7.** After that Molar tubes were removed before the fabrication of guiding arm otherwise it will hindrance the removal of tubes.

Fabrication of guiding arm:

Distal arm of archwire template were fabricated in such a way that it should sit on occlusal surface of molars on both side. Then made a stop on occlusal surface of molars by acrylic resin on both side. These arms not only help in seating the Archwire reliably at desired position but also guide the operator to re-customize a debonded bracket. **Figure 8**

Customization:

Thin layer of cold mold seal was applied on labial and lingual surface of the teeth, and the setup was allowed to dry completely before customization. The Archwire was held at one end, and base of the brackets were coated with light cured composite adhesive (3M UNITEK TRANSBOND XT) **Figure 9** and seated properly with

the help of occlusal stop of guiding arm, and the composite pad was light cured.

Fabrication of individual transfer tray:

Individual transfer tray were made anteriorly by acrylic resin (**hiro technique**) and posteriorly by flowable composite (**kommonbase technique**⁷).

Anterior tray fabrication

Anteriorly, Acrylic resin of individual tray extended labially till 2-3mm from the gingival margin. **Figure 10.** After the polymerization, Arch wire template was carefully removed from the individual tray by removing the elastic module with the help of probe.

Posterior tray fabrication:

It was done by kommon base technique.

During anterior tray fabrication, 1st and 2nd premolar brackets were bonded on the lingual surface. Then 1st and 2nd molar tubes were bonded directly to lingual surface, where previously marked the position of molar tubes during bracket placement. Before light curing, extra composite present around the tubes were extended toward the surrounding surface with the help of applicator tip and light cured. Then flowable composite was placed close to the bracket base and extended to lingual surface and also 1-2m toward the occlusal surface premolars and molar and followed by light curing. **Figure11.** Then setup was placed in water for sufficient time to dissolve the separating medium and individual tray was carefully removed from the setup. The margin of individual trays were trimmed carefully and finished.

If possible, The composite pad base of the brackets are sandblasted to remove any impurities and create microetches to improve bond strength and kept ready for bonding. Just before bonding onto the dentition, the composite pad was cleaned with acetone to remove any residual sand particles on the etched surface

Bonding on to tooth surface:

Before bonding, teeth surfaces were cleaned and etchant was applied on lingual surface for 15 sec. **figure 12.** After rinsing and drying, thin coat of primer (3M UNITEK TRANSBOND) was applied to both lingual surface and bracket base and cured. Apply sufficient amount of composite (3M UNITEK TRANSBOND XT) on the bracket base and carefully placed on lingual surface of teeth with the help of individual transfer tray and light cured. **Figure 13.**

Removing the tray:

After bonding, individual tray carefully removed with the help of high speed airoter. **figure14**

Rebonding:

It is essential to preserve ideal archwire used for indirect bonding. Debonded brackets are sand blasted and secured on to ideal archwire with help of modules. The archwire with debonded brackets are re-oriented in the setup and new transfer tray is made. The remaining procedure is same.

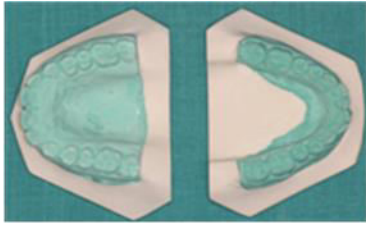


Figure 1



Figure 2

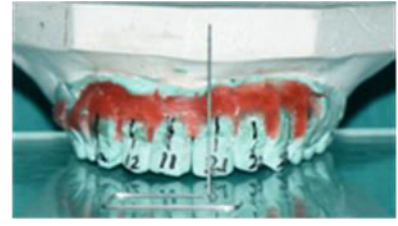

Figure 3

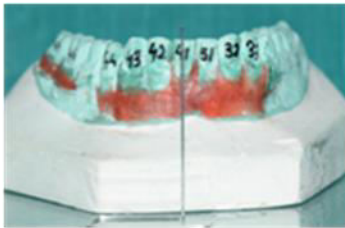


Figure 4

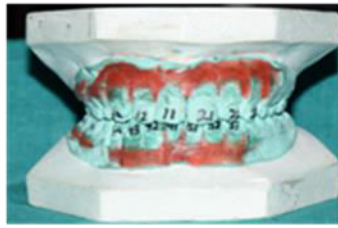

Figure 5

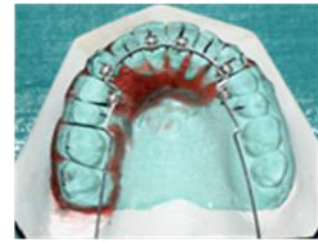


Figure 6

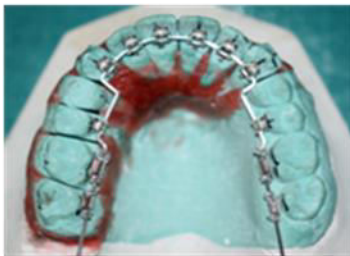

Figure 7

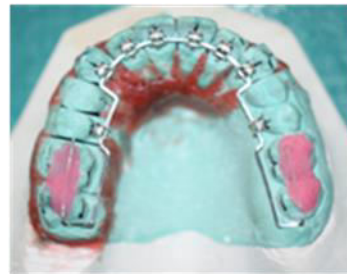

Figure 8



Figure 9

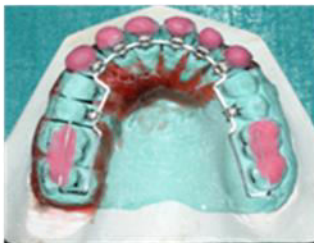

Figure 10

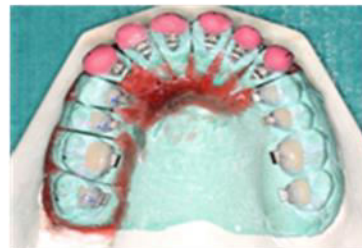

Figure 11

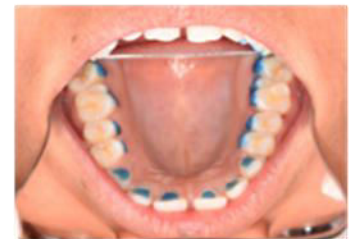

Figure 12

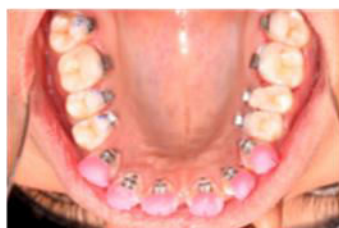

Figure 13

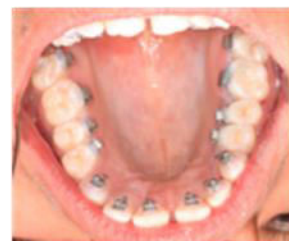

Figure 14

Figures: 1- study models; 2- sectioned individual teeth; 3 and 4- setting the tip of anterior teeth by using guiding template. Maxillary central incisor has 4 deg tip and mandibular central incisor has 0 deg. By using guiding template measure the tip with help of protractor; 5- after kesling setup; 6- Archwire template with inset bends on between canine and premolar region and between 2nd premolar and molar on both sides; 7- placement of brackets; 8- guiding arm with occlusal stops; 9- placing composite on bracket base; 10- anterior tray fabrication by acrylic resin; 11- posterior tray fabrication by flowable composite; 12- after etchant was applied; 13- after the individual tray placement; 14- after the removal of tray.

CONCLUSION

In lingual orthodontics, the indirect bonding system has been indispensable because of the morphological variation of lingual surface, difficulty in direct vision, variation in labio lingual thickness, transfer of labial and buccal torque on lingual and smaller inter bracket system. Previously, lingual bonding was confined only to limited number of orthodontists because of high cost and laboratory dependency.

The steps of hiro technique and kommon base technique have been modified in this article to simplify the laboratory process by using commonly used dental materials. Compared to other indirect techniques, the hiro system has several advantages; less expensive, no electronic equipment is required, provide accurate bonding, free from bonding failure and rebondable. With kommon base technique, as the bracket base is extended the large bonding base ensures high bonding strength and prevent bond failure.

REFERENCES

1. Echarri P. Revisiting the history of lingual orthodontics: A basis for the future. *Semin Orthod* 2006;12:153-9.
2. Saini P, Sharma H, Kalha AS, Chandna AK. The current evidence and implications of lingual orthodontics. *J Indian Orthod Soc* 2016;50:S4-9.
3. Hiro T, Iglesia FD, Andreu P. Indirect bonding technique in lingual orthodontics: The Hiro system. *Prog Orthod* 2008;9:34-45.
4. Hiro T, Takemoto K. Resin core indirect bonding system – Improvement of lingual orthodontic treatment. *Orthod Waves* 1998;57:83-91.
5. Kesling HD. The diagnostic set up with consideration of the third dimension. *Am J Orthod* 1956;42:740-8.
6. Das SK. Simplified manual setup and customization by resin core indirect bonding technique: Lingual orthodontics on your own. *J Indian Orthod Soc* 2016;50:S23-32.
7. Komori A, Fujisawa M, Iguchi S. KommonBase for precise direct bonding of lingual orthodontic brackets. *Int Orthod* 2010;8:14-27.