

## Original Article

### Clinicopathological Analysis of Salivary Gland Tumours - A Retrospective Study

Archana Kumari<sup>1</sup>, Sonali Roy<sup>2</sup>, Aparna Pathak<sup>3</sup>

<sup>1,2</sup>Senior Resident (Dental) Nalanda Medical College and Hospital, Patna, Bihar, India, <sup>3</sup>MDS, Oral Pathology

#### ABSTRACT:

**Background:** Salivary gland tumours are rare neoplasm. The present study was conducted to assess salivary glands lesions histopathologically. **Materials & Methods:** The present study comprised of 112 salivary gland lesions seen in both genders. General information such as age, sex, anatomical location etc. was recorded. **Results:** Out of 112 cases, 50 were seen in males and 62 in females. Parotid gland involvement was seen in 70 cases, submandibular gland in 30 and minor salivary gland in 12. The difference was significant ( $p < 0.05$ ). The most commonly seen parotid tumor was pleomorphic adenoma seen in 44 cases followed by Warthin tumors in 11 cases in submandibular gland and cysts in 5 cases of minor salivary gland. **Conclusion:** Most commonly lesions were seen in parotid gland and most common lesion was pleomorphic adenoma and there was female predominance.

**Key words:** Pleomorphic adenoma, Salivary gland tumors, Warthin tumors

Received: 2 November 2018

Revised: 24 December 2018

Accepted: 28 December 2018

**Corresponding Author:** Dr. Archana Kumari, Senior Resident (Dental) Nalanda Medical College and Hospital, Patna, Bihar, India

**This article may be cited as:** Kumari A, Roy S, Pathak A. Clinicopathological Analysis of Salivary Gland Tumours - A Retrospective Study. *J Adv Med Dent Scie Res* 2019;7(1):113-116.

#### INTRODUCTION

Salivary gland tumours are rare neoplasm with annual incidence ranging from 0.4 to 6.5 cases per lakh population. It accounts to less than 2-6.5% of all neoplasms of head and neck. More than forty five types of primary neoplasm are described in salivary gland owing to their varied histopathology despite their low incidence.<sup>1</sup>

Salivary glands tumors can demonstrate a striking scope of morphological assorted variety between various tumor types and here and there inside an individual tumor mass. Also, hybrid tumors, de-differentiation and the affinity for some benign tumors to advance to danger can bewilder histopathological translation. Around 80% of the salivary gland tumors are found in the parotid organ, 10-15% in the submandibular organ.<sup>2</sup>

Tumours of salivary glands have continuously interested medical profession, pathologists in particular because of a number of peculiarities of the subject. Approximately 80% of the salivary gland tumors are found in the parotid gland and 10 to 15% in the submandibular gland. Majority of Salivary gland tumours are of benign histology (80-85%),

with pleomorphic adenoma being the most common, constituting 70% of benign tumours.<sup>3</sup> The probability of malignancy is relatively inversely proportional to the size of the gland. Overall, benign tumours of the salivary glands tend to present somewhat earlier than malignant ones. The etiology, prognostic factors and risk factors are poorly defined. Many of these lesions behave in an indolent fashion and some of the histologic types tend to recur late.<sup>4</sup> The present study was conducted to assess salivary glands lesions histopathologically.

#### MATERIALS & METHODS

The present retrospective study was conducted in the 112 salivary gland lesions seen in both genders recorded in 1 year. The study protocol was approved from institutional ethical committee. All participants were informed regarding the study and written consent was obtained.

General information such as age, sex, anatomical location etc. was recorded. Results thus obtained were subjected to statistical analysis. P value  $< 0.05$  was considered significant.

**RESULTS**

**Table I Distribution of cases**

Total- 112		
Gender	Males	Females
Number	50	62

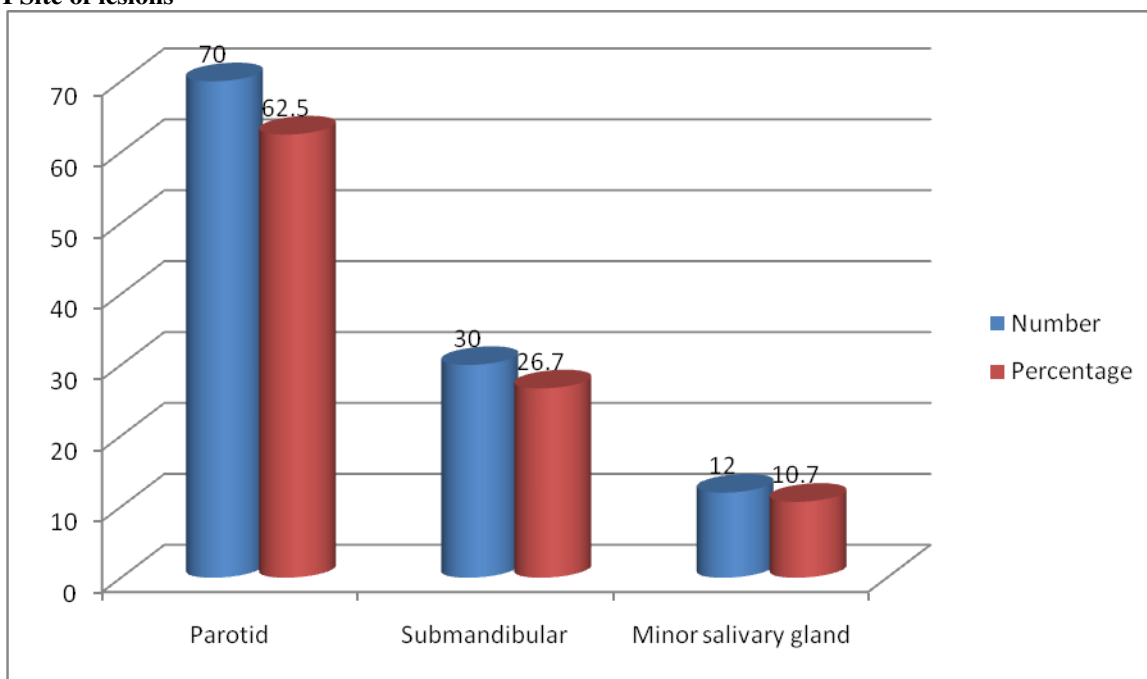
Table I shows that out of 112 cases, 50 were seen in males and 62 in females.

**Table II Site of lesions**

Site	Number	Percentage	P value
Parotid	70	62.5	0.01
Submandibular	30	26.7	
Minor salivary gland	12	10.7	

Table II, graph I shows that parotid gland involvement was seen in 70 cases, submandibular gland in 30 and minor salivary gland in 12. The difference was significant ( $p < 0.05$ ).

**Graph I Site of lesions**

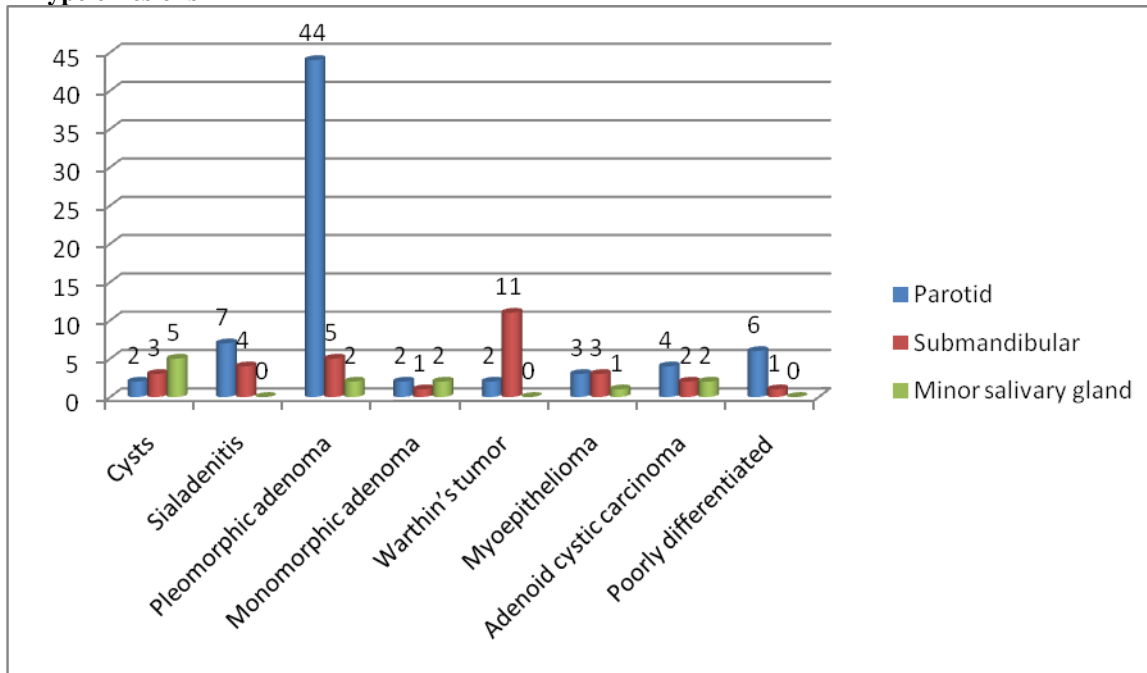


**Table III Type of lesions**

Lesion	Parotid	Submandibular	Minor salivary gland
Cysts	2	3	5
Sialadenitis	7	4	0
Pleomorphic adenoma	44	5	2
Monomorphic adenoma	2	1	2
Warthin's tumor	2	11	0
Myoepithelioma	3	3	1
Adenoid cystic carcinoma	4	2	2
Poorly differentiated	6	1	0
Total	70	30	12

Table III, graph II shows that most commonly seen parotid tumor was pleomorphic adenoma seen in 44 cases followed by Warthin tumors in 11 cases in submandibular gland and cysts in 5 cases of minor salivary gland.

**Graph II Type of lesions**



**DISCUSSION**

The salivary gland disorders represent a distinct group of disorders affecting both the major and minor glands. These conditions range from inflammatory disorders of infectious, granulomatous, auto immune etiology to obstructive, developmental, idiopathic disorders and neoplasm.

The majority of salivary gland tumors (80-85%) are of considerate histology, with pleomorphic adenoma being the most common, constituting 70% of benign tumors. Peak incidence of most of the benign tumours is in the fourth and the fifth decade and malignant is in the sixth and the seventh decade.<sup>5</sup> More women than men are affected by benign salivary gland tumour. But, malignant tumours are equally divided between the sexes. 4 80% of parotid gland tumours are benign and 82% of minor salivary gland tumours were malignant. Causation of salivary gland tumour is probably multifactorial. Epidemiological study has shown an increased incidence of salivary gland tumour following radiation exposure and patient treated with I<sup>131</sup> for the treatment of thyroid disease.<sup>6</sup> The present study was conducted to assess salivary glands lesions histopathologically.

In present study, out of 112 cases, 50 were seen in males and 62 in females. Parotid gland involvement was seen in 70 cases, submandibular gland in 30 and minor salivary gland in 12.

Nepal et al<sup>7</sup> found that out of 90 cases, 55 (61 %) were benign and 35 (39 %) were malignant. M: F proportion of 1.5:1. The mean age watched was 39.6 years with age scope of 18 to 70 years. Pleomorphic adenoma was observed to be the commonest benign tumor, trailed by Warthin tumor. The mucoepidermoid carcinoma was the

most widely recognized malignant tumor, trailed by adenoid cystic carcinoma. Parotid was the most well-known site for the area of tumors (68%) trailed by submandibular (17%) and minor salivary organs (15 %). Ali et al<sup>8</sup> found that out of 60 cases, 58 were epithelial tumours and two were non-epithelial tumours. Overall, 63.3% of cases in the study were female and 36.7% were male. Out of 60 cases, 34 were benign, 26 were malignant. 73.3% of tumours arise from major salivary gland and 26.6% were found in minor salivary gland. Eleven out of 26 cases of malignant tumours were found in major glands, 15 out of 26 cases were found in minor salivary gland. Out of 60 tumours, 32 arises from parotid, 12 cases from submandibular gland and remaining were from minor salivary gland. Pleomorphic adenoma was the commonest benign tumour forming 28 cases out of 60. Adenoid cystic carcinoma was the commonest malignant tumour forming 12 cases out of 60 cases.

Solange et al<sup>9</sup> found that out of total 53 cases, 41(77.35%) were neoplastic and 12(22.64%) were non neoplastic. Predominance of females was observed with M: F ratio of 0.8:1. The mean age observed was 46.7 years with age range of 12 to 75 years. Benign tumors outnumbered the malignant ones. Parotid was the most common site for the location of tumors (73.5%) and Pleomorphic adenoma was the commonest salivary gland tumor observed in both sexes. Muco-epidermoid carcinoma was the most common among the malignant salivary gland tumors followed by adenoid cystic carcinoma.

## CONCLUSION

Most commonly lesions were seen in parotid gland and most common lesion was pleomorphic adenoma and there was female predominance.

## REFERENCES

1. Stanley MW, Bardales RH, Farmer CE, *et al.* Primary and metastatic high-grade carcinomas of the salivary glands: A cytologic-histologic correlation study of twenty cases, *Diagnostic Cytopathology*. 1995; 13(1):37-43.
2. Edda vahahula AM. Salivary Gland tumors in Uganda: Clinical Pathological Study. *African health sciences*. 2004; 4(1):15-23.
3. Qizilbash AH, Sianos J, Young JEM, Archibald SD. Fine needle aspiration biopsy cytology of major salivary glands, *Acta Cytologica*. 1985; 29(4):503-512.
4. Nguansangiam S, Jesdapatarakul S, Dhanarak N, Sosrisakorn K. Accuracy of fine needle aspiration cytology of salivary gland lesions: routine diagnostic experience in Bangkok, Thailand, *Asian Pacific Journal of Cancer Prevention*. 2012; 13(4):1583-1588.
5. Barnes L, Everson JW, Reuichart P, Sidrawsky D. WHO classification of tumours. *Pathology and Genetics of Head and Neck Tumours*. 2005; 9:209-81.
6. Spiro JD, Spiro RH. Salivary tumors. In: Shah JP, Decker SB, editors. *Cancer of the Head and Neck*. Hamilton: Decker BC Inc. 2001, 240-50.
7. Nepal A, Chettri ST, Joshi RR, Bhattarai M, Ghimire A, Karki S. Primary salivary gland tumors in eastern Nepal tertiary care hospital. *J Nepal Health Res Counc*. 2010; 8:31-4.
8. Ali NS, Nawaz A, Rajput S, Ikram M. Parotidectomy: A review of 112 patients treated at a teaching hospital in Pakistan. *Asian Pac J Cancer Prev*. 2010; 11:1111-3.
9. Solange SL, Andrea FS, Rivadaxia FB, Roseana DA. Epidemiologic profile of salivary gland neoplasms: analysis of 245 cases. *Rev Bras Otorhinolaryngo*. 2005; 71(3):335-340.

**Source of support:** Nil

**Conflict of interest:** None declared

This work is licensed under CC BY: *Creative Commons Attribution 3.0 License*.