

## Original Article

### Fine Needle Aspiration Cytology in Lymph Node Pathologies- A Clinical Study

Himanshu Chauhan

Department of Pathology, BIMR Hospital Gwalior, Madhya Pradesh, India

#### ABSTRACT:

**Background:** Lymphadenopathy or adenopathy is condition in which lymph nodes are abnormal in size, number, or consistency. The present study was conducted to assess the cases of lymphadenopathy using FNAC. **Materials & Methods:** The present study comprised of 135 patients of both genders with neck masses. All patients underwent both FNA and subsequently surgical excision of their neck masses. Smears were then prepared and stained with Pap method. Smears were studied under microscope by a single pathologist to reach the diagnosis. **Results:** Out of 135 cases, males were 75 and females were 60. The difference was non-significant (P= 0.1). Out of 135 cases, 110 were benign and 25 were malignant. In benign lesions, 60 were in males and 50 were in females and in malignant cases, 15 were in males and 10 were in females. The difference was significant (P= 0.01). Metastatic neoplasm was seen in 7 males and 4 females, Hodgkin's lymphoma in 5 males and 4 females and non-Hodgkin's lymphoma in 3 males and 2 females. The difference was non-significant (P> 0.05). **Conclusion:** Lymph node biopsy plays an important role in establishing the cause of lymphadenopathy. Most common cause was benign lesions.

**Key words:** Hodgkin's lymphoma, lymphadenopathy, Metastatic neoplasm

Received: 28 November 2017

Revised: 26 December 2017

Accepted: 28 December 2017

**Corresponding author:** Dr. Himanshu Chauhan, Department of Pathology, BIMR Hospital Gwalior, Madhya Pradesh, India, E mail: [him\\_himanshu11@yahoo.co.in](mailto:him_himanshu11@yahoo.co.in)

**This article may be cited as:** Chauhan H. Fine Needle Aspiration Cytology in Lymph Node Pathologies- A Clinical Study. J Adv Med Dent Sci Res 2018;6(2):104-106.

#### INTRODUCTION

Lymphadenopathy or adenopathy is condition in which lymph nodes are abnormal in size, number, or consistency. Lymphadenopathy may be classified by size, where lymphadenopathy in adults is often defined as a short axis of one or more lymph nodes is greater than 10mm. There can be localized lymphadenopathy due to localized spot of infection e.g., an infected spot on the scalp will cause lymph nodes in the neck on that same side to swell up. Generalized lymphadenopathy due to a systemic infection of the body e.g., influenza.<sup>1</sup>

The experiment of fine needle aspiration (FNA) developed gradually, until 1921, when Guthrie<sup>2</sup> tried to correlate FNA results with various disease processes. Easy accessibility of acquiring a sample for cytological or histological examination has made it an important component of practices of the pathologists. Fine needle aspiration cytology (FNAC) has been introduced in the laboratory diagnostics since last two or three decades.

Thus in case of lymphadenopathy, FNAC becomes mandatory in order to reach out the exact cause. The most of the diagnoses are reactive or non-specific inflammatory conditions, however a significant number of cases are composed of granulomatous inflammations, the most common cause is tuberculosis. Fine needle aspiration cytology (FNAC) is a part of initial management of patients presenting with neck masses using a 18 to 23 gauge needle. The main benefit of FNAC is to avoid the need for surgical biopsy, which requires local or general anesthesia, increased hospital stay and costs.<sup>3</sup> The present study was conducted to assess the cases of lymphadenopathy using FNAC.

#### MATERIALS & METHODS

The present study was conducted in the department of general pathology. It comprised of 135 patients of both genders with neck masses who visited the department. All were informed regarding the study and written consent was obtained. Ethical clearance was obtained prior to the study.

General information such as name, age, gender etc. was recorded. All patients underwent both FNA and subsequently surgical excision of their neck masses. Smears were then prepared and stained with Pap method. Smears were studied under microscope by a single pathologist to

reach the diagnosis. The cases were divided into benign and malignant. Nondiagnostic smears were discarded. Results thus obtained were subjected to statistical analysis using chi-square test. P value less than 0.05 was considered significant.

**RESULTS**

**Table I** Distribution of cases

Total- 135		
Males	Females	P value
75	60	0.1

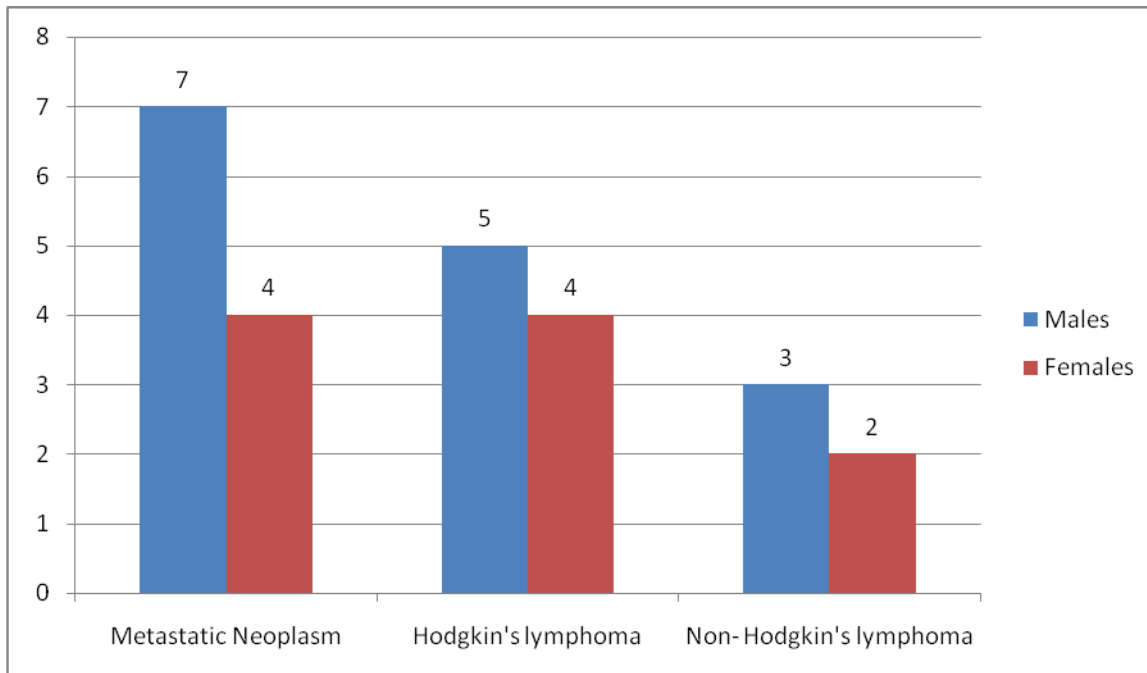
Table I shows that out of 135 cases, males were 75 and females were 60. The difference was non- significant (P- 0.1).

**Table II** FNAC results according to nature of lesion

Benign		Malignant		P value
Males	Females	Males	Females	
60	50	15	10	0.01
Total		Total		

Table II shows that out of 135 cases, 110 were benign and 25 were malignant. In benign lesions, 60 were in males and 50 were in females and in malignant cases, 15 were in males and 10 were in females. The difference was significant (P- 0.01).

**Graph I** Various FNAC lesions



Graph I shows that metastatic neoplasm was seen in 7 males and 4 females, hodgkin’s lymphoma in 5 males and 4 females and non- hodgkin’s lymphoma in 3 males and 2 females. The difference was non- significant (P> 0.05).

## DISCUSSION

Lymph node enlargement is recognized as a common sign of infectious, autoimmune, or malignant disease. It can be reactive in case of acute infection such as bacterial & viral. Cervical lymph nodes may be enlarged in cases of infectious mononucleosis which is an acute viral infection usually caused by Epstein-Barr virus. Fine-needle aspiration (FNA) is a diagnostic procedure used to investigate lumps or masses. In this technique, a thin, hollow needle is inserted into the mass for sampling of cells that after being stained is examined under a microscope. The sampling and biopsy considered together are called fine-needle aspiration cytology (FNAC). Fine-needle aspiration biopsies are very safe and minor surgical procedures.<sup>4</sup>

Out of 135 cases, 110 were benign and 25 were malignant. In benign lesions, 60 were in males and 50 were in females and in malignant cases, 15 were in males and 10 were in females. In a study by Abdul et al<sup>5</sup>, of the 289 lymph node biopsy specimens received, 154 (53.3%) were from males and 135 (46.7%) from females giving a male: female ratio of 1.14:1. Age of the patients ranged from 2.5 to 96 years with a mean age 33.9 years. The commonest lymph node group affected was the cervical (30.4%) followed by axillary (9.7%) and inguinal (8.7%). Malignant lymphoma [71 Hodgkin's disease (HD), 57 non Hodgkin's lymphoma (NHL)] 128 (44.3%), reactive hyperplasia 68 (23.5%), and tuberculosis 41 (14.2%) were the common causes of lymph node enlargement. While HD, reactive hyperplasia and tuberculosis were commonest in young adult patients and rare above the age of 50 years; NHL was the predominant cause of lymph node enlargement above 50 years.<sup>6</sup>

In a study by Mohammed<sup>7</sup>, reactive lymphadenitis, metastatic neoplasm, Hodgkin's lymphoma, and non-Hodgkin's lymphoma constituted 59.6%, 17.9%, 14.6% and 7.8% of total cases, respectively. In 27 cases (15.2%), the FNA findings were nondiagnostic. Diagnostic accuracy of FNAC was about 88%. Sensitivity, specificity, positive and negative predictive values were 75.8%, 96.6%, 94% and 85.1%, respectively. Our study revealed that metastatic neoplasm was seen in 7 males and 4 females, Hodgkin's lymphoma in 5 males and 4 females and non-Hodgkin's lymphoma in 3 males and 2 females.

A needle aspiration biopsy is safer and less traumatic than an open surgical biopsy, and significant complications are usually rare, depending on the body site. Common complications include bruising and soreness. There is a risk, because the biopsy is very small that the problematic cells will be missed, resulting in a false negative result. There is also a risk that the cells taken will not enable a definitive diagnosis. The most common symptom of Hodgkin's is the painless enlargement of one or more lymph nodes.

The nodes may also feel rubbery and swollen when examined.<sup>8</sup> The nodes of the neck and shoulders are most frequently involved. The lymph nodes of the chest are often affected, and these may be noticed on a radiograph. Classically, involved nodes are painful after alcohol consumption, though this phenomenon is very uncommon, occurring in only two to three percent of people with Hodgkin's lymphoma.

The signs and symptoms of non-Hodgkin's lymphoma vary depending upon its location within the body. Symptoms may include bone pain, chest pain, or itchiness and lymphadenopathy. Some forms are slow growing while others are fast growing. Enlarged lymph nodes may cause lumps to be felt under the skin when they are close to the surface of the body. Lymphomas in the skin may also result in lumps, which are commonly itchy, red or purple.<sup>9</sup>

## CONCLUSION

Lymph node biopsy plays an important role in establishing the cause of lymphadenopathy. Most common cause was benign lesions.

## REFERENCES

1. Cohen MB, Miller TR, Bottles K. Classics in cytology: note on fine needle aspiration of the lymphatic glands in sleeping sickness. *Acta Cytol* 1986;30(4):451-2.
2. Guthrie CG. Gland puncture as a diagnostic measure. *Johns Hopkins Bull* 1921;32:266-9.
3. Tandon S, Shahab R, Benton JI, Ghosh SK, Sheard J, Jones TM. Fine-needle aspiration cytology in a regional head and neck cancer center: comparison with a systematic review and meta-analysis. *Head Neck* 2008;30(9):1246-52.
4. Carroll CM, Nazeer U, Timon CI. The accuracy of fine-needle aspiration biopsy in the diagnosis of head and neck masses. *Ir J Med Sci* 1998;167(3):149-51.
5. Abdul, Bardales RH, Baker SJ, Mukunyadzi P. Fine-needle aspiration cytology findings in 214 cases of nonparotid lesions of the head. *Diagn Cytopathol* 2000;22(4):211-7.
6. Fulciniti F, Califano L, Zupi A, Vetrani A. Accuracy of fine needle aspiration biopsy in head and neck tumors. *J Oral Maxillofac Surg* 1997;55(10):1094-7.
7. Mohammed G, Koasri F, Alavi Tafreshi M. Fine needle aspiration cytology in diagnosis of nonthyroidal neck masses. *Acta medica Iranica* 2002;40(1):49-51.
8. Comeche C, Barona R, Navarro T, Armengot M, Basterra J. Verifiable diagnosis of the puncture of the fine needle aspiration in head and neck neoplasms. *Acta Otorrinolaringol Esp* 1993;44(5):381-4.
9. Mixon T, Gianoli G. Fine needle aspiration in head and neck surgery. *J La State Med Soc* 1993;145(12):505-8.

**Source of support:** Nil

**Conflict of interest:** None declared

This work is licensed under CC BY: **Creative Commons Attribution 3.0 License.**