

Case Report

Identification and Endodontic Management of Confluent Middle Mesial Canal in Mandibular First Molar: A Case Report

Brijesh Patel, Naveen Chhabra, Disha Jain

Department of Conservative Dentistry & Endodontics, K.M.Shah Dental College & Hospital, Sumandeep Vidyapeeth, Piparia, Vadodara, Gujarat, India, 391760,

Abstract:

Knowledge and understanding of the root canal anatomy is fundamental in achieving the successful endodontic treatment outcome. Occurrence of variations in root canal anatomy is common and frequency may vary according to population. This paper discusses a clinical report of root canal therapy in a permanent mandibular first molar and emphasizes the importance of magnification for the assessment, and acquaintance of the possible canal configuration, alongwith the management of middle mesial canal of permanent mandibular first molar.

Key Words: Anatomic variations, Mandibular molar, Middle mesial canal, Root canal therapy.

Corresponding Author: Dr. Brijesh Patel, Department of Conservative Dentistry & Endodontics, K.M. Shah Dental College & Hospital, Sumandeep Vidyapeeth, Piparia, Vadodara, Gujarat, India, 391760, E-mail: brij2110@gmail.com

This article may be cited as: Patel B, Chhabra N, Jain D. Identification and Endodontic Management of Confluent Middle Mesial Canal in Mandibular First Molar: A Case Report. J Adv Med Dent Scie Res 2015;3(1):156-159.

INTRODUCTION:

The prime goals of root canal treatment are thorough cleaning of the entire pulp space followed by complete obturation with inert material. Missed canals and spaces within the root canal system may contribute to failure of therapy as it contains microorganisms and their byproducts. A missed canal is neither debrided nor thoroughly sealed, and thus leading to the persistence of periapical inflammation. Hence, it is crucial that aberrant anatomy is identified before / during the root canal treatment.^[1]

The first documented presence of a middle mesial canal(MM) in a mandibular molar was by Vertucci and Williams in 1974.^[2] Since then multiple case of atypical canal morphology in the mesial root of mandibular molar have been reported.^[3-9] It has been postulated that secondary dentin apposition

during tooth maturation forms the dentinal vertical partition inside root canal cavity, resulting in various root canal configurations. Additional canals in the mesial root of mandibular molars have been reported in the literature and its incidence ranges from 2.07% to 13.3% of the examined cases.^[5,9] Pomeranz et al^[6] clinically evaluated 100 mandibular molar and found that twelve molars had medial mesial canals in their mesial roots and classified them into 3 morphologic categories: fin, confluent, and independent.

Incidence of dental caries is highest in the permanent mandibular first molar owing to its earliest eruption in the oral cavity and therefore, most often requiring the root canal treatment.^[10] This case report presents the clinical detection and management of middle mesial canal in permanent mandibular first molar.

CASE REPORT

A 28-year-old male patient reported to department of conservative dentistry and endodontics with a chief complaint of pain in left lower posterior region of the mouth since 10 days. The patient's medical history was non-contributory. Clinical examination showed the presence of faulty restoration and secondary caries around tooth 36. The tooth 36 was tender and there was no swelling / sinus opening present in the adjacent soft tissues. No periodontal pockets were detected. The tooth did not respond to electrical pulp testing (Gentle Plus; Parkellinc., USA). Radiographic examination revealed the presence of radiolucency in relation to distal root of tooth 36 suggestive of chronic periapical peridontitis, necessitating endodontic therapy for the same.

After obtaining the patient's consent, tooth was anesthetized using 2% Lignocaine with 1: 80,000 adrenaline (Lignox, Indoco Remedies Ltd, India) and isolated using rubber dam. All residual filling material and caries were removed and access cavity was prepared. Three root canal orifices were initially observed, including mesiobuccal (MB), mesiolingual (ML) and Distal. The working length was determined with an electronic apex locator (RootZX II; Morita, Japan). [Figure (a)]

The patency of the root canals were obtained using stainless steel no. 10 K-files (Mani inc., Japan) and cleaned and shaped using nickel-titanium rotary files (M-two, VDW, Germany). During instrumentation the canals were intermittently flushed with 5.25% sodium hypochlorite. During the course, a tiny orifice was detected between the MB and ML with an endodontic explorer DG-16 (Dentsply Maillefer, Ballaigues, Switzerland) under endodontic microscope 10X magnification (Labomed, India). The patency of the additional canal was confirmed using no. 15 K-file passing through the orifice. The existence of a middle mesial (MM) canal in a line was considered and later confirmed with the intraoral periapical radiograph (IOPA). The IOPA showed that the three mesial root canals were arrayed in a line (Figure 1a). The additional canal (MM) was cleaned and shaped using the same technique as the other canals (Figure 1b). All the canals were finally flushed with copious solution of 5.25% sodium hypochlorite followed by paper drying and placement of calcium hydroxide dressing (RC Cal, Prime Dental Products, India) in the root canals. Later the access cavity was temporized with Cavit (3M ESPE, USA) and the treatment was rescheduled after one week.

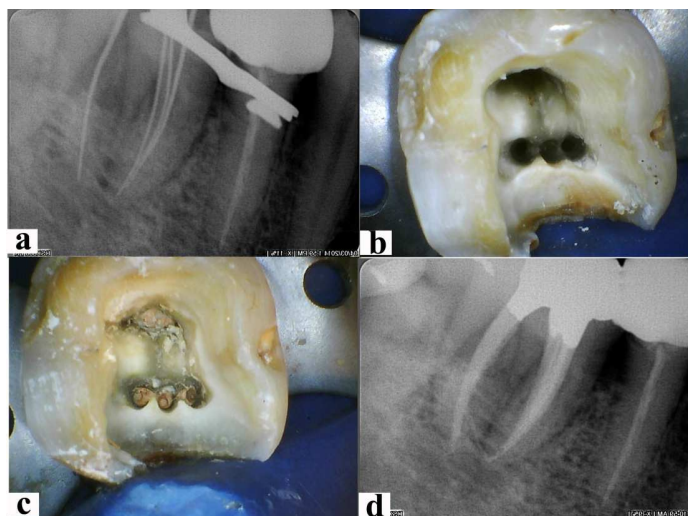


Figure 1: a) Working length IOPA radiograph showing the presence of middle mesial canal; b) Intraoral image showing the presence of middle mesial canal; c) satisfactorily obturated canals seen in the IOPA radiograph; d) clinical image showing obturated root canal orifices

In the next appointment the tooth was asymptomatic. The canals were rinsed using 5 ml of 5.25% sodium hypochlorite to remove the residual calcium hydroxide. Each canal was flushed with 2 ml of 17% EDTA solution to remove the smear layer. Thereafter the all the canals were dried using absorbent paper points and obturated using gutta-percha cone&resin based sealer (AH-Plus, Dentsply, India) using lateral condensation method (Figure 1c & 1d). Subsequently the access was restored with silver amalgam and referred to the Department of Prosthodontics for complete coverage crown prosthesis.

DISCUSSION

Sufficient literature supports the presence of three foramina in the mesial root of mandibular molars, however, only a few have reported the presence of three independent canals.^[11] In this case, middle mesial canal connected with mesiobuccal canal to end in common apical foramen. Also the literature shows that middle mesial canal joined to mesiobuccal or mesiolingual canal in most cases.^[12-13]

In the present case middle mesial canal was confluent where middle mesial canal originated as a separate orifice but apically joined the mesiobuccal or mesiolingual canal according to categories suggested by Pomeranz et al.^[6]

The clinician should precisely scrutinize the pulp chamber floor to trace possible canal orifices. Pulp chamber floor and wall anatomy present a guide to determine the root canal morphology. Krasner and Rankow^[14] made a sensible approach to examine the association of the pulp chamber to the clinical crown and the pulp chamber floor. Their interpretations, presented in the form of laws, are valuable aids to the clinician while searching for hidden canals.

A long shank round bur or an ultrasonic tip can be used for removal of any protuberance from the mesial axial wall, which would

block the direct access to the developmental groove between mesiobuccal and mesiolingual orifices. The sharp tip of an endodontic explorer should be used carefully to check for this developmental groove. If depression or orifices are located, the groove can be troughed with ultrasonic tip at its mesial aspect until a small file can negotiate this intermediate canal.^[15]

Radiographic examination using standard intraoral periapical views at different horizontal angulations is important for the evaluation of the canal configuration. Digital radiography at different angles with subsequent image analysis can be used effectively. Computed tomography (CT) imaging has been extensively used in medicine since many years and was introduced in the endodontics around 1990s.^[16] Cone beam CT (CBCT) imaging has been shown to provide similar images at low dose and costs to be considered as an alternative to multidetector CT imaging in endodontics. Clinical detection and management of an independent middle mesial canal in mandibular first molar by means of CBCT imaging has been suggested as well.^[17-18]

Other aids like dyes, champagne bubble test, micro openers, trans-illumination devices and observing the chamber for bleeding spots could be used as invaluable means to locate additional canal orifices. Dental operating microscope and loupes also provide magnification and illumination of the operating field and considerably enhance the visualization of root canal orifices.^[17]

The present report confirms the occurrence of third canal in the mesial root of mandibular first molar and suggests the careful exploration of the pulp chamber floor under high magnification. Any cervical stenosis present between two mesial canals of mandibular molar must be removed using burs or ultrasonic tips to explore hidden orifices.

REFERENCES

1. Vertucci FJ. Root canal anatomy of the human permanent teeth. *Oral Surg Oral Med Oral Pathol* 1984;58:589–99.
2. Vertucci FJ, Williams RG. Root canal anatomy of the mandibular first molar. *JNJ Dent Assoc* 1974;48:27–8.
3. Weine FS. Case report: three canals in the mesial root of a mandibular first molar. *J Endod* 1981;8:517–20.
4. Bond JL, Hartwell GR, Donnelly JC, et al. Clinical management of middle mesial root canals in mandibular molars. *J Endod* 1988;14:312–4.
5. Fabra-Campos H. Unusual root anatomy of mandibular first molars. *J Endod* 1985; 11:568–72.
6. Pomeranz HH, Eidelman DL, Goldberg MG. Treatment considerations of the middle mesial canal of mandibular first and second molars. *J Endod* 1981;7:565–8.
7. Min KS. Clinical management of a mandibular first molar with multiple mesial canals: a case report. *J Contemp Dent Pract* 2004;3:142–9.
8. Ricucci D. Three independent canals in the mesial root of a mandibular first molar. *Endod Dent Traumatol* 1997;13:47–9.
9. Goel NK, Gill KS, Taneja JR. Study of root canals configuration in mandibular first permanent molar. *J Indian Soc PedodPrev Dent* 1991;8:12–4.
10. Lu Q, Wang P, Yang B, Liu X, Wang SY, Yu Q. Endodontic Treatments of Mandibular First Molar with Middle Mesial Canal: Two Case Reports. *Chin J Dent Res* 2013;16:75-8.
11. Holtzmann L. Root canal treatment of a mandibular first molar with three mesial root canals. *IntEndod J* 1997;30:422–3.
12. Aminsobhani M, Bolhari B, Shokouhinejad N, et al. Mandibular first and second molars with three mesial canals: a case series. *Iran Endodont J* 2010;5:36–9.
13. Fabra-Campos H. Unusual root anatomy of mandibular first molars. *J Endod* 1985;11:568–72.
14. Krasner P, Rankow HJ. Anatomy of the pulp-chamber floor. *J Endod* 2004;30:5–16.
15. Vertucci FJ. Root canal morphology and its relationship to endodontic procedures. *Endod Topics* 2005;10:3–29.
16. Tachibana H, Matsumoto K. Applicability of X-ray computerized tomography in endodontics. *Endod Dent Traumatol* 1990;6:16–20.
17. Cotton TP, Geisler TM, Holden DT, Schwartz SA, Schindler WG. Endodontic application of cone-beam volumetric tomography. *J Endod* 2007;33:1121–32.
18. La SH, Jung DH, Kim EC, Min KS. Identification of Independent Middle Mesial Canal in Mandibular First Molar Using Cone-Beam Computed Tomography Imaging. *J Endod* 2010;36:542-5.

Source of funding: Nil

Conflict of interest: None declared