

Original Article

Assessment of the Diagnostic Significance of RBCs changes in various Stages of OSMF

Anuj Shrotriya¹, Akansha Shrotriya²

^{1,2}Department of Oral Pathology & Microbiology, Khajrana Dental Clinic & Implant Centre, Indore, M.P., India

ABSTRACT:

The present study was aimed to assess the diagnostic significance of RBCs changes in various stages of OSMF. Results showed that overall comparison of mean % of RBCs with shallow single (p=0.693), shallow multiple (p=0.521), deep single (p=0.236), deep multiple (p=0.426) central concavity and RBCs with absence of central concavity (p=0.194) across functional stages of OSMF cases was not statistically significant. Therefore, inter stage comparison was not applicable.

Key words: Diagnostic, RBC, OSMF & Assessment.

Received: 4 August 2018

Revised: 28 August 2018

Accepted: 29 August 2018

Correspondence to: Dr. Akansha Shrotriya, Department of Oral Pathology & Microbiology, Khajrana Dental Clinic & Implant Centre, Indore, M.P., India

This article may be cited as: Shrotriya A, Shrotriya A. Assessment of the Diagnostic Significance of RBCs changes in various Stages of OSMF. J Adv Med Dent Sci Res 2018;6(9):84-87.

INTRODUCTION

Areca nut being rich in polyphenols, can generate phenolic radicals via reaction with an oxidant. Also, arecoline, one of the major constituents of AN, have been shown to be capable of forming a conjugate with reduced glutathione, thereby diminishing cellular glutathione antioxidant reserves. Therefore, when constituents of AN enter into the circulation, an oxidative stress evoked effect on Red blood cells (RBC) membrane integrity can ensue.

RBC exposed to high concentration of AN causes concentration-dependent passive potassium leak and such damage is accompanied by the leakage of macromolecules such as haemoglobin. This phenomena is accompanied by a morphological alteration that resembled target-cell-like transformation in RBCs.

Therefore, it can be inferred that, human RBCs exposed to AN directly alter membrane structural integrity, including morphology, de-formability and membrane permeability.^{1&2}

MATERIALS & METHOD

The present study was carried out in the Department of Oral and Maxillofacial Pathology and Microbiology, Index

Institute of Dental Science, Indore after approval from Institutional ethical committee. The study comprised of blood samples collected from clinically confirmed 30 cases of OSMF which were equally divided into three groups as per the functional staging of **Haider SM et al (2000)** and six blood samples were collected from normal subjects.³

Subjects with bleeding and clotting disorders and with any other systemic illness were excluded. Six blood samples were taken from the normal individuals, who did not have any clinically detectable lesion and any abusive habit and were undergoing routine blood examination for minor dental procedures.

ARMAMENTARIUM

Glassware

- Micro slides - 75 mm×25mm×1.35mm (Blue star)

Instruments and Equipments

- Diamond glass cutter
- Disposable 2ml syringe (hi-tech)
- Anticoagulant EDTA vial

- Atomic Force Microscope (Digital instruments Nano Scope-E system, Tip- silicon nitride, available at UGC-DAE consortium for Scientific Research, Devi Ahilya University campus, Indore.)

Software

WSxM [Windows Scanning X (Force, Tunneling, Near Optical) Microscope] version-5.0 develop 7.0, for Data Acquisition and Processing in Scanning Probe Microscopy (SPM).

PROCEDURE

Blood samples from subjects were collected in vials containing anticoagulant EDTA. Immediately thin blood film was drawn by taking small drop of blood on glass slides and air dried. The glass slides was broken into 8mm×8mm pieces by diamond glass cutter. A piece from the tail portion having uniform and thin spread was selected and observed under the atomic force microscope with standard top view. Both AFM and LFM (Lateral force microscopy) images were captured simultaneously in real time. LFM images were obtained by taking into account the horizontal component of the force revealing surface roughness. The acquired images were processed using appropriate software.

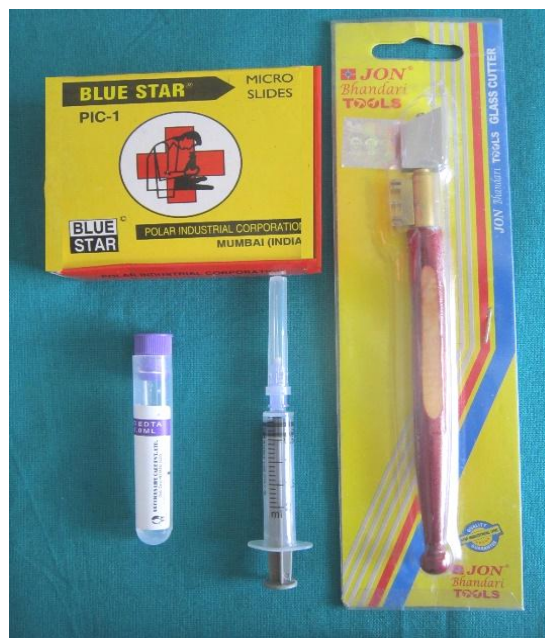

Fig 1: Photograph of glass slides, diamond glass cutter, EDTA vial and syringe used in study.

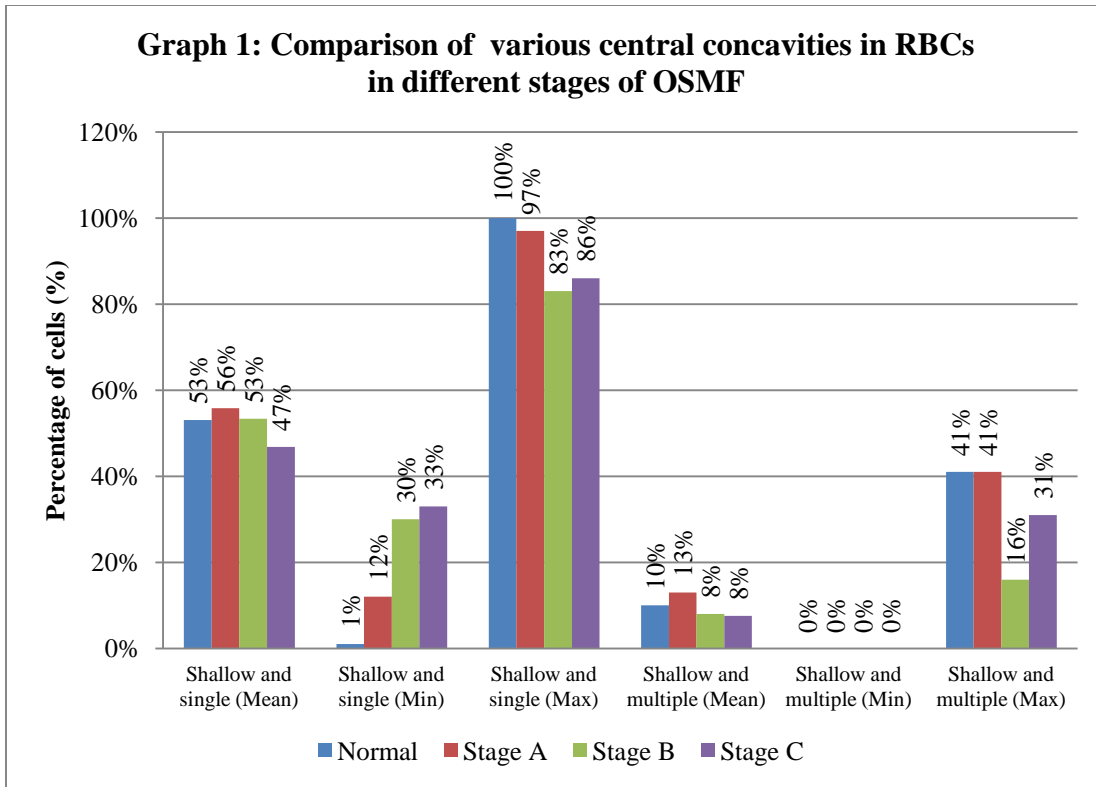
RESULTS

Table 1: Comparison of presence or absence of central concavity in RBCs between three Stages (A, B, C) of OSMF

Groups according to functional stages of OSMF	Central concavity present					Central concavity absent Flat top cell (%)
	Shallow		Deep			
	Single (%)	Multiple (%)	Single (%)	Multiple (%)		
Stage A (n=10)	Mean %	56	13	24	0	7
	SD±	26	15	21	0	6
	Minimum	12	0	0	0	0
	Maximum	97	41	71	0	18
Stage B (n=10)	Mean%	53	8	29	2	8
	SD ±	17	5	21	5	8
	Minimum	30	0	0	0	0
	Maximum	83	16	63	17	25
Stage C (n=10)	Mean%	47	8	36	1	8
	SD ±	16	10	16	2	10
	Minimum	33	0	0	0	0
	Maximum	86	31	53	7	25
Overall Comparison: chi-square value, p-value, significance	0.895, 0.693, NS	1.304, 0.521, NS	2.884, 0.236, NS	2.008, 0.366, NS	0.149, 0.928, NS	
Stage A vs B (z, p-value, sig)	NA	NA	NA	NA	NA	
Stage A vs C (z, p-value, sig)	NA	NA	NA	NA	NA	
Stage B vs C (z, p-value, sig)	NA	NA	NA	NA	NA	

NS- Not significant

NA-Not applicable



Overall comparison analyzed by Kruskal-Wallis test, stage wise comparison by Mann-Whitney test.

In the above table, comparison of mean percentage of RBCs for presence or absence of central concavity was done in between different stages of OSMF. In case of presence of central concavity, comparison of mean % of cells having shallow single, shallow multiple, deep single, deep multiple was done in between different stages of OSMF.

The mean % of RBCs with single shallow central concavity in Stage A, B and C were 56±26 with min 12 & max 97, 53±17 with min 30 & 83 and 47±16 with min 33 & 86 respectively.

The mean % of RBCs with multiple shallow central concavities in Stage A, B and C were 13±15 with min 0 & max 41, 8±5 with min 0 & max 16 and 8±10 with min 0 & max 31 respectively.

The mean % of RBCs with single deep central concavity in Stage A, B and C were 24±21 with min 0 & max 71, 29±21 with min 0 & max 63 and 36±16 with min 0 & max 25 respectively.

The mean % of RBCs with multiple deep central concavities in Stage A, B and C were 0±0, 2±5 with min 0 & max 17 and 1±2 with min 0 & max 7 respectively.

The mean % of RBCs without central concavity (flat top cells) in Stage A, B and C were 7±6 with min 0 & max 18, 8±8 with min 0 & max 25 and 8±10 with min 0 & max 25 respectively.

Overall comparison of mean % of RBCs with shallow single (p=0.693), shallow multiple (p =0.521), deep single (p=0.236), deep multiple (p=0.426) central concavity and RBCs with absence of central concavity (p=0.194) across functional stages of OSMF cases was not statistically significant. Therefore, inter stage comparison was not applicable.

DISCUSSION

Kolhe AS et al (2009) demonstrated cytotoxic morphological aberration concentration dependent swelling of RBC as concentration dependent swelling of RBC by various concentration of areca nut and tobacco.⁴ As, tobacco can also cause cytotoxic changes in RBC, it is difficult to state that morphological changes observed in the present study were only due to AN.

The present study was undertaken to examine RBCs, as they contain a well-developed membrane skeleton network, and their membrane skeleton is biochemically better characterized than those of other cells. AFM, has provided a range of new opportunities for viewing positions, shapes and sizes of particulate components over the entire surface of RBCs at high resolution up to nanometers with minimum or no sample preparation. Structures near the plasma membrane, such as membrane skeleton can be visualized on the extracellular surface of the plasma membrane by AFM. Therefore, the present study was designed to evaluate RBCs by AFM.

It is documented that the true image of the cell surface could be observed only in the middle part of the cell. Therefore, in our study we had measured the RBCs dimensions from the center of the cell.^{5&6}

Till today, no such study was performed in OSMF to evaluate cytotoxic changes in RBCs due to AN consumption.

Our study consisted of 6 normal subjects and 30 OSMF subjects. Though various classifications are being proposed for OSMF, in the present study functional staging of OSMF by **Haider SM et al (2000)** was considered because of its easy applicability which clinically classifies OSMF into 3 stages depending on the inter incisal mouth opening as - **Stage A:** mouth opening ≥ 20 mm, **Stage B:** mouth opening 11-19mm and **Stage C:** mouth opening < 10 mm.³

CONCLUSION

Overall comparison of mean % of RBCs with shallow single ($p=0.693$), shallow multiple ($p=0.521$), deep single ($p=0.236$), deep multiple ($p=0.426$) central concavity and RBCs with absence of central concavity ($p=0.194$) across functional stages of OSMF cases was not statistically significant. Therefore, inter stage comparison was not applicable.

REFERENCES

1. Peng KP, Chiou JF, Chen YT, Liu TZ. Is the blood donated by habitual nut quid chewers suitable for use in transfusion? J Formos Med Assoc. 2010; 109(2):106-12.
2. Lync S. Indicators of the iron status of populations: RBC parameters. Annex 1. www.who.int/nutrition/publications.
3. Haider SM, Merchant AT, Fikre FF, Rahbart MH. Clinical and functional staging of oral submucous fibrosis. British Journal of Oral and Maxillofacial Surgery. 2000; 38:12-15.
4. Kolhe AS, Patil N. Cytotoxicity of aqueous extract of areca nut and tobacco on human erythrocytes (Red Blood Corpuscles). International Research Journal. 2009; II(5):539-540.
5. Nowakowski R, Luckham P. Imaging the surface details of RBCs with atomic force microscopy. Surface and Interface Analysis. 2002; 33:118-121.
6. Hekele O, Goesseisberger CG, Gebeshuber IC. Nanodiagnostics performed on human RBCs with atomic force microscopy. Materials Science and Technology, 2008; 24(9):1162-1165.

Source of support: Nil

Conflict of interest: None declared

This work is licensed under CC BY: **Creative Commons Attribution 3.0 License.**