

Journal of Advanced Medical and Dental Sciences Research

@Society of Scientific Research and Studies

Journal home page: www.jamdsr.com

doi: 10.21276/jamdsr

ICV 2018= 82.06

(e) ISSN Online: 2321-9599;

(p) ISSN Print: 2348-6805

Original Research

Evaluation of Existing Radiographic Prescription Tendencies in Planning Dental Implant Therapy: A Survey Based Original Study

Rohit Singh¹, Supriya Singh², Aaysha Tabinda Nabi³, Irfanul Huda⁴, D K Singh⁵

¹Senior lecturer, Department of Prosthodontics, Patna Dental College and Hospital Patna;

²Private Practitioner, Department of Oral Medicine and Radiology;

³Reader, Department of Periodontology, Buddha Institute of Dental Sciences and Hospital, Patna;

⁴Reader, Department of Prosthodontics, Patna Dental College and Hospital Patna;

⁵Professor and Head, Department of Prosthodontics, Patna Dental College and Hospital Patna

ABSTRACT:

Background: Since a long time; dental radiology has played an exciting and basic demonstrative part in dentistry. This has been never more genuine than now with the quickly growing cluster of imaging modalities. Radiography offers the sole strategy for investigation of bone required for implant treatment. The prime aim of this paper is to study the current radiographic prescriptions in dental implant therapy among dental practitioners in Northern Indian region. **Materials and Methods:** 160 dental practitioners were met by utilizing a poll which enquired about the radiographic assessment strategies endorsed by experts in implant site evaluation in their implantology practice. Different explanations behind picking specific imaging modalities were additionally enquired. **Statistical Analysis and Result:** Around 55% of the dental practitioners recommended only panoramic radiography for dental implant evaluation and 18% requested panoramic radiography in addition to periapical radiography and conventional tomography and/or computed tomography (CT). Only 8% of the dental specialists requested conventional tomography or CT as a solitary examination, although 12% requested it in blend with other imaging modalities. **Conclusion:** Within the limitations of the study, this paper has demonstrated that the larger part of dental practitioners endorses panoramic radiographs. Moreover for achieving larger views, accessibility and broad coverage; a combination of panoramic and intraoral periapical radiographs is also reported to be quite popular among the said clinicians.

Key words: Computed Tomography, Dental Implants, Dental Radiography, Panoramic Radiography

Received: 22 August, 2019

Revised: 19 October, 2019

Accepted: 22 October, 2019

Corresponding author: Dr. Supriya Singh, Private Practitioner, Department of Oral Medicine and Radiology

This article may be cited as: Singh R, Singh S, Nabi AT, Huda I, Singh DK. Evaluation of Existing Radiographic Prescription Tendencies in Planning Dental Implant Therapy: A Survey Based Original Study. J Adv Med Dent Scie Res 2019;7(11):100-103.

INTRODUCTION

The use of osteointegrated dental implants is a widely accepted procedure in the replacement of edentulous spaces. Long-term clinical success of osteointegrated implants is based on careful diagnosis and treatment planning. Treatment planning for implants includes a radiographic examination that provides information about the location of anatomical structures, the quality and quantity of available bone, the presence of bone lesions,

and the number and size of implants, which are essential for successful implant treatment. Radiographic measurement of marginal bone loss has been the main criteria in the assessment of success in oral implants.¹⁻³ The choice of when to endorse imaging relies on the reconciliation of these elements and can be sorted out into three stages. Those are: (1) Pre-surgical implant imaging, (2) surgical and interventional implant imaging. (3) post prosthetic implant imaging. Albeit a few picture

indicative strategies are accessible to assess proposed locales for implants, at present, not a solitary strategy is viewed as perfect for pre-and post-agent investigations. Along these lines, few creators propose a mix of different procedures to acquire dependable data.⁴ Long-term clinical success of osteointegrated implants is based on careful diagnosis and treatment planning. Radiographic examination provides information about the location of anatomical structures, the quality and quantity of available bone, the presence of bone lesions in the potential area. Many types of presurgical radiographic techniques are recommended for implant treatment planning. The American academy of oral and maxillofacial radiology (AAOMR) recommends the use of cross-sectional images for the implant site evaluation, several studies have reported cross-sectional imaging to be more accurate.⁵⁻⁶ There is to a great degree rare writing overall with respect to the radiographic remedy rehearses among implant experts worldwide and whether they stick to the proposals set forward by proficient bodies.⁷ Hence, the prime aim of this paper is to study the current radiographic prescriptions in dental implant therapy among dental practitioners in Northern Indian region.

MATERIALS AND METHODS

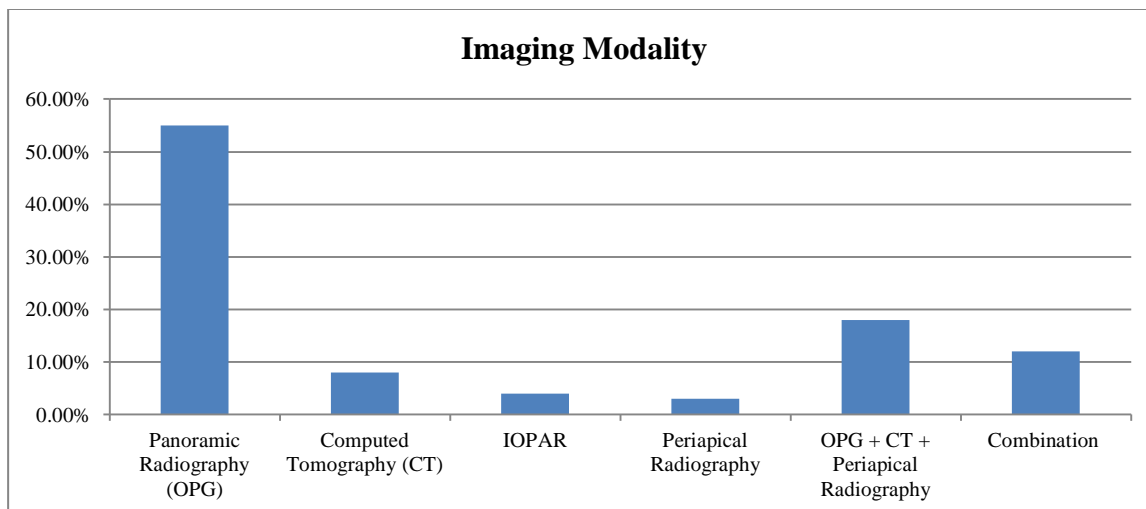
A total of one hundred and fifty dental specialists from the city were randomly selected in utilizing a closed end survey which enquired about the types of radiographic examinations the dental specialists recommend for pre-operative implant site evaluations and development. The related details of the general dental practitioners were received from the registry of city society association of dental practitioners. For example; panoramic radiography, CT, conventional tomography and periapical radiography. They were further studied on the basis of their decision, including cost, radiation dosage, wide scope of facial bones and teeth, accessibility and estimation accuracy. The majority of the dental specialists associated with the examination were specific or prepared in implant dentistry. The privacy policy and other rights of the study participants were absolutely ensured. Informed consent was obtained from the respondents those were voluntarily ready for participation. To ensure completely stress-free replies, the study was conducted over a period of 30 days in which dentists are asked to fill and send back the questionnaire. The significance of this study was explained in detail to all general dental practitioners. Results thus received was compiled in table and subjected to basic statistical analysis. P value less than 0.05 was considered significant (p< 0.05).

RESULT

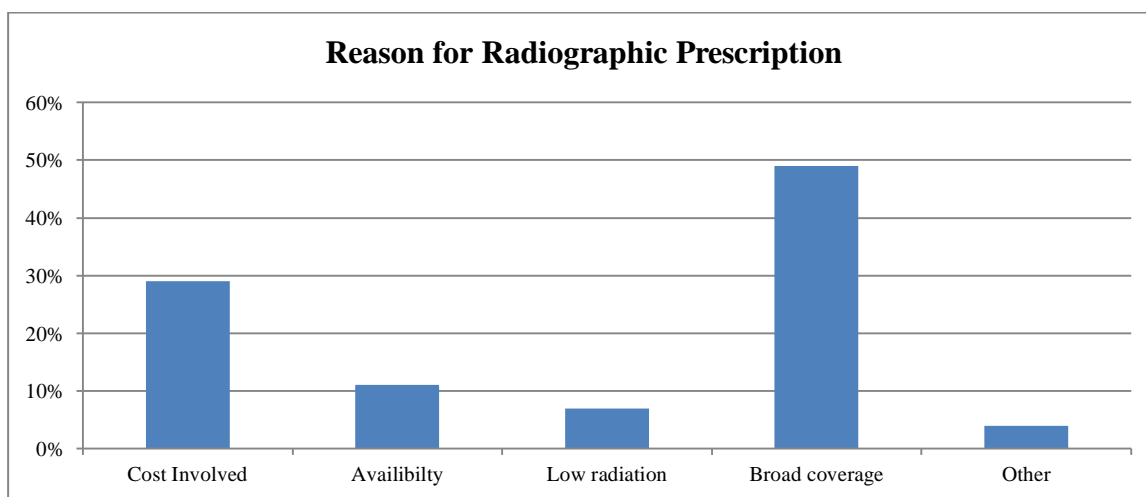
All the composed data were compiled judiciously and subjected to fundamental statistical analysis with SPSS statistical package for the Social Sciences version 21 for Windows. Basic statistical analysis was done firstly followed by other test, namely, ANOVA for further data analysis. Approximately 55% of the dental practitioners recommended only panoramic radiography for dental implant evaluation and 18% requested panoramic radiography in addition to periapical radiography and conventional tomography and/or computed tomography (CT). Only 8% of the dental specialists requested conventional tomography or CT as a solitary examination, although 12% requested it in blend with other imaging modalities. The enquired dental practitioners in this examination approved panoramic radiographs in dental implant assessment based on broad coverage and cost [Table 1, Graph 1]. On studying reasons for different radiographic prescriptions, we noticed that it was based on multiple options [Graph 2].

Table No 1: Demographic details of dental practitioners

Variables	Numbers
Age (years)	
25-35	31
36-45	36
46-55	54
>55	29
Gender	
Male	95
Female	55
Specialty	
Implantology	51%
Periodontology	21%
General Dentistry	8%
Oral Surgery	13%
Prosthodontics	7%
Type of practice	
Private	104
Government	33
Both	13
Years of practice	
5-10	29
11-15	43
16-20	55
>20	29



Graph 1: Imaging modality options in dental implant evaluation



Graph 2: Reasons for prescribing radiographs for dental implant evaluation

DISCUSSION

Several types of radiographic techniques are used in implant treatment planning, such as Intra-Oral Periapical Radiography (IOPAR), Orthopantomography (OPG), occlusal radiography, Conventional tomography, Computed Tomography (CT), and Cone-Beam Computed Tomography (CBCT). It is the clinician who usually decides the best method for each clinical situation. The American academy of oral and maxillofacial radiology (AAOMR) recommended that cross-sectional imaging be used for the assessment of all dental implant sites and many studies have reported cross-sectional imaging to be more accurate. Currently CBCT is the imaging method of choice to gain this diagnostic information.⁸⁻⁹ Dental Implants are being widely used for the replacement of missing teeth. Dental practitioners have remarkably taken up this treatment modality and adapted to the advancements in oral rehabilitation. The main criterion in assessing the success of oral implants has been the

marginal bone loss evidenced by the radiological examination. The imaging objectives aids the clinician in providing the cross-sectional views of the dental arch for visualization of spatial relationship of anatomic structures of the maxilla and mandible, the quality and quantity of available bone, the presence of infra-bony lesions, the occlusal pattern and the number and size of implants as well as prosthesis design, all which are essential for successful implant treatment planning and evaluation of the ongoing implant functioning. A strategy for assessing the panoramic radiograph for mandibular posterior implants and examination with the clinical assessment amid surgery was created by recognizing the mental foramen and the posterior extent of the inferior alveolar channel.¹⁰⁻¹¹ Long-term clinical success of osteointegrated implants is based on careful diagnosis and treatment planning. Radiographic examination provides information about the location of anatomical structures, the quality and quantity of available bone, the presence of bone

lesions in the potential area. Many types of presurgical radiographic techniques are recommended for implant treatment planning. The American academy of oral and maxillofacial radiology (AAOMR recommends the use of cross-sectional images for the implant site evaluation, several studies have reported cross-sectional imaging to be more accurate.¹²⁻¹⁶ Other than the reasons expressed above with respect to the low usage of cross-sectional imaging by clinicians, we guess that one reason why more dental practitioners don't utilize conventional tomography or CT is the trouble of picture understanding.^{17,18} Endeavors must be made to take care of these issues, changing the instructive projects in proceeding with training courses. Albeit numerous modalities are accessible for imaging the implant site, the right and required strategy ought to be received relying upon the case and the clinician's judgment to translate the picture gained.^{19,21} Functional and esthetic restoration is the main objective of rehabilitation using dental implants. Thus, the imaging of potential recipient sites should provide accurate information for precise placement of implants incorrect three-dimensional position.

CONCLUSION

Within the limitations of the study, this paper has demonstrated that the larger part of dental practitioners endorse panoramic radiographs. Moreover for achieving larger views, accessibility and broad coverage; a combination of panoramic and intraoral periapical radiographs is also reported to be quite popular among the said clinicians. Furthermore, our study outcomes could be treated as suggestive for predicting clinical inferences of such situations. Nevertheless we expect other genuine studies to be conducted that could further establish certain concrete guidelines in this field.

REFERENCES

1. Sonick M, Abrahams J, Faiella RA. A comparison of the accuracy of periapical, panoramic, and computerized tomographic radiographs in locating the mandibular canal. *Int J Oral Maxillofac Implants* 1994;9:455-60.
2. Quirynen M, Van Assche N, Botticelli D, Berglundh T. How does the timing of implant placement to extraction affect outcome? *Int J Oral Maxillofac Implants* 2007;22 Suppl:203-23.
3. Adell R, Lekholm U, Rockler B, Brånemark PI. A 15-year study of osseointegrated implants in the treatment of the edentulous jaw. *Int J Oral Surg* 1981;10:387-416.
4. Andersson B, Odman P, Lindvall AM, Brånemark PI. Five-year prospective study of prosthodontic and surgical single-tooth implants treatment in general practices and at a specialist clinic. *Int J Prosthodont* 1998;11:351-5.
5. Welander U, Li G, McDavid WD, Tronje G. Transtomography: A new tomographic scanning technique. *Dentomaxillofac Radiol* 2004;33:188-95.
6. Bousquet F, Bousquet P, Vazquez L. Transtomography for implant placement guidance in non-invasive surgical procedures. *Dentomaxillofac Radiol* 2007;36:229-33.
7. Schwarz MS, Rothman SL, Rhodes ML, Chafetz N. Computed tomography: Part I. Preoperative assessment of the mandible for endosseous implant surgery. *Int J Oral Maxillofac Implants* 1987;2:137-41.
8. Schwarz MS, Rothman SL, Chafetz N, Rhodes M. Computed tomography in dental implantation surgery. *Dent Clin North Am* 1989;33:555-97.
9. Scaf G, Lurie AG, Mosier KM, Kantor ML, Ramsby GR, Freedman ML. Dosimetry and cost of imaging osseointegrated implants with film-based and computed tomography. *Oral Surg Oral Med Oral Pathol Oral Radiol Endod* 1997;83:41-8.
10. Bruggenkate CM, van der Linden LW, Oosterbeek HS. Parallelism of implants visualized on the orthopantomogram. *Int J Oral Maxillofac Surg* 1989;18:213-5.
11. Tyndall DA, Brooks SL. Selection criteria for dental implant site imaging: a position paper of the American Academy of Oral and Maxillofacial Radiology. *Oral Surg Oral Med Oral Pathol Oral Radiol Endod* 2000;89:630-7.
12. Beason RC, Brooks SL. Preoperative implant site assessment in southeast Michigan. *J Dent Res* 2001;80:137.
13. Klinge B, Petersson A, Maly P. Location of the mandibular canal: Comparison of macroscopic findings, conventional radiography, and computed tomography. *Int J Oral Maxillofac Implants* 1989;4:327-32.
14. Lindh C, Petersson A. Radiologic examination for location of the mandibular canal: A comparison between panoramic radiography and conventional tomography. *Int J Oral Maxillofac Implants* 1989;4:249-53.
15. Scaf G, Lurie AG, Mosier KM, Kantor ML, Ramsby GR, Freedman ML. Dosimetry and cost of imaging osseointegrated implants with film-based and computed tomography. *Oral Surg Oral Med Oral Pathol Oral Radiol Endod* 1997;83:41-8.
16. ten Bruggenkate CM, van der Linden LW, Oosterbeek HS. Parallelism of implants visualised on the orthopantomogram. *Int J Oral Maxillofac Surg* 1989;18:213-5.
17. Tyndall DA, Brooks SL. Selection criteria for dental implant site imaging: A position paper of the American Academy of Oral and Maxillofacial radiology. *Oral Surg Oral Med Oral Pathol Oral Radiol Endod* 2000;89:630-7.
18. Bou Serhal C, Jacobs R, Flygare L, Quirynen M, van Steenberghe D. Perioperative validation of localisation of the mental foramen. *Dentomaxillofac Radiol* 2002;31:39-43.
19. Bolin A, Eliasson S, von Beetzen M, Jansson L. Radiographic evaluation of mandibular posterior implant sites: Correlation between panoramic and tomographic determinations. *Clin Oral Implants Res* 1996;7:354-9.
20. Sakakura CE, Morais JA, Loffredo LC, Scaf G. A survey of radiographic prescription in dental implant assessment. *Dentomaxillofac Radiol* 2003;32:397-400.
21. Schropp L, Wenzel A, Kostopoulos L. Impact of conventional tomography on prediction of the appropriate implant size. *Oral Surg Oral Med Oral Pathol Oral Radiol Endod* 2001;92:458-63