

Original Article

Retrospective Evaluation of Patients Undergoing Endoscopic Lumbar Discectomy: An Observation Study

Prashant Garhwal¹, Bimla Choudhary²

¹Consultant, Department of Orthopedics, SMS Medical College, Jaipur, Rajasthan, India.

²Senior Resident, Department of Gynaecology, Government Medical College, Sikar, Rajasthan

ABSTRACT:

Background: Endoscopic disc surgery is a relatively new and minimally invasive technique, and endoscopic lumbar discectomy (ELD) has gained increasing popularity among the spine surgeons for the treatment of herniated intervertebral disc largely because it has the ability to overcome the limitation of muscles splitting. Hence; we planned the present study to retrospectively analyse patients undergoing ELD. **Materials & methods:** The present study to evaluate of data of patients who underwent endoscopic lumbar discectomy (ELD). Data records of a total of 50 patients who underwent ELD were included in the present study. Data records of all the patients were obtained. We also obtained the follow-up records of all the patients from record files. Modified Macnab criteria were used for grading the results: excellent, good, fair and poor. All the results were recorded and analysed by SPSS software. **Results:** Mean duration of the surgery in the present study was 68 minutes. Perioperative complications encountered in the present study were inadvertent removal of facet joint, minor dural punctures and nerve root damage. None of these complications extended till the postoperative period. **Conclusion:** ELD is a safer technique which provides early rehabilitation and lesser side effects.

Key words: Endoscopic lumbar discectomy, Outcome, Retrospective

Received: 08 May 2018

Revised: 27 May 2018

Accepted: 01 June 2018

Corresponding Author: Dr. Bimla Choudhary, Senior resident, Department of Gynaecology, Government Medical College, Sikar, Rajasthan, India.

This article may be cited as: Garhwal P, Choudhary B. Retrospective Evaluation of Patients Undergoing Endoscopic Lumbar Discectomy: An Observation Study. J Adv Med Dent Scie Res 2018;6(6):80-83.

INTRODUCTION

Low back and sciatic pain have been one of the most common and disabling spinal disorders recorded in medical history. Lumbar disc herniation is a major cause of back pain and sciatica. The surgical management of lumbar disc prolapse has evolved from exploratory laminectomy to percutaneous endoscopic discectomy.¹⁻³ Endoscopic disc surgery is a relatively new and minimally invasive technique, and endoscopic lumbar discectomy (ELD) has gained increasing popularity among the spine surgeons for the treatment of herniated intervertebral disc largely because it has the ability to overcome the limitation of muscles splitting. The use of an endoscope allows the same access port and the same surgical technique to be used on the vertebral canal and disc while at the same time reducing the skin incision and minimizing the access port.⁴⁻⁶ The advantages of this technique are the same as those for discectomy but the immediate postoperative effects are reduced allowing a more rapid rehabilitation and return to previous activities

for the patient. It is also attractive as a small skin incision with a gentle and minimal tissue dissection and excellent visualization.⁷ Hence; we planned the present study to retrospectively analyse patients undergoing ELD.

MATERIALS & METHODS:

The present retrospective study was conducted in the department of orthopaedic surgery of the medical institute and it included evaluation of data of patients who underwent endoscopic lumbar discectomy (ELD). Data records of a total of 50 patients who underwent ELD were included in the present study. Inclusion criteria for the present study included:

- Patients between the age group of 18 to 60 years,
- Patients who underwent ELD for L4-5 or L5-S1 PIVD,
- Patients with negative history of any other systemic illness,
- Patients with absence of any known drug allergy

Data records of all the patients were obtained. We also obtained the follow-up records of all the patients from record files. Modified Macnab criteria were used for grading the results: ⁸ excellent, good, fair and poor. All the results were recorded and analysed by SPSS software. Univariate regression curve was used for assessment of level of significance.

In the present study, we analysed a total of 20 patients, among which 12 were males while the remaining 8 were females. Mean age of the patients of the present study was 49.1 years. Mean duration of the surgery in the present study was 68 minutes. Perioperative complications encountered in the present study were inadvertent removal of facet joint, minor dural punctures and nerve root damage. None of these complications extended till the postoperative period.

RESULTS

Table 1: Details of the patients included in the present study

Parameter	Value
No. of patients	20
Males	12
Females	8
Mean age (years)	49.1

Graph 1: Details of the patients included in the present study

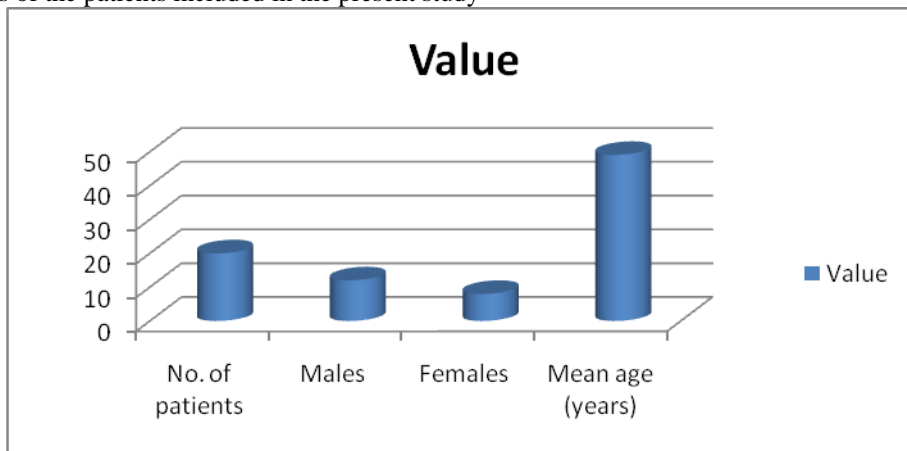
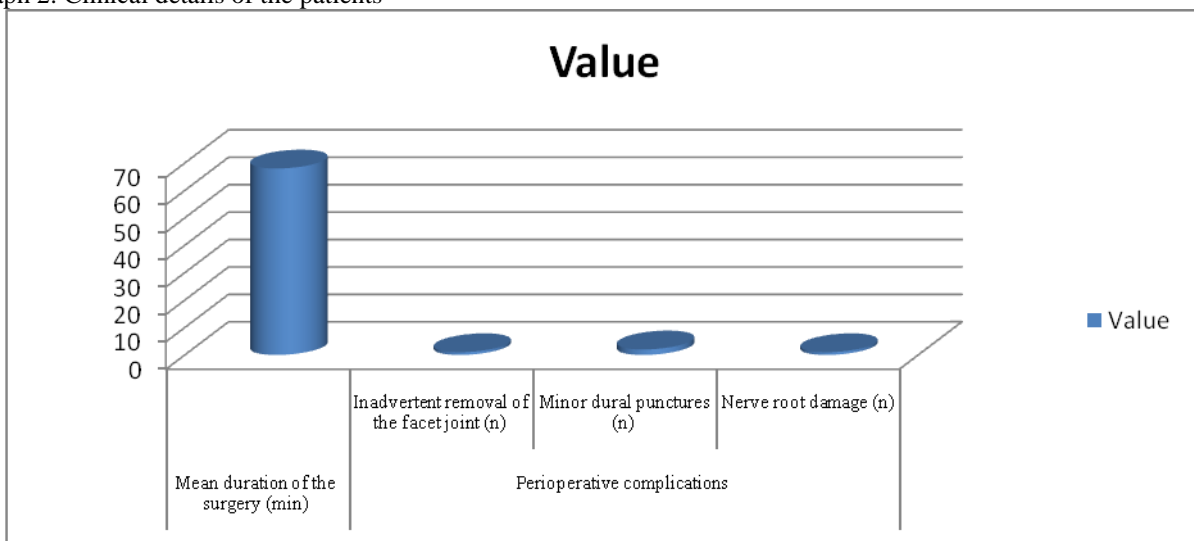


Table 2: Clinical details of the patients

Parameter		Value
Mean duration of the surgery (min)		68
Perioperative complications	Inadvertent removal of the facet joint (n)	1
	Minor dural punctures (n)	2
	Nerve root damage (n)	1

Graph 2: Clinical details of the patients



DISCUSSION

In the present study, mean duration of the surgery in the present study was 68 minutes. Perioperative complications encountered in the present study were inadvertent removal of facet joint, minor dural punctures and nerve root damage. None of these complications extended till the postoperative period. Hur JW et al reported surgical experience of treating contained or noncontained lumbar disc herniation (LDH) at the L3-L4 and L4-L5 or L4-L5 and L5-S1 levels by transforaminal percutaneous endoscopic lumbar discectomy and annuloplasty (PELDA) through the single entry point. When there are concurrent LDHs involving lower two levels simultaneously, PELDA has not been performed. Between March 2008 and May 2011, eight patients presented with back pain or radicular lower limb pain. Upon radiologic examination using magnetic resonance imaging, the patients were diagnosed with central or paramedian LDH at low spine levels (L3-L4 and L4-L5 or L4-L5 and L5-S1) consistent with their clinical presentations. They performed double PELDA at the affected two levels simultaneously through a single skin portal. The symptoms were relieved dramatically, and all patients were discharged the next day. There was no radiologic instability during the follow-up period. Transforaminal PELDA to treat two levels of LDH through a single portal could be considered as one of the minimally invasive treatment modalities that avoids conventional open surgery.⁹

Jhala A et al evaluated technical problems, complications, and overall initial results of microendoscopic discectomy. First 100 consecutive cases aged 19-65 years operated by microendoscopic discectomy between August 2002 – December 2005 are reported. All patients with single nerve root lesions including sequestered or migrated and selected central disc at L4-5 and L5-S1 were included. The patients with bilateral radiculopathy were excluded. All patients had preoperative MRI and first 11 patients had postoperative MRI to check the adequacy of decompression. Diagnostic selective nerve root blocks were done in selective cases to isolate the single root lesion when MRI was inconclusive (n=7). All patients were operated by a single surgeon with the Metrx system (Medtronic). 97 were operated by 18-mm ports, and only three patients were operated by 16-mm ports. Postoperatively, all patients were mobilized as soon as the pain subsided and discharged within 24–48 h postsurgery. Patients were evaluated for technical problems, complications, and overall results by modified Macnab criteria. Patients were followed up at 2, 6, and 12 weeks. The mean follow up was 12 months (range 3 months – 4 years). Open conversion was required in one patient with suspected root damage. Peroperatively single facet removal was done in 5 initial cases. Minor dural punctures occurred in seven cases and root damage in one case. The average surgical time was 70 min (range 25-210 min). Average blood loss was 20-30 ml. Technical difficulties encountered in initial 25 cases were insertion of guide pin, image orientation, peroperative dissection and bleeding problems, and reaching wrong levels

suggestive of a definitive learning curve. Postoperative MRI (n=11) showed complete decompression. Overall 91% of patients had good-to-excellent results, with four patients having recurrence of whom three were reoperated. Four patients had postoperative discitis. One of the patients required fusion for discitis and rest were managed conservatively. One patient had root damage to L5 root that had paresthesia in L5 region even on 4 years of follow-up. Microendoscopic discectomy is minimally invasive procedure for discectomy with early encouraging results. Once definite learning curve was over and expertise is acquired, the results of this procedure are acceptable safe and effective.¹⁰ Bhasare R et al presented long-term results from a 10-year follow-up after endoscopic lumbar discectomy (ELD) by "Destandau's technique". Endoscopic disc surgery by Destandau's technique using ENDOSPINE Karl Storz system is a relatively new technique. It was introduced in 1993. It has been gaining popularity among the spine surgeons, as it is attractive for small skin incision and allows a gentle and excellent tissue dissection with excellent visualization. Many authors have published results of their own studies; however, in all these studies the long-term follow up of the patients has not been emphasized. A total of 21 patients selected on basis of strict inclusion criteria's underwent ELD from November 2004 to March 2005. Surgery outcome was assessed by using "Prolo's Anatomic-Functional-Economic Rating System" (1986). Patients were followed up to 10 years. In addition, we compared the results of our study with other studies. Outcomes were excellent in 17 patients (80.95%), good in 3 (14.28%) and fair in 1 (4.78%), with no patients having a poor result. In our study, 19 patients (90.47%) were able to resume their previous works/jobs, and only 2 (9.52%) needed to change their jobs for lighter work. No patient retired from his or her previous daily routine following the operation. The initial and long-term results are very good for endoscopic lumbar discectomy by Destandau's technique.¹¹

CONCLUSION

Under the light of above obtained results, the authors concluded that ELD is a safer technique which provides early rehabilitation and lesser side effects. However; further studies are recommended.

REFERENCES

1. Williams RW. Microlumbar discectomy: a conservative surgical approach to the virgin herniated lumbar disc. *Spine (Phila Pa 1976)* 1978;3:175–182.
2. Perez-Cruet MJ, Foley KT, Isaacs RE, Rice-Wyllie L, Wellington R, Smith MM, et al. Microendoscopic lumbar discectomy: Technical note. *Neurosurgery*. 2002;51:S129–36.
3. Palmer S. Use of a tubular retractor system in microscopic lumbar discectomy: 1 year prospective results in 135 patients. *Neurosurg Focus*. 2002;13:E5.
4. Destandau J. A special device for endoscopic surgery of lumbar disc herniation. *Neurol Res*. 1999;21:39–42.
5. Destandau J. Technical features of endoscopic surgery for lumbar disc herniation: 191 patients. *Neurochirurgie*. 2004;50:6–10.

6. See DH, Kraft GH. Electromyography in paraspinal muscles following surgery for root compression. Arch Phys Med Rehabil. 1975;56:80–83.
7. Smith MM, Foley KT. Microendoscopic discectomy (MED): surgical technique and initial clinical results; Proceedings of the Thirteen annual Meeting of the joint section of Disorders of the Spine and Peripheral Nerve of the American Association of Neurological Surgeons; 1997 Feb; Newport Beach, CA.
8. Lyson T, Mariak Z, Jadeszko M, Kochanowicz J, Lewko J. Results of Destandau microendoscopic lumbar discectomy. Neurol Neurochir Pol. 2008;42:105–111.
9. Hur JW1, Kim JS1, Shin MH1, Ryu KS1, Park CK1, Lee SH2. Percutaneous endoscopic lumbar discectomy and annuloplasty for lumbar disc herniation at the low two contiguous levels: single-portal, double surgeries. J Neurol Surg A Cent Eur Neurosurg. 2014 Sep;75(5):381-5. doi: 10.1055/s-0033-1345097. Epub 2013 Jun 13.
10. Jhala A, Mistry M. Endoscopic lumbar discectomy: Experience of first 100 cases. Indian Journal of Orthopaedics. 2010;44(2):184-190. doi:10.4103/0019-5413.62051.
11. Bhaisare R, Kamble B, Patond K. Long-Term Results of Endoscopic Lumbar Discectomy by “Destandau’s Technique.” Asian Spine Journal. 2016;10(2):289-297. doi:10.4184/asj.2016.10.2.289.

Source of support: Nil

Conflict of interest: None declared

This work is licensed under CC BY: ***Creative Commons Attribution 3.0 License.***