

## Original Article

### Classifying Impacted Mandibular Third Molar & its Relation with Inferior Alveolar Canal- A Clinical Study

Sandeep Kumar Bains<sup>1</sup>, Archana Bhatia<sup>2</sup>

<sup>1</sup>Associate Professor, Oral Medicine & Radiology, <sup>2</sup>Associate Professor, Periodontics & Implantology, Dasmesh Institute of Research & Dental Sciences, Faridkot

#### ABSTRACT:

**Background:** The exact knowledge of relation of impacted mandibular third molar with inferior alveolar canal is useful in removing the tooth. The present study was conducted to assess the relationship with impacted mandibular third molar with inferior alveolar canal by using panoramic radiographs and CBCT. **Materials & Methods:** 120 patients requiring surgical extraction of impacted mandibular third molar were selected and subjected to OPG and CBCT. Images thus obtained were analyzed by oral and maxillofacial radiologist for assessment of relationship. Newer classification given by Michele was considered. **Results:** Out of 120 patients, 70 were males 50 were females. The difference was non- significant (P< 0.1). Darkening of roots (DR) were seen in 30 males and 20 females, diversion of canal (DC) in 12 males and 10 females, narrowing of canal (NC) in 9 males and 5 females, presence of cortication in 10 males and 8 females and interruption of white line (IWL) in 14 males and 7 females. The difference was significant (P< 0.05). Darkening of roots (DR) was seen in 50 patients on OPG and similar number were confirmed by CBCT, diversion of canal (DC) in 22 patients on OPG and 24 on CBCT, narrowing of canal (NC) in 14 patients on OPG and 16 on CBCT, presence of cortication in 18 patients on OPG and 19 on CBCT and interruption of white line (IWL) in 21 patients both on OPG and CBCT. The difference was non- significant (P> 0.05). Third molar relation with IAC was class 0 (0), subtype 1A (20), subtype 1B (24), subtype 2A (1), subtype 2B (2), subtype 3A (25), subtype 3B (22), subtype 4A (2), subtype 4B (16), subtype 5A (1), subtype 5B (2), subtype 6A (2), subtype 6B (2) and class 7 (1). The difference was significant (P< 0.05). **Conclusion:** The relationship of impacted mandibular third molar with inferior alveolar canal using newer classification of CBCT images would definitely proven to be the boon for the surgeon.

**Key words:** Cone beam computer tomography, Impacted, Inferior alveolar canal.

Received: 20 January 2018

Revised: 14 February 2018

Accepted: 18 February 2018

**Corresponding author:** Dr. Sandeep Kumar Bains, Associate Professor, Oral Medicine & Radiology, Dasmesh Institute of Research & Dental Sciences, Faridkot, Punjab, India

**This article may be cited as:** Bains SK, Bhatia A. Use of Herbal Medicines in Dentistry- A Review. J Adv Med Dent Scie Res 2018;6(3):77-81.

#### INTRODUCTION

The chances of mandibular third molar impaction are quite high which requires extraction of tooth. Most of cases require surgical extraction. In other cases, reasons for third molar extraction can be prophylactic or orthodontic. The proximity of impacted third molar with inferior alveolar canal (IAC) needs more attention as damage to the inferior alveolar nerve (IAN) during extraction is a significant and common complication. Neurological involvement is a serious complication may leads to post-operative paresthesia.<sup>1</sup>

IAN paresthesia is transient or permanent prolonged sensory deficit and/or abnormal sensation in the lower jaw, mental region and lower lip of the affected side. The incidence of IAN paresthesia following surgery is reported to be between 0.4% and 8%. Permanent paresthesia may lead to functional deficits, and a decreased quality of life.<sup>2</sup>

Thus a radiological study becomes mandatory to assess the risk of a possible post-operative injury to the IAN during extraction of impacted mandibular third molar. Hence, accurate preoperative radiographic examination is therefore considered indispensable before extraction of mandibular third molar.<sup>3</sup>

Earlier, radiographic signs such as darkening, narrowing or deflection of the root, dark and bifid apex of the root, interruption of cortical outline of mandibular canal, canal diversion or narrowing, island-shaped apex were indicative of proximity between third molar and IAC on panoramic radiographs. Being, 2-D imaging, OPG images lack third dimension. With the advent of CBCT, this drawback of OPG has eliminated. Cone-beam computer tomography (CBCT) can define the several types of relationships in a buccal/lingual, mesio- distal and superior- inferior direction. The main drawback of conventional medical CT is the much higher dose that the patient receives and higher cost of the examination in comparison with panoramic radiographs and CBCT images.<sup>4</sup>

To identify the different types of possible relationships between the third molar and the mandibular canal, a new radiological classification proposed by Michele et al<sup>5</sup>. applicable on the cross-sectional images was considered. The rationale of this classification is that of researching a restricted number of categories able to describe all the possible anatomic variants that the clinician can encounter before surgery.

-Class 0: the mandibular canal is not visible on the images (plexiform canal);

-Class 1: the mandibular canal runs apically or buccally with respect to the tooth but without touching it (the cortical limitations of the canal are not interrupted);

-Subtype 1A: the distance IAN/tooth is greater than 2 mm;

-Subtype 1B: the distance IAN/tooth is less than 2 mm;

-Class 2: the mandibular canal runs lingually to the tooth without touching it (the cortical limitations of the canal are not interrupted);

-Subtype 2A: the distance IAN/tooth is longer than 2 mm;

-Subtype 2B: the distance IAN/tooth is less than 2 mm;

-Class 3: the mandibular canal runs apical or buccal touching the tooth;

-Subtype 3A: in the point of contact the mandibular canal shows a preserved diameter;

-Subtype 3B: in the point of contact the mandibular canal shows a smaller calibre and/or an interruption of the corticalization;

- Class 4: the mandibular canal runs lingually touching the tooth.

-Subtype 4A: in the point of contact the mandibular canal shows a preserved diameter; subtype 4B: in the point of contact the mandibular canal shows a smaller calibre and/or an interruption of the corticalization;

- Class 5: the mandibular canal runs between the roots but without touching them.

-Subtype 5A: the distance IAN/tooth is greater than 2 mm;

-Subtype 5B: the distance IAN/tooth is less than 2 mm;

- Class 6: the mandibular canal runs between the roots touching them.

-Subtype 6A: in the point of contact the mandibular canal shows a preserved diameter;

-Subtype 6B: in the point of contact the mandibular canal shows a smaller calibre and/or an interruption of the corticalization;

- Class 7: the mandibular canal runs between fused roots.

Considering this, the present study was conducted to assess the relationship with impacted mandibular third molar with IAN by using panoramic radiographs and CBCT.

**MATERIALS & METHODS**

The present study was conducted on 120 patients with impacted mandibular third molar of both gender. Inclusion criteria for the study were patients above 18 years of age and clinical missing third molar. Exclusion criteria were pregnant women, poor quality panoramic radiographs and patients with systemic diseases. All were informed regarding the study and written consent was obtained. Ethical clearance for the study was taken from institutional ethical committee.

General information such as name, age, gender etc. was noted on case history proforma. Patients were explained the procedure of OPG and CBCT. After obtaining panoramic images, signs such as darkening of the root, diversion of the canal, narrowing of canal, presence of cortication, interruption in white line were looked. If any of above signs were present, patients were subjected to CBCT. The obtained images were evaluated by oral maxillofacial radiologist for the assessment of its relation. Results thus obtained were subjected to statistical analysis. P value < 0.05 was considered significant.

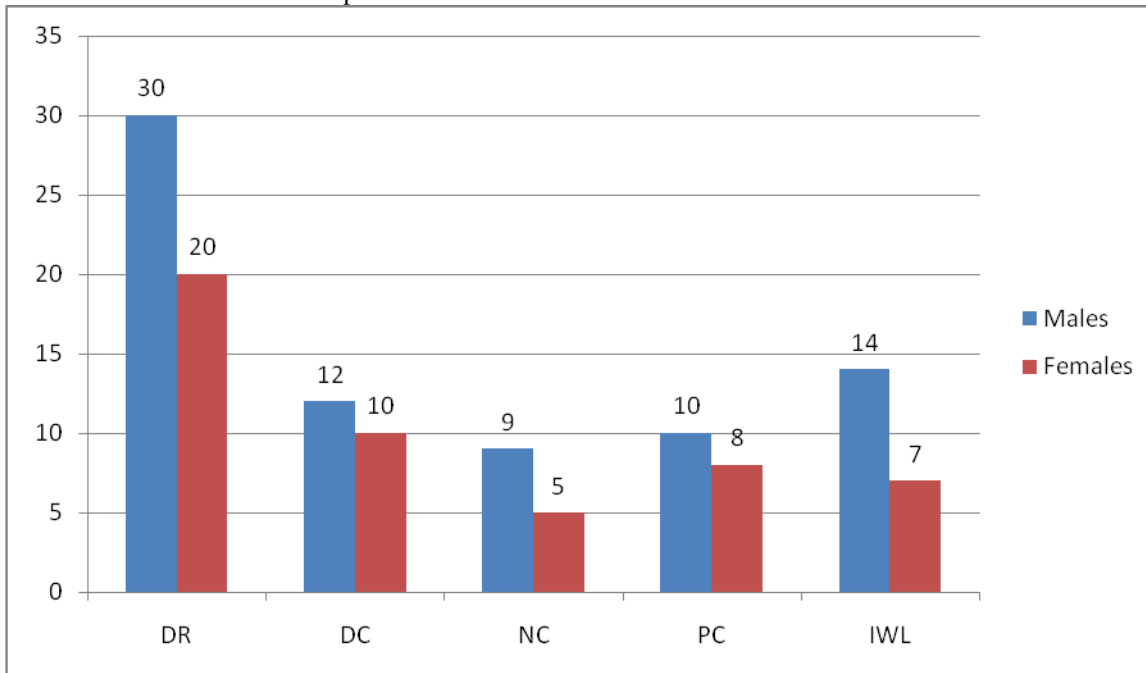
**RESULTS**

**Table I** Distribution of patients

		Total - 120
Males	Females	P value
70	50	0.1

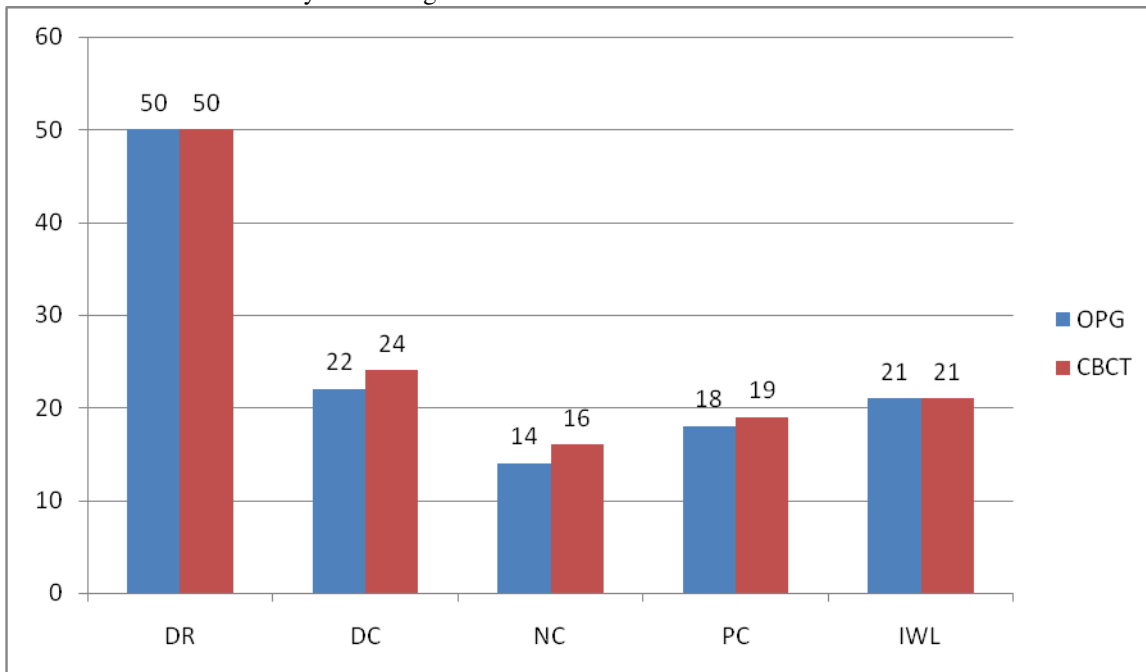
Table I shows that out of 120 patients, males were 70 and females were 50. The difference was non- significant (P- 0.1).

**Graph I** Presence of various criteria in patients



Graph I shows darkening of roots (DR) in 30 males and 20 females, diversion of canal (DC) in 12 males and 10 females, narrowing of canal (NC) in 9 males and 5 females, presence of cortication in 10 males and 8 females and interruption of white line (IWL) in 14 males and 7 females. The difference was significant ( $P < 0.05$ ).

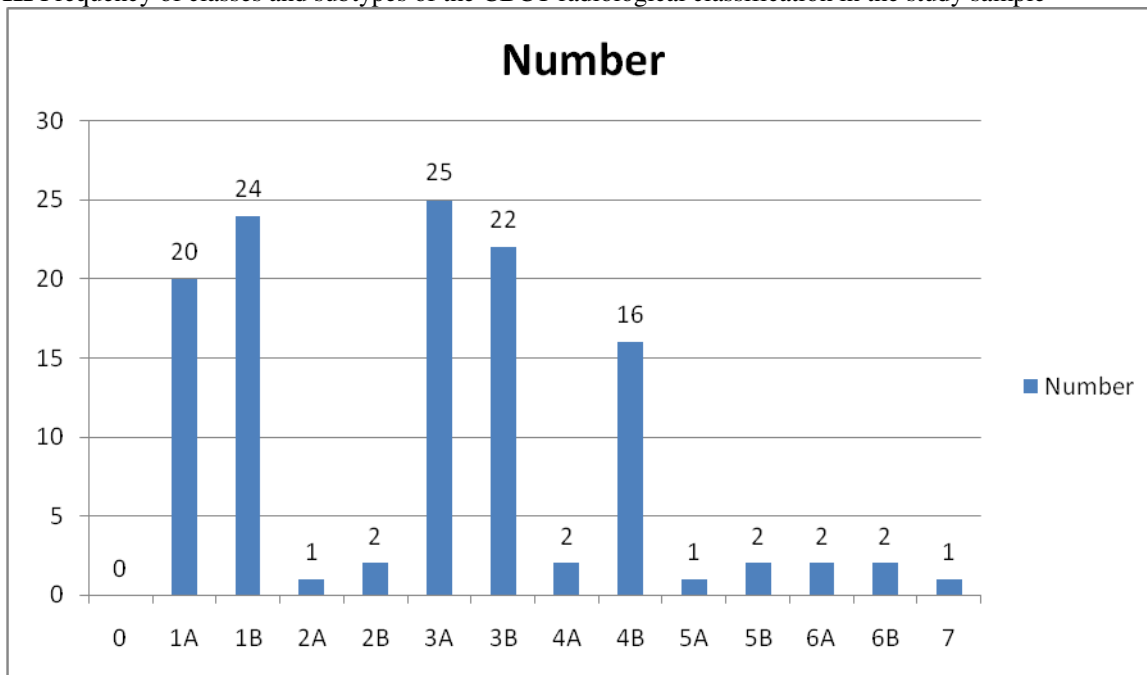
**Graph II** Confirmation of criteria by OPG images and CBCT



Graph II reveals that darkening of roots (DR) was seen in 50 patients on OPG and similar number were confirmed by CBCT, diversion of canal (DC) in 22 patients on OPG and 24 on CBCT, narrowing of canal (NC) in 14 patients on OPG

and 16 on CBCT, presence of cortication in 18 patients on OPG and 19 on CBCT and interruption of white line (IWL) in 21 patients both on OPG and CBCT. The difference was non- significant ( $P > 0.05$ ).

**Graph III** Frequency of classes and subtypes of the CBCT radiological classification in the study sample



Graph III shows that third molar relation with IAC was class 0 (0), subtype 1A (20), subtype 1B (24), subtype 2A (1), subtype 2B (2), subtype 3A (25), subtype 3B (22), subtype 4A (2), subtype 4B (16), subtype 5A (1), subtype 5B (2), subtype 6A (2), subtype 6B (2) and class 7 (1). The difference was significant ( $P < 0.05$ ).

## DISCUSSION

Several studies have been conducted on risk factors and complications associated with the surgery of impacted third molars. The most common complication is damage to IAN. To intercept and predict the risk of nerve injury, the radiographic examination is routinely performed in clinical practice before extraction.<sup>6</sup> The present study was conducted to assess the relationship with impacted mandibular third molar with IAN by using panoramic radiographs and CBCT.

We included 70 males and 50 females. Most commonly seen criteria was darkening of roots followed by diversion of canal (DC), interruption of white line (IWL), narrowing of canal (NC) and presence of cortication. This is in agreement with the results by De Mello et al.<sup>7</sup>

Various studies have shown the diagnostic accuracy of CBCT in predicting neurovascular bundle exposure prior to impacted mandibular third molar removal. However, due to the higher dose and cost of this imaging modality, many dental settings only rely on conventional radiographs such as intraoral periapical radiograph in the assessment of impacted mandibular third molar. However, OPG has many inherent limitations.<sup>8,9</sup> A fundamental one is that, the three dimensional anatomy is collapsed into a two-dimensional surface, which causes image features representing different anatomical structures to be superimposed. Features of

diagnostic interest may, therefore, be obscured and diagnostic accuracy is decreased.<sup>10</sup>

In this study, we found that diversion of canal (DC) was seen in 22 patients on OPG whereas 24 CBCT gave 24 cases. Similarly, narrowing of canal (NC) was observed in 14 patients on OPG and 16 on CBCT, presence of cortication in 18 patients on OPG and 19 on CBCT and interruption of white line (IWL) in 21 patients both on OPG and CBCT.

Tantanapornkul et al.<sup>11</sup> showed that CBCT was superior to OPG in predicting neurovascular bundle exposure following assessment of the relationship of the mandibular third molar root tip to the mandibular canal. They studied 161 impacted teeth and reported that the relative sensitivity and specificity of CBCT and OPG in predicting the nerve exposure was 93%, 77% and 70%, 63% respectively. In this study we found that maximum number of subtype 3A relation was seen followed by subtype 1B, subtype 3A, subtype 3B, subtype 1A, subtype 4B etc.

The purpose of the classification was not merely to detect if a real relationship between the mandibular canal and the roots of the third molar exists, but to intercept the individual anatomical relations for an optimised surgery.

## CONCLUSION

The relationship of impacted mandibular third molar with inferior alveolar canal gives a strong direction to the clinician to achieve the best possible result in removing it. CBCT gives knowledge of its relation in all three planes ie saggittal, axial and coronal. Furthermore, new classification would definitely prove to be the boon for the surgeon.

## REFERENCES

1. Rood JP, Shehab BA. The radiological prediction of inferior alveolar nerve injury during third molar surgery. Br J Oral Maxillofac Surg. 1990; 28:20-5.
2. Friedland B, Donoff B, Dodson TB. The use of 3-dimensional reconstructions to evaluate the anatomic relationship of the mandibular canal and impacted mandibular third molars. J Oral Maxillofac Surg. 2008; 66:1678-85.
3. Sedaghatfar M, August MA, Dodson TB. Panoramic radiographic findings as predictors of inferior alveolar nerve exposure following third molar extraction. J Oral Maxillofac Surg. 2005; 63:3-7.
4. Jhamb A, Dolas RS, Pandilwar PK, Mohanty S. Comparative efficacy of spiral computed tomography and orthopantomography in preoperative detection of relation of inferior alveolar neurovascular bundle to the impacted mandibular third molar. J Oral Maxillofac Surg. 2009; 67:58-66.
5. Michele Maglione, Fulvia Costantinides, Gabriele Bazzocchi Classification of impacted mandibular third molars on cone-beam CT images. J Clin Exp Dent. 2015; 7: 224-31.
6. Flygare L, Ohman A. Preoperative imaging procedures for lower wisdom teeth removal. Clin Oral Investig. 2008; 12:291-302.
7. De Melo Albert DG, Gomes AC, do Egito Vasconcelos BC, de Oliveira e Silva ED, Holanda GZ. Comparison of orthopantomographs and conventional tomography images for assessing the relationship between impacted lower third molars and the mandibular canal. J Oral Maxillofac Surg. 2006; 64: 1030-7.
8. Suomalainen A, Ventä I, Mattila M, Turtola L, Vehmas T, Peltola JS. Reliability of CBCT and other radiographic methods in preoperative evaluation of lower third molars. Oral Surg Oral Med Oral Pathol Oral Radiol Endod. 2010; 109: 276-84.
9. Park W, Choi JW, Kim JY, Kim BC, Kim HJ, Lee SH. Cortical integrity of the inferior alveolar canal as a predictor of paresthesia after third-molar extraction. J Am Dent Assoc. 2010; 141: 271-8.
10. Susarla SM, Sidhu HK, Avery LL, Dodson TB. Does computed tomographic assessment of inferior alveolar canal cortical integrity predict nerve exposure during third molar surgery? J Oral Maxillofac Surg. 2010; 68: 1296-1303.
11. Tantanapornkul W, Okouchi K, Fujiwara Y, Yamashiro M, Maruoka Y, Ohbayashi N, et al. A comparative study of conebeam computed tomography and conventional panoramic radiography in assessing the topographic relationship between the mandibular canal and impacted third molars. Oral Surg Oral Med Oral Pathol Oral Radiol Endod. 2007; 103: 253-9.

**Source of support:** Nil

**Conflict of interest:** None declared

This work is licensed under CC BY: ***Creative Commons Attribution 3.0 License.***