

## *Original Article*

### *Temporomandibular Joint Morphology in Normal Occlusion- A Cone Beam Computed Tomography Study*

Rakhi Bharat<sup>1</sup>, Rinku Saini Jagnade<sup>2</sup>

<sup>1</sup>Assistant Professor, Department of Orthodontics, Index Institute of Dental Sciences, Indore, Madhya Pradesh, India,

<sup>2</sup>Senior Lecturer, Department of Periodontology, Index Institute of Dental Sciences, Indore, Madhya Pradesh, India

#### **ABSTRACT:**

**Background:** The ideal position of the condyle in the glenoid fossa of the temporomandibular joint (TMJ) is one of the most hot topics found in dentistry with a lot of fundamental questions. The present study aimed to investigate the morphology of the TMJ in Normal occlusion (skeletal class-I) by cone beam computed tomography. **Materials and Method:** In this study patients, age group range from 15 to 22 years were taken who needed CBCT scan for their treatment. Bilateral TMJs were evaluated on the volumetric images, and the following three-dimensional measurements were obtained: 1) mandibular fossa position, inclination, and parameters; 2) mandibular condyle position, inclination, and parameters; 3) TMJ space measurements; and 4) centralization of the condyles in their respective mandibular fossae. The multiplanar images were evaluated for the surface-area measurements. **Results & Conclusion:** There were no significant mean differences found for all parameters in right side and left side of subjects, when skeletal class I. In the evaluation of centralization of the condyle on the right side in subjects with skeletal class 1 occlusion the mean values was statistically significant where as on the left side the mean values were not significant. The right side anteroposterior diameter of condylar process in class I subjects found strongly correlated and highly significant with left side. The anteroposterior difference between the geometric center of the right & left condylar processes in skeletal class-I found with geometric center situated anterior to the zero point reflected positive. Anteroposterior differences between the geometric center of the right and left condylar processes class I subjects, The concentric was greater and positive in normal occlusion.

Received: 12 May 2018

Revised: 01 September 2018

Accepted: 02 September 2018

**Correspondence to:** Dr. Rinku Saini Jagnade, Senior Lecturer, Department of Periodontology, Index Institute of Dental Sciences, Indore, Madhya Pradesh, India

**This article may be cited as:** Bharat R, Jagnade RS. Temporomandibular Joint Morphology in Normal Occlusion- A Cone Beam Computed Tomography Study. J Adv Med Dent Sci Res 2018;6(9):74-79.

#### **INTRODUCTION**

The temporomandibular joint (TMJ) is a synovial condylar joint between the base of the zygomatic process of the temporal bone and the condylar process of the mandible.<sup>1-3</sup> Its main articular components are the synovial pouches, articular disc, caudal and lateral ligaments, and joint capsule. The temporomandibular joint (TMJ) is a highly specialized articulation which is different from other synovial joints in that its articular surfaces are composed of dense fibrous tissue which functions like cartilage. Functionally, the temporomandibular joint is a ginglymus, where motion occurs in a rough hinge axis along a

repeatable plane supported by strong lateral ligaments. It is also an arthrodial joint permitting gliding motion.<sup>5,6</sup>

The Craniomandibular s a bicondylar articulation, with the mouth closed, the condyle is located in a centric position in glenoid fossae.<sup>7</sup>

The Cone beam CT (CBCT) has become an increasingly important source of three dimensional (3D) volumetric data in clinical orthodontics since its introduction into dentistry. CBCT provides information on gross morphological changes in TMJ structure relative to an orthopantomogram. The purpose of this study is to investigate the morphology of temporomandibular joint, the condyle -fossa

relationship, the concentric position of the condyles, and the dimensional and positional symmetries between the right and left condyles joint in skeletal class-I morphology of TMJ.

**AIM-** The aim of this study is to investigate the morphology of the TMJ in Normal occlusion (skeletal class-I) by cone beam computed tomography.

**OBJECTIVES-**

- 1- To investigate the morphology (condylar fossa relationship) in subjects with skeletal class-I malocclusion.
- 2 -To investigate the morphology (condyle symmetry) in subjects with skeletal class-I malocclusion

**MATERIALS AND METHOD**

In this study patients, age group range from 15 to 22 years were taken who needed CBCT scan for their treatment. The patients were examined clinically & investigated, using lateral cephalogram to determine the skeletal class I relationship & CT scan by CBCT to evaluate TMJ morphology of same patient.

- Two investigations were carried out on each subject
  - 1. Lateral Cephalogram
  - 2. CT Scan of Temporomandibular joint.

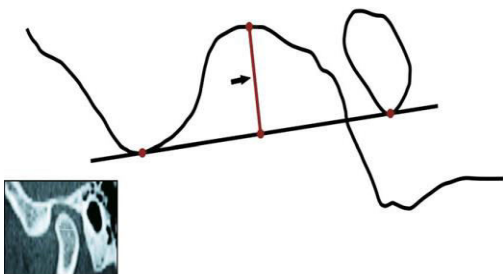
**METHODOLOGY**

The CT images were obtained with the patient in maximum intercuspatation, & their head were positioned in natural head position (NHP) so that Frankfort and mid sagittal plane were perpendicular to floor.

The helicoidal multislice CT scan was performed at 120 kV & 160 mA obtained 1mm thick tomographic imaging slices spaced at 1mm intervals. The measurements were determined by tracing the selected image structures as in most CT images, the dimensions did not correspond to the real size of the structures. Therefore, a scale for measurement conversion was determined for each image.

The following measurements were assessed on the **sagittal plane**

**1 - (Fig -1) Depth of the mandibular fossa:** measured from the most superior point of the fossa to the plane formed by the most inferior point of the articular tubercle to the most inferior point of the auditory meatus.



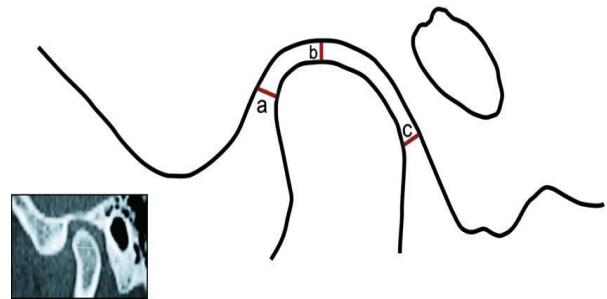
**Depth of the mandibular fossa:**

**2-(Fig -2)**

**a-Anterior joint space:** the shortest distance between the most anterior point of the condyle and the posterior wall of the articular tubercle.

**b- Superior Joint Space:** measured from the shortest distance between the most superior point of the condyle & the most superior point of the mandibular fossa.

**c- Posterior Joint Space:** represented by the shortest distance between the most Posterior point of the condyle and the posterior wall of the mandibular fossa



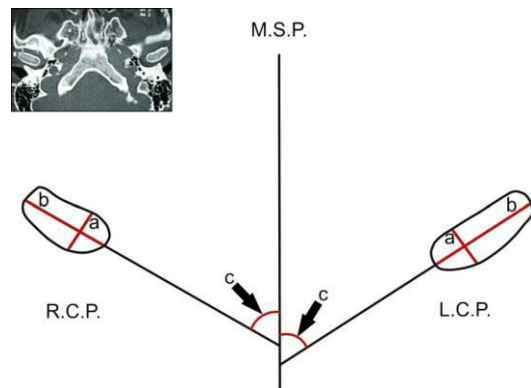
**Figure 2:** Ant, post & superior joint spaces

3- The following measurement were assessed on the **axial plane (fig-3)**

a- The largest anteroposterior diameter of the mandibular condylar processes.

b- The largest mediolateral diameter of the mandibular condylar processes.

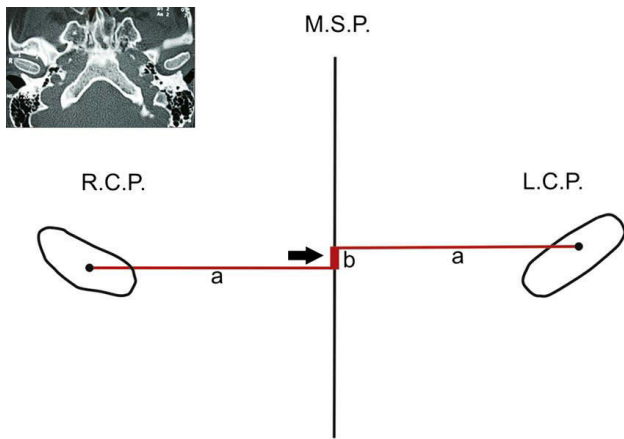
c- The angle between the long axis of the mandibular condylar process and the mid sagittal plane .



**Fig-3**

**4- (Figure 4)- A** -The distance between the geometric centers of the condylar processes and the midsagittal plane, measured with a line that passed through the geometric centers of the condylar processes and perpendicular to the midsagittal plane.

**b-** The anteroposterior difference between the geometric center of the right and left condylar processes as reflected on the midsagittal plane . The point representing the geometric center of the right condylar process was considered the zero point. The variations on the left side were measured from this point. The geometric centers situated anterior to the 0 point were considered positive, and those posterior to it were considered negative



(Fig-4)

Measurements of the anterior and posterior joint spaces were compared for the right and left sides to evaluate the centric position of the condyles in their respective mandibular fossa.

Student's paired t-test was used to identify the significance of difference in means of mandibular fossae, anterior, superior and posterior joint spaces, anterioposterior and mediolateral diameter of condylar process, angle for condylar process/mid sagittal plane, distance between condylar process and mid sagittal plane between right and left sides of subjects in normal occlusion .

Student's unpaired t-test was used to identify the significance of difference in means of mandibular fossae, anterior, superior and posterior joint spaces, anterioposterior and mediolateral diameter of condylar process, angle for condylar process/mid sagittal plane, distance between condylar process and mid sagittal plane.

**RESULT-**

A total subjects of skeletal Class I taken and further divided in two sub groups (Class I: Male, Class I: Female) were randomly selected for the present study. The age of all subjects were obtained with a span of 15 to 22 years with a

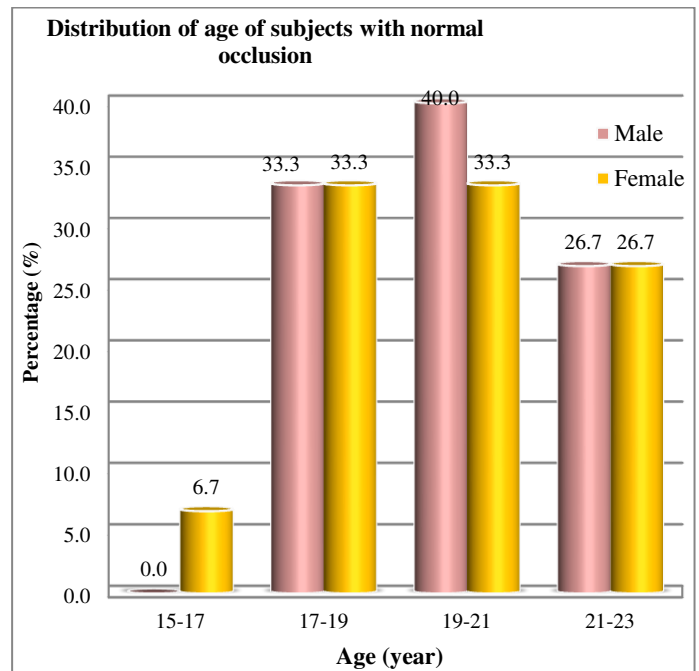
mean spread in age was 19.38±1.92 years. The mean spread of age for subjects in Class I: Male group (n=15) was 19.47±1.73 years while 19.07±1.98 years was recorded for group Class I: Female (n=30). The following tables are showing the analyzed results with interpretations

**Table 1-THE DISTRIBUTION OF AGE OF SUBJECTS WITH NORMAL OCCLUSION; GROUP I**

Age (year)	Class I: Male		Class I: Female	
	N	%	n	%
15-17	0	0.0	1	6.7
17-19	5	33.3	5	33.3
19-21	6	40.0	5	33.3
21-23	4	26.7	4	26.7
<b>Total</b>	<b>15</b>	<b>100.0</b>	<b>15</b>	<b>100.0</b>

Most of the male with normal occlusion in group Class I: Male (40.0%) and Class I: Female (33.3%) had belonged to age group of 19-21 years while 33.3% subjects each in malocclusion group Class I: Male and Class I: Female found with age ranges from 17-19 years. 26.7% subjects in malocclusion group Class I: Male while the same proportion in malocclusion group Class I: Female had belonged to age group of 21-23 years

**Figure 5: THE DISTRIBUTION OF AGE OF SUBJECTS WITH SKELETAL CLASS-I OCCLUSION; GROUP I**



**Table 2:** COMPARISON FOR VARIOUS PARAMETERS BETWEEN RIGHT AND LEFT SIDE IN NORMAL OCCLUSION

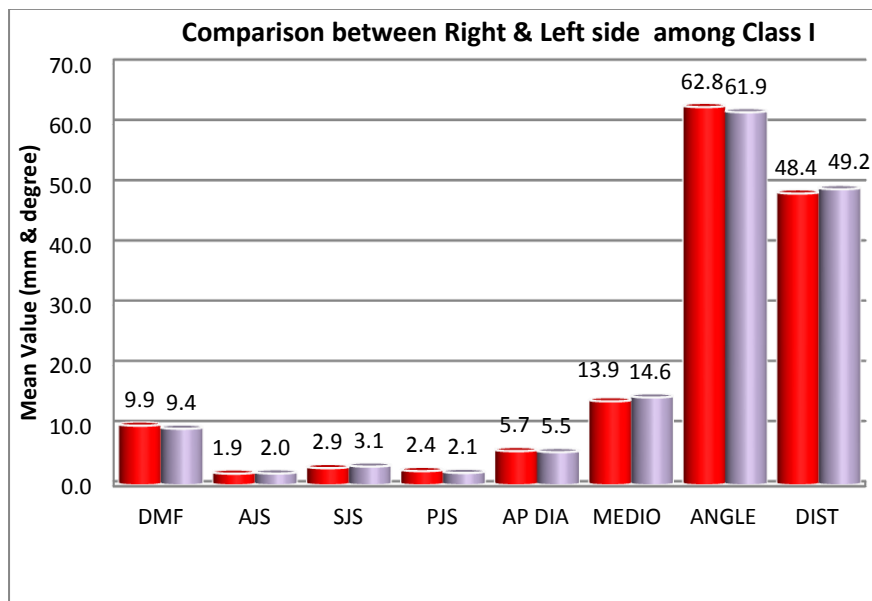
Parameter	Side	Spread	MD	t-value	LOS
		Mean±SD			
<i>Depth of mandibular Fossa (mm)</i>	Right	9.91±1.60	0.51 mm	<b>2.23</b>	p<0.05 *
	Left	9.40±1.17			
<i>Anterior joint space (mm)</i>	Right	1.94±0.61	0.03 mm	<b>0.22</b>	p>0.05 ⊗
	Left	1.97±0.68			
<i>Superior joint space (mm)</i>	Right	2.85±1.00	0.26 mm	<b>1.45</b>	p>0.05 ⊗
	Left	3.11±1.11			
<i>Posterior joint space (mm)</i>	Right	2.37±0.92	0.31 mm	<b>1.98</b>	p<0.06 ^
	Left	2.06±0.56			
<i>Anteroposterior diameter of condylar process (mm)</i>	Right	5.68±1.24	0.17 mm	<b>1.14</b>	p>0.05 ⊗
	Left	5.51±1.09			
<i>Mediolateral diameter of condylar process (mm)</i>	Right	13.95±2.76	0.64 mm	<b>1.22</b>	p<0.03 *
	Left	14.59±3.30			
<i>Angle condylar process and mid sagittal plane (°)</i>	Right	62.80±17.81	0.87 °	<b>0.32</b>	p>0.05 ⊗
	Left	61.93±13.86			
<i>Distance, Condylar process and mid sagittal plane (mm)</i>	Right	48.44±4.61	0.72 Mm	<b>1.04</b>	p>0.05 ⊗
	Left	49.16±3.21			

The mean differences are significant at the 0.03 and 0.05 levels of significance. ^ The mean differences are poorly/suggestively significant at the 0.06 level of significance.

⊗ The mean differences are not significant (insignificant) at the 0.05 level of significance.

[Degrees of freedom is 29; Std. Deviation; MD-Mean Difference; LOS-Level of Significance]

**Figure 6:** MULTIPLE BAR DIAGRAM SHOWED THE COMPARISON BETWEEN RIGHT AND LEFT SIDE AMONG CLASS I SUBJECTS TO PRESENT THE MORPHOLOGY OF TMJ



## DISCUSSION

Knowledge of the anatomy of the TMJ is an extremely important component of the diagnostic process; it will help us to determine which imaging technique is the most appropriate in the study of morphology of Temporomandibular joint.

The radiographic images of the temporomandibular joint demonstrated that the shape of the condyle was slightly convex in most cases and that was a positive correlation between depth of glenoid fossa and inclination of the posterior slope of the articular eminence, indicating that the greater the depth of the glenoid fossa, the greater the inclination of the posterior slope of the eminence. The mandibular condyle is convex along the surface that receives the force, wider in the medio-lateral dimension, and has an oval shape antero-posteriorly. This observation and others, such as the relation of the articular disc with the condyle and the temporal bone, muscle attachments, and occlusion, requires a 3-D approach to analyze the TMJ complex.<sup>8-12</sup>

The need of present study is to complete evaluation of morphology of Temporomandibular joint with taking in consideration various parameter of TMJ by Three Dimensional technology that is cone beam computed tomography.

Derived datas were evaluated by suitable stastical analysis and the following conclusions were derived.

## COMPARISON FOR VARIOUS PARAMETERS BETWEEN RIGHT AND LEFT SIDE IN NORMAL OCCLUSION

In this study subjects with normal occlusion (Class I) The mean depths of the mandibular fossa in right side was significantly ( $p < 0.05$ ) higher than left side. The differences in mean mediolateral diameter of condylar process was ( $p < 0.03$ ) statistically highly significant. So, the depth of mandibular fossa and mediolateral diameter of condylar process may be used

as important significant indices to assess the morphology of the temporomandibular joints in subjects with normal occlusion (Class I).

My study favour the result obtained by the study done by **F Rodrigues, et al**<sup>12</sup> the linear measurement of the mediolateral diameter of the condylar process showed a statistically significant

difference between the right and left sides. There were no significant differences between both sides in the other measurements.

My study contradict the result obtained by the study done by Prabhat KC et al, Verma SK et al.<sup>13</sup> There was no difference in the condylar process and joint morphology between right and left sides of both Angle's Class I normal occlusion. Evaluation of the position of the condyles in their respective mandibular fossae showed concentric position with a tendency towards anterior positioning for

both right and left sides of the subjects with Angle's Class normal occlusion.

## THE ANTEROPOSTERIOR DIFFERENCE BETWEEN THE GEOMETRIC CENTER OF THE RIGHT AND LEFT CONDYLAR PROCESSES IN SUBJECTS WITH NORMAL OCCLUSION

Most of the male (60.0%) and female (53.3%) with normal occlusion found with geometric centers situated anterior to the 0 point reflected positive. Approximately one-third male (26.7%) but exactly one-third female (33.3%) with normal occlusion found with geometric center of the right condylar process with 0 point reflected concentric. Two male and female found negative as situated posterior to the 0 point.

## CONCLUSION

Present study was carried out the morphology of TMJ of (normal occlusion) skeletal class-I by cone beam computed tomography. Total of 30 subjects were equally distributed in two groups. All the subject were investigated for CBCT scan as well as lateral cephalogram and they were evaluated for all the variable related with the TMJ morphology.

However within the limitations of the study, stastical figures show the following conclusion

- ❖ The depth of mandibular fossa may be used as important significant indices to assess the morphology of the temporomandibular joints in subjects with normal occlusion.
- ❖ The mediolateral diameter of the condylar process of TMJ can also be used in subjects with normal occlusion to assess the morphology of the
- ❖ There were no significant mean differences found for all parameters in right side and left side of subjects, when skeletal class I.
- ❖ In the evaluation of centralization of the condyle on the right side in subjects with skeletal class I occlusion the mean values was statistically significant where as on the left side the mean values were not significant.
- ❖ The right side anteroposterior diameter of condylar process in class I subjects found strongly correlated and highly significant with left side.
- ❖ The anteroposterior difference between the geometric center of the right & left condylar processes in skeletal class-I found with geometric center situated anterior to the zero point reflected positive
- ❖ Anteroposterior differences between the geometric center of the right and left condylar processes class I subjects, The concentric was greater and positive in normal occlusion.

### Male and Female Distribution

- ❖ The posterior joint space right side may be used as the significant indices to access the morphology of TMJ in male.
- ❖ The superior joint space in left side may be used as significant indices to access the morphology of TMJ in male
- ❖ In female it was concluded that there were not any statistically significant differences identified in any of the parameters in right & left side in class-I.

### REFERENCES

1. Robbert Murray Rickets. A study of changes in temporomandibular relation associated with the treatment of class II malocclusion Angle ortho.1952;918-933.
2. Mongini F. Modificazioni dell'articolazione temporo-mandi Burley MA. An examination of the relation between the radiographic appearance of temporomandibular joint and some features of the occlusion Br Dent J 1961;110:195-200.
3. Blackwood HJ. Pathology of the TM joint. J Am Dent Assoc 1969; 79:118-24.
4. Mongini F. Remodelling of the mandibular condyle in the adult and its relationship to the condition of the dental arches. Acta Anat (Basel) 1972; 82:437-53.
5. Benget et al Relation between height of the articular tubercle of the TMJ and facial morphology 1974;44:1:15-24.
6. Mongini F. Dental abrasion as a factor in remodeling of the mandibular condyle. Acta Anat (Basel) 1975;92:292-300.
7. Franco Mongini, Anatomic and clinical evaluation of the relationship between the temporomandibular joint and occlusion .J prosthetic dentistry-1977-38;5;539-551.
8. Wedel A, Carlsson G, Sagne S. Temporomandibular joint morphology in a medieva skull material. Swed Dent J 1978;2:177.
9. Ben-Bassat Y, Yaffe A, Brin I, Freeman J, Ehrlich Y. Functional and morphological occlusal aspects in children treated for unilateral posterior cross-bite. Eur J Orthod 1993;15:57-63.
10. O'Byrn BL, Sadowsky C, Schneider B, Begole EA. An evaluation of mandibular asymmetry in adults with unilateral posterior crossbite. Am J O-DO 1995;107:394-400.
11. Kapil., RS Conley and WE Harrell - The current status of cone beam computed tomography imaging in orthodontics . Dentomaxillofac Radiol. 1998-06-01.
12. Rodrigues AF, Fraga MR, Vitral RWF. Computed Tomography evaluation of the TMJ in Class I mal occlusion patient. Condylar Symmetry & Condyle -Fossa relationship. AJO- DO 2009; 136:199-06 .
13. Prabhat ZC, Verma SK. Computed tomography evaluation of Cranio mandibular articulation in class II division I malocclusion and class I normalocclusion subjects in north Indian. Population. International Scholarly Research Network (ISRN) Dentistry Volume 2012, Article ID 312031, 5 pages.

**Source of support:** Nil

**Conflict of interest:** None declared

This work is licensed under CC BY: **Creative Commons Attribution 3.0 License.**