

## Original Article

### Infectious Endocarditis- Microscopic and Clinical Finding in Pediatric Patients

Girjesh Kumar Singh

Assistant Professor, Department Of Pediatrics, Hind Institute Of Medical Sciences, Safedabad, Barabanki, U.P

#### ABSTRACT:

**Background:** Infectious endocarditis (IE) is a fatal disease in pediatric patients. Patients usually have underlying hemodynamic problems that predispose them to the risks of IE. The present study was conducted to assess the cases of Infectious endocarditis in pediatric patients. **Materials & Methods:** The present study was conducted in the department of pediatrics. It comprised of 24 cases of IE in children. Symptoms, signs, laboratory findings etc. were recorded. All were subjected to echocardiography which was studied by cardiologists. **Results:** Out of 24 patients, males were 16 and females were 8. The difference was significant ( $P < 0.05$ ). Age group 1- 5 years had 4 males and 3 females, 6- 10 years had 6 males and 2 females, 11-15 years had 4 males and 2 females and 15- 20 years had 2 males and 1 female. The difference was non- significant ( $P = 0.5$ ). Common symptoms were fever seen in 15 males and 4 females, microscopic hematuria in 15 males and 3 females, pulmonary embolism in 10 males and 2 females, Janeways lesion in 4 males and 2 females, ARF in 2 males and 1 female and hepatitis in 1 male and 1 females each. The difference was significant ( $P < 0.05$ ). Common bacteria involvement was streptococcus (24%), pneumococcus (16%), staphylococcus (10.5%), pseudomonas aeruginosa (5%), candida albican (2.5%) and unknown causes in 42%. **Conclusion:** Infective endocarditis is a fatal disease occurs mostly in pediatric patients. Common symptoms are fever, microscopic hematuria, pulmonary embolism etc.

**Key words:** Infective endocarditis, Pseudomonas aeruginosa, Staphylococcus

Received: 08 May 2018

Revised: 24 May 2018

Accepted: 26 May 2018

**Corresponding Author:** Dr Girjesh Kumar Singh, Assistant Professor, Department Of Pediatrics, Hind Institute Of Medical Sciences, Safedabad, Barabanki, U.P., India

**This article may be cited as:** Singh GK. Infectious Endocarditis- Microscopic and Clinical Finding in Pediatric Patients. J Adv Med Dent Scie Res 2018;6(6):76-79.

#### INTRODUCTION

Infectious endocarditis (IE) is a rare, but potentially fatal disease in pediatric patients. Most patients have underlying hemodynamic problems that predispose them to the risks of IE. Infective endocarditis is an infection of the inner surface of the heart, usually the valves. Though Streptococcus viridians and Staphylococcus aureus are the main pathogens of the disease, other pathogens have also been isolated.<sup>1</sup>

Symptoms may include fever, small areas of bleeding into the skin, heart murmur, feeling tired, and low red blood cell count. Complications may include valvular insufficiency, heart failure, stroke and kidney failure. Modified Duke criteria are commonly used for clinical diagnosis of IE.

The cause is typically a bacterial infection and less commonly a fungal infection. Risk factors include rheumatic heart disease, congenital heart disease, artificial valves, intravenous drug use and electronic pacemakers. The number of people affected is about 5/100,000 per year. Males are affected more often than females. The risk of death among those infected is about 25%. Without treatment it is almost universally fatal.<sup>2</sup>

Bacteria such as streptococcus viridians and staphylococcus aureus are present in the normal oral flora and enter the bloodstream usually by dental surgical procedures or genitourinary manipulation; as such, dental surgeons must fully carry out protective and preventive measures. High risk patients may be given prophylactic antibiotics such as penicillin or clindamycin for penicillin allergic patients

prior to dental procedures. Prophylactics should be bactericidal rather than bacteriostatic.<sup>3</sup> The present study was conducted to assess the cases of Infectious endocarditis in pediatric patients.

**MATERIALS & METHODS**

The present study was conducted in the department of pediatrics. It comprised of 24 cases of IE in children. All

were informed regarding the study and written consent was obtained. Ethical clearance was taken prior to the study. General information such as name, age, gender etc. was recorded. Symptoms, signs, laboratory findings etc. were recorded. All were subjected to echocardiography which was studied by cardiologists. Results thus obtained were subjected to statistical analysis using chi- square test. P value less than 0.05 was considered significant.

**RESULTS**

**Table I Distribution of patients**

		Total- 24	
Males	Females	P value	
16	8	0.01	

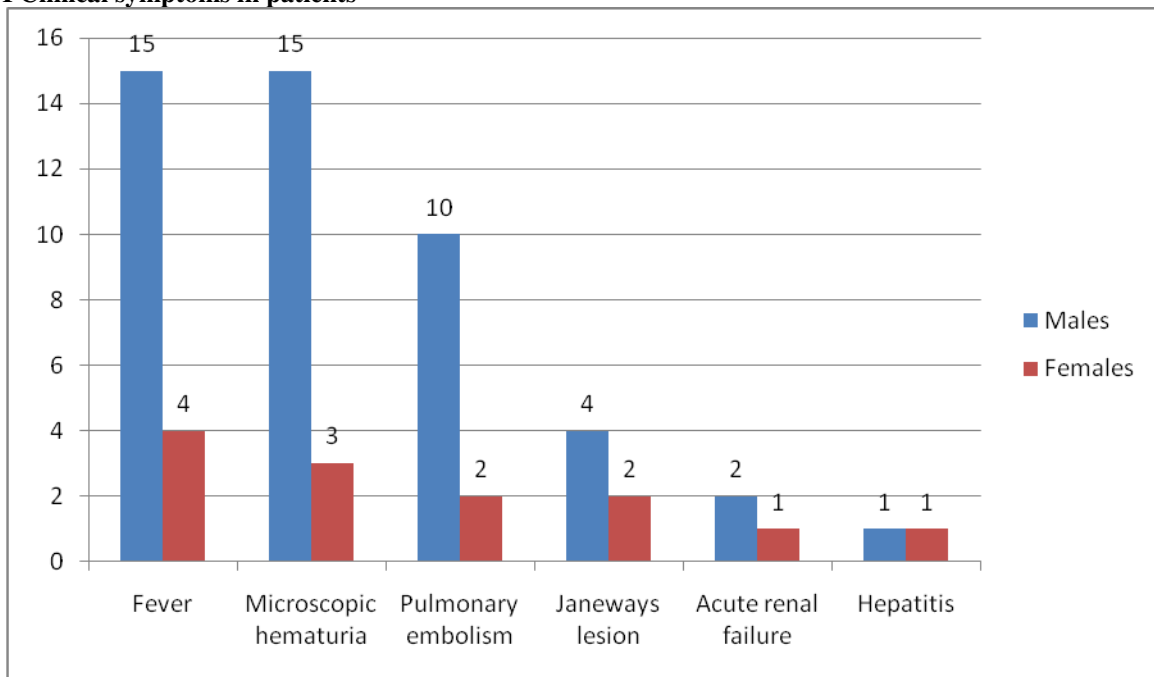
Table I shows that out of 24 patients, males were 16 and females were 8. The difference was significant (P< 0.05).

**Table II Age wise distribution of cases**

Age group (years)	Males	Females	P value
1- 5	4	3	0.5
6-10	6	2	
11-15	4	2	
15- 20	2	1	

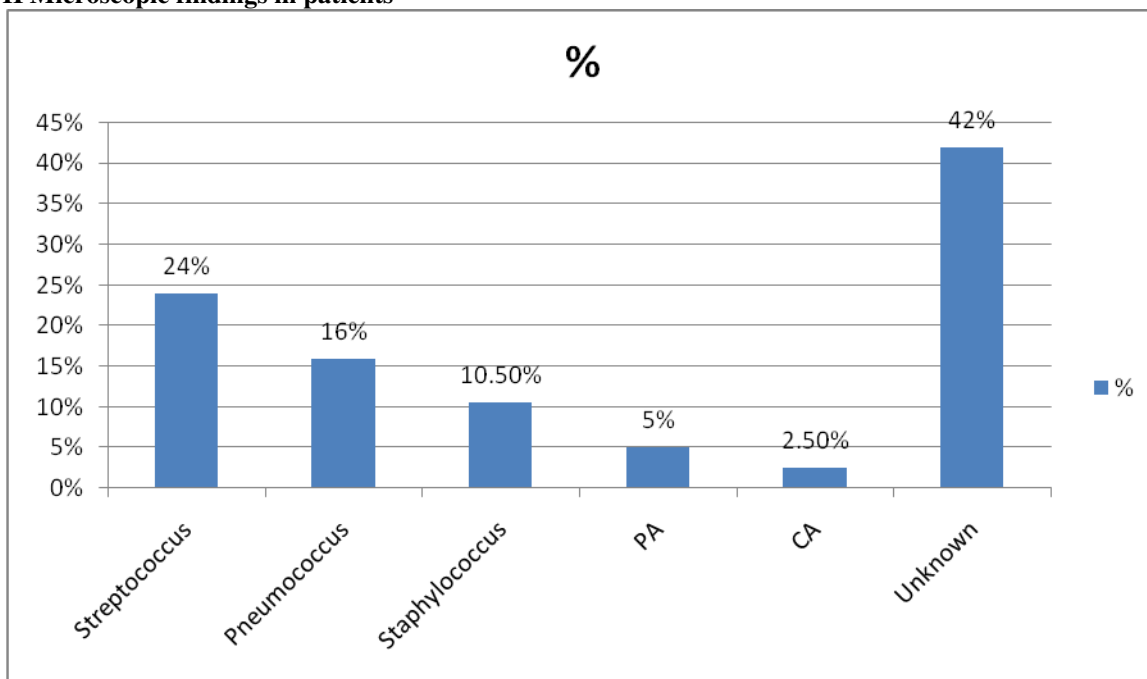
Table II shows that age group 1- 5 years had 4 males and 3 females, 6- 10 years had 6 males and 2 females, 11-15 years had 4 males and 2 females and 15- 20 years had 2 males and 1 female. The difference was non- significant (P- 0.5).

**Graph I Clinical symptoms in patients**



Graph I shows that common symptoms were fever seen in 15 males and 4 females, microscopic hematuria in 15 males and 3 females, pulmonary embolism in 10 males and 2 females, Janeways lesion in 4 males and 2 females, ARF in 2 males and 1 female and hepatitis in 1 male and 1 females each. The difference was significant (P< 0.05).

**Graph II Microscopic findings in patients**



Graph II shows that common bacteria involvement was streptococcus (24%), pneumococcus (16%), staphylococcus (10.5%), pseudomonas aeruginosa (5%), candida albican (2.5%) and unknown causes in 42%.

**DISCUSSION**

The precise incidence of IE in pediatric patients is difficult to ascertain because case definitions have varied from decade to decade. Studies have shown that common findings are heart murmur, weight loss, and coughing occurs in 35% of people. Vascular phenomena involves septic embolism, Janeway lesions (painless hemorrhagic cutaneous lesions on the palms and soles), splenic infarcts, intracranial hemorrhage, conjunctival hemorrhage, splinter hemorrhages and kidney infarcts. Other findings are Osler's nodes ie. painful subcutaneous lesions in the distal fingers, Roth's spots on the retina, positive serum rheumatoid factor etc.<sup>4</sup>

In present study, out of 24 patients, males were 16 and females were 8. age group 1- 5 years had 4 males and 3 females, 6- 10 years had 6 males and 2 females, 11-15 years had 4 males and 2 females and 15- 20 years had 2 males and 1 female. This is in agreement with Johnson et al.<sup>5</sup>

We found that common bacteria involvement was streptococcus (24%), pneumococcus (16%), staphylococcus (10.5%), pseudomonas aeruginosa (5%), Candida albican (2.5%) and unknown causes in 42%. This is similar to Griffin et al.<sup>6</sup>

Fever, prostration and the presence of cardiac murmurs were noted in over of the cases, as has also been observed by various authors.<sup>7,8</sup> Splenomegaly, which is related to the presence of prolonged bacteremia leading to a

hypertrophied reticulo-endothelial system, occurred in 27.7% of the cases studied by Mckinsey et al.<sup>9</sup> Due to the

increased frequency of acute infections by S. aureus and the reduction of the period between onset and diagnosis of IE, splenomegaly is being observed less and less.

Cherubin et al<sup>10</sup> in their study found that nineteen cases in age from 2.5 months to 18 years were involved in the study. 52.9% had microscopic hematuria and two out of three (66.7%) cases showed elevated rheumatoid factor levels. 89.5% had fever and 36.8% had major vessel embolic events. Blood cultures yielded Staphylococcus aureus in seven cases, and viridans Streptococci in two cases. The other three cases had Pneumococcus, Pseudomonas aeruginosa and Candida albicans. The initial C-reactive protein levels in the blood culture-positive group were significantly higher than those in the blood culture-negative. Everaldo et al<sup>11</sup> in their study found 180 cases of infectious endocarditis. Echocardiograms in 132 (73.3%) provided a diagnosis of infectious endocarditis in 111 (84%) patients; mitral valves were affected in 55 (30.5%), tricuspid valves in 30 (16.6%) and the aortic valve in 28 (15.5%) patients. Hemocultures were performed in 148 (93.8%) episodes of IE. The most commonly isolated infectious organisms were Staphylococcus aureus in 46 (27.2%) patients and Streptococcus viridans in 27 (15.9%). Complications occurred in 116 (64.4%) patients and 73 (40.5%) of the patients died.

## CONCLUSION

Infective endocarditis is a fatal disease occurs mostly in pediatric patients. Common symptoms are fever, microscopic hematuria, pulmonary embolism etc.

## REFERENCES

1. Durack DT, Lukes AS, Bright DK. Duke endocarditis service. New criteria for active infective endocarditis: utilization of specific echocardiographic findings. *Am J Med* 1994; 96: 2000-9.
2. Lamas, CC, Eykyn SJ. Suggested modifications to the Duke Criteria for the clinical diagnosis of native and prosthetic valve endocarditis: analysis of 118 pathologically proven cases. *Clin Infect Dis* 1997; 25: 713-9.
3. Nettles RE, McCarty DE, Corey GR, Li J, Sexton DJ. An evaluation of the Duke criteria in 25 pathologically confirmed cases of prosthetic valve endocarditis. *Clin Infect Dis* 1997;1401-3.
4. Mansur AJ, Grinberg M, Bellotti G, Jatene A, Pileggi F. Infective endocarditis in the 1980s: experience at a heart hospital. *Clin Cardiol* 1990; 13: 623-30.
5. Johnson CM, Rhodes KH. Pediatric endocarditis. *Mayo Clin Proc* 1982;57:86-94.
6. Griffin MR, Wilson WR, Edwards WD, O'Fallon WM, Kurland LT. Infective endocarditis in Olmsted County, Minnesota, 1950 through 1981. *JAMA* 1985; 254:1199-202.
7. Raoult D, Casalta JP, Richet H, Khan M, Bernit E, Rovey C, et al. Contribution of systematic serological testing in diagnosis of infective endocarditis. *J Clin Microbiol* 2005;43:5238-42.
8. Werner M, Andersson R, Olaison L, Hogevik H. A clinical study of culture-negative endocarditis. *Medicine (Baltimore)* 2003; 82: 263-73.
9. McKinsey DS, Ratts TE, Bisno AL. Underlying cardiac lesions in adults with infective endocarditis. The changing spectrum *Am J Med* 1987;82:681-8.
10. Cherubin CE, Neu HC. Infective endocarditis at the Presbyterian Hospital in New York City from 1938-1967. *Am J Med* 1971; 51:83-96.
11. Tornos MP, Permanyer-Miralda G, Olona M, Gil M, Galve E, Almirante B, et al. Long-term complications of native valve infective endocarditis in non-addicts: a 15-year follow-up study. *Ann Intern Med* 1992;117:567-72.

**Source of support:** Nil

**Conflict of interest:** None declared

This work is licensed under CC BY: *Creative Commons Attribution 3.0 License*.