

Review Article

Evaluation of Outcomes of Recent Materials Used for Single Visit Apexification

Karuna Ramnani¹, Rajesh Shetty², Soumya Shetty³

¹Post Graduate Student, ²Professor, ³Reader

Department of Conservative Dentistry & Endodontics, Dr. D. Y. Patil Dental College & Hospital, Pimpri, Pune 411018, Maharashtra, India.

ABSTRACT:

Background: To evaluate outcomes of recent materials Used for Single Visit Apexification.

Objectives: To assess the clinical and radiographical outcomes of MTA and Biodentine when used for single visit apexification.

Data Source: Two internet sources of evidence were used in the search of appropriate papers satisfying the study purpose: the National Library of Medicine (MEDLINE PubMed) and Google Scholar.

Study Eligibility Criteria: The following criteria was used to select the studies:

1. The Inclusion criteria were article in English having detailed summary were searched, and studies published between 1st January 2005 to 31st December 2016 were selected, Studies which give information about Grey MTA, White MTA and Biodentine used for single visit Apexification, Studies done on adults aged more than 18 years, case reports and clinical studies for Apexification.
2. The exclusion criteria were review, abstracts, letters to editors, editorials and in vitro studies and Studies assessing different materials used for multiple visit apexification.

Intervention: Outcome of single visit apexification with recent materials (MTA and Biodentine)

Results: 78 articles out of which 15 articles were selected. The papers were screened, as a second step, full text papers were obtained when they fulfilled the criteria of the study aim. However, articles which assessed the clinical and radiographical outcomes of MTA and Biodentine when used for single visit apexification were selected. Finally a total of 11 articles were included of which 5 were selected for this review.

Limitations: There are few limitations not addressed in the studies. There were limited full text articles available for this study to analyze.

Conclusion: On comparing outcome of MTA and biodentine for single visit apexification, Biodentine showed greater properties and hence can be considered a novel material for single visit apexification procedures.

Future Implications: Further comparative studies are required.

Key Words: Apexification, single visit, MTA, biodentine.

Received: 06 May 2018

Revised: 24 May 2018

Accepted: 25 May 2018

Corresponding Author: Dr. Karuna Ramnani, Post Graduate Student, Department of Conservative Dentistry & Endodontics, Dr. D. Y. Patil Dental College & Hospital, Pimpri, Pune 411018, Maharashtra, India.

This article may be cited as: Ramnani K, Shetty R, Shetty S. Evaluation of Outcomes of Recent Materials Used for Single Visit Apexification. J Adv Med Dent Scie Res 2018;6(6):76-80.

INTRODUCTION

Dental caries and trauma are the most common challenges to the integrity of the tooth as it matures. Both insults can render the pulp non-vital. If this occurs prior to the root formation and apical closure, normal root development is halted.¹

Clinically, there are several conditions associated with treating teeth that have a widened or open apical foramen. For one the apical diameter of the canal is always larger

than the coronal diameter, so debridement is difficult. In addition, the lack of an apical stop makes obturation in all dimensions virtually impossible. Finally the thin walls of the root canal are prone to fracture, so that surgical treatment is generally not a viable option.²

To avoid these complications, apexogenesis (vital pulp therapy) is indicated to encourage continued physiological development and formation of the root end. When the insult to the pulp has caused pulpal necrosis, alternative

treatment must be considered i.e apexification, which is defined by the AAE Glossary as “a method of inducing a calcified barrier in a root with an open apex or the continued apical development of an incompletely formed root in teeth with necrotic pulp.”

The main difficulty encountered is the lack of an apical stop against which to compact an interim dressing of calcium hydroxide (Ca(OH)₂), or the final obturation material. In these situations the unpredictability of the result, the difficulty in creating a leak-proof temporary restoration for the duration of treatment, and the difficulty in protecting the thin root from fracture may lead to complications when using traditional (Ca(OH)₂ -based) apexification techniques. Furthermore, given the increased mobility of today’s society, lengthy treatment protocols are fraught with problems, and may not be followed through to completion. This may lead to ultimate failure of the case.

Mineral Trioxide Aggregate (MTA) has been introduced for use in endodontics. Current literature supports its efficacy in a multitude of procedures including apexification. A one-visit apexification protocol with MTA can be seen as an alternative to the traditional treatment practices with Ca(OH)₂.

Materials previously considered for apical barriers include dentin chips, freeze-dried cortical bone/dentin, calcium phosphate and calcium hydroxide which are efficient in creating a barrier for obturation in one appointment but do not provide a well-sealed environment. Thus Mineral Trioxide Aggregate has been advocated for use as an apical barrier because of its sealing capabilities, ability to set in the presence of moisture, its biocompatibility and ability to induce hard tissue formation.³ Also, recently a novel material named Biodentine has been introduced by Septodont in September 2010. Biodentine is similar to MTA in its basic composition with the addition of setting accelerators which is calcium chloride not only results in fast setting but also improves the handling properties and strength. Biodentine is superior to MTA like its consistency is better suited to the clinical use, ensures a better handling and safety, does not require a two-step obturation and as the setting is faster, there is a lower risk of bacterial contamination.⁴

METHOD

ELIGIBILITY CRITERIA

Inclusion Criteria: This included articles and studies based on some fixed guidelines.

1. Articles in English or those having detailed summary in English
2. Studies published between 1st January 2005 and 31st December 2016.

3. Studies which give information about Grey MTA, White MTA and Biodentine used for single visit apexification.
4. Studies done on adults aged more than 18 years.
5. Case reports and clinical studies for Apexification

Exclusion Criteria:

1. Review, abstracts, letters to editors, editorials and in vitro studies are excluded.
2. Studies assessing different materials used for multiple visit apexification

The PICOS guidelines that were selected are:

P comprised of people of age group more than 18 years. I as the Intervention where this was considered as Single visit apexification. C as comparison and this review aimed to compare Biodentine and MTA used for single visit apexification. O as the outcome where it assessed the radiographic and clinical outcomes of Apexification. And hence the PICOS are mentioned below:

- P - Participants: People of age group more than 18 years
- I - Intervention: single visit Apexification
- C- Comparison: Biodentine and MTA for single visit Apexification
- O- Outcome: Apexification
- S - Study design: Clinical

INFORMATION SOURCES

Two internet sources of evidence were used in the search of appropriate papers satisfying the study purpose: the National Library of Medicine (MEDLINE PubMed) and Google Scholar. All cross reference lists of the selected studies were screened for additional papers that could meet the eligibility criteria of the study. The databases were searched including January 2005 to December 2016 using the search strategy.

SEARCH

Primary keywords	Secondary keywords
Apexification	Apical barrier , Root end filling materials
Single visit	One visit, Same visit
MTA	
Biodentine	Grey MTA, White MTA, ProRoot MTA, MTA Angelus

Sr. No.	Search Strategies	Number of articles	Selected	After Duplicates removal
1.)	apexification AND single visit AND MTA	8	2	
2.)	apexification AND single visit AND Biodentine	5	1	
3.)	Apical barrier AND single visit AND MTA	7	2	1
4.)	Apical barrier and single visit and Biodentine	5	1	1
5)	MTA AND single visit AND apical barrier OR apexification	53	1	
	TOTAL	78	7	5

STUDY SELECTION

Preliminary screening consisted total of 78 articles out of which 15 articles were selected. The papers were screened independently by two reviewers. At first the papers were screened by title and abstract. As a second step, full text papers were obtained when they fulfilled the criteria of the study aim. Any disagreement between the two reviewers was resolved after consensus. For full-text screening, the following criteria were taken into consideration: In vivo studies and case reports were selected; however, only articles where clinical and radiographic outcomes after using MTA or Biodentine in single visit apexification cases were assessed. Finally a total of 5 articles were included.

DATA COLLECTION PROCESS

A standard pilot form in excel sheet was initially used and then all those headings not applicable for review were removed. Data extraction was done for one article and this form was reviewed by an expert and finalized. This was followed by data extraction for all the articles.

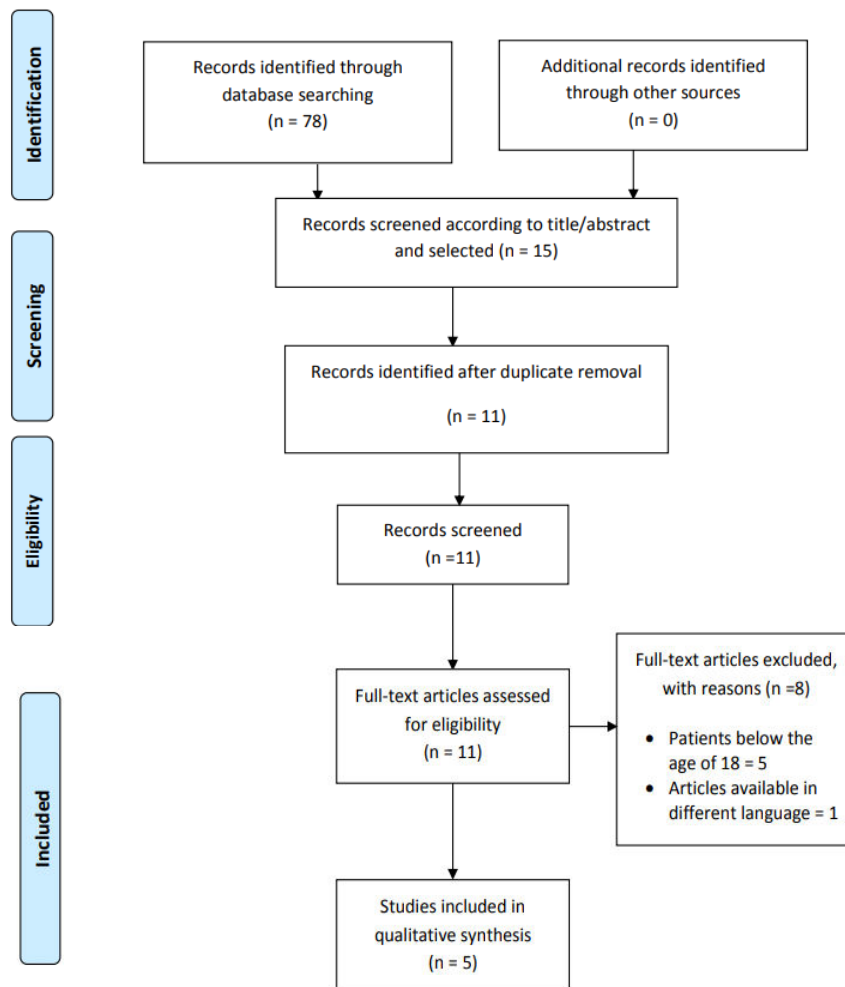
DATA ITEMS

The data items included were

1. Author – The name of the author
2. Year of publication – The year in which the study was published
3. Material used – the material used for single visit apexification procedure.
4. Tooth type – which teeth were used in different studies.
5. Sample size – No. of participants included in the study
6. Evaluation technique – techniques used to evaluate the outcomes i.e clinical and radiographic techniques.
7. Follow ups – patient recalled after a certain duration of time period to assess the improvement of the procedure.
8. Authors Conclusion– Result of the study
9. Remarks – comments of the author.

STUDY SELECTION

PRISMA 2009 Flow Diagram



DISCUSSION

The completion of root development and closure of the apex occurs up to 3 years after eruption of the tooth.⁵ The treatment of pulpal injury during this period provides a significant challenge for the clinician. Depending upon the vitality of the affected pulp, two approaches are possible – apexogenesis or apexification. Apexogenesis is ‘a vital pulp therapy procedure performed to encourage continued physiological development and formation of the root end’.⁶ Apexification is defined as ‘a method to induce a calcified barrier in a root with an open apex or the continued apical development of an incomplete root in teeth with necrotic pulp’.⁷ As always, success is related to accurate diagnosis and a full understanding of the biological processes to be facilitated by the treatment.

Apexification has been carried out from long time where calcium hydroxide is the widely used material. Calcium hydroxide gained the widest popularity. It is bactericidal in nature with an alkaline pH that may be responsible for stimulating apical calcification. Despite its widest acceptance, it has some disadvantages including variability of treatment time, difficulty in patients follow up, delayed healing, needs multiple visits to the completion to induction of calcific barrier formation and it weakens the dentin of root. Thus, the scientists and clinicians felt urge to introduce new materials and techniques that will help to the quick resolution of the apical radiolucency and to form the apical barrier. MTA (mineral trioxide aggregate), a recently introduced material is successfully used in the treatment of apexification. Many renowned scientists and clinicians worked on this materials and got very good results. Recently a clinical study has been published showing the effects of a combined medicament prepared by mixing calcium hydroxide with cefadroxil on the resolution and formation of apical barrier. Although it was a multi visits treatment compared to the treatment with MTA but showed promising results in the treatment of apexification in presence or absence of radiolucency.⁷

Of all the materials available, MTA has been widely used for one-visit apexification. It has attracted considerable attention owing to their superior sealing ability, biocompatibility, regenerative capabilities, and antibacterial properties.^{8,9} Nevertheless, MTA remains subject to some concerns, such as its long setting time, poor handling characteristics, low resistance to compression, low flow capacity, limited resistance to washout before setting, possibility of staining of tooth structure, presence and release of arsenic, and high cost.^{10,11} These disadvantages necessitate more ideal restorative materials, with adequate biological and mechanical properties. Recently, a new calcium silicate-based material, Biodentine (Septodont, Saint-Maur-des-Fossés, France), has been introduced with the intention of preserving the properties and clinical applications of MTA without its negative characteristics.¹⁴

Simon S *et al* (2007)¹² has assessed the outcome of apexification using mineral trioxide aggregate (MTA). 57 teeth with open apices on 50 patients referred for root canal treatment received an apexification procedure in

one appointment with MTA by the same operator. Patients were recalled at 6 months, 12 months and every year thereafter. Blind to the treatment record, two examiners assessed the pre-treatment, post-treatment and control radiographs of the study patients. Forty-three cases were included with at least 12 months follow-up. When considering the PAI score and the decrease in size of the apical lesion, healing occurred in 81% of cases. They concluded that Apexification in one step using an apical plug of MTA can be considered a predictable treatment, and may be an alternative to the use of calcium hydroxide.

Zhu WH *et al* (2008)¹³ in a case report using Mineral Trioxide Aggregate as an apical plug to treat necrotized teeth with open apices has been suggested. This report involves a mandibular first premolar with immature root development. After root canal instrumentation and irrigation with 2.5% NaOCl, calcium hydroxide was placed for 2 weeks. At second visit the apical 4mm of the root canal was filled with MTA. The post-operative period was asymptomatic, and radiographic examination demonstrated apparent regeneration of periapical tissue 30 months after the treatment. The result demonstrated that the use of MTA for apical plugging may be a valid treatment method.

Nayak G *et al* (2013)¹⁴ described in a case report, single visit apexification in a maxillary central incisor with necrotic pulp and open apex using Biodentine as an apical barrier, and a synthetic collagen material as an internal matrix. Following canal cleaning and shaping, calcium hydroxide was placed as an intracanal medicament for 1 month. This was followed by placement of small piece of absorbable collagen membrane beyond the root apex to serve as matrix. An apical plug of Biodentine of 5 mm thickness was placed against the matrix using pre-fitted hand pluggers. The remainder of canal was back-filled with thermoplasticized gutta-percha and access cavity was restored with composite resin followed by allceramic crown. One year follow-up revealed restored aesthetics and function, absence of clinical signs and symptoms, resolution of periapical rarefaction, and a thin layer of calcific tissue formed apical to the Biodentine barrier. They concluded that the positive clinical outcome in this case is encouraging for the use of Biodentine as an apical plug in single visit apexification procedures.

Balasubrahmaniam A *et al* (2014)¹⁵ performed a case report on one visit apexification using a novel dental material Biodentine in a 43 year old patient with respect to maxillary left first incisor which revealed a large blunderbuss canal with associated periapical lesion. Biodentine was mixed according to the manufacturer’s instruction and an apical plug of 5 mm was made with the help of a plugger and the root canal was obturated with termoplastticizedguttapercha and access cavity was sealed with composite resin. They reported remarkable healing of osseous lesion during the follow up visits.

Pace R *et al* (2014)¹⁶ conducted a 10 year study and evaluated the clinical and radiologic outcomes of teeth with necrotic pulp, immature apices, and periapical lesions treated with the mineral trioxide aggregate apical

plug technique. Seventeen single rooted immature teeth were included in the study. The outcome based on clinical and radiographic criteria, was assessed by 2 calibrated investigators using the periapical index. The apical plug with MTA was a successful and effective technique for long term management of this group of teeth with necrotic pulps with immature root development and periapical lesions.

LIMITATIONS

There were limited full text articles available for this study to analyze.

CONCLUSION

On comparing outcome of MTA and biodentine for single visit apexification, Biodentine showed greater properties and hence can be considered a novel material for single visit apexification procedures.

REFERENCES:

1. D. E. Witherspoon, K. Ham. One-Visit Apexification: Technique for Inducing Root-End Barrier Formation in Apical Closures. *PractProcedAesthet Dent* 2001;13(6):455-460
2. Arens DE. Treatment of the incompletely formed root. *Dent J* 1978; 47: 107 – 116.
3. Steinig TH, Regan JD, Gutmann JL. The use and predictable placement of Mineral Trioxide Aggregate in one-visit apexification cases. *Aust Endod J.* 2003; 29(1): 34–42.
4. Ambica K, Chaudhary S, Talwar S, Verma M. Endodontic management of open apex using Biodentine as a novel apical matrix. *Indian J Dent Res.* 2014; 25(4):513-6.
5. Bhasker SN. Orban's oral histology and embryology, 11th edn. St. Louis: Mosby-Year Book; 1991.
6. American Association of Endodontists. Glossary of endodontic terms, 7th edn. Chicago: American Association of Endodontists; 2003.
7. ALI, SM Akkaset *al.* Recent Advancement in the Treatment of Open Apex: Materials and Technique. *City Dental College Journal*, [S.l.], v. 9, n. 2, p. 25-30.2012
8. Parirokh M, Torabinejad M. Mineral trioxide aggregate: a comprehensive literature review - Part I: chemical, physical, and antibacterial properties. *J Endod.* 2010; 36:16–27.
9. Torabinejad M, Parirokh M. Mineral trioxide aggregate: a comprehensive literature review - Part II: leakage and biocompatibility investigations. *J Endod.* 2010; 36:190–202.
10. Parirokh M, Torabinejad M. Mineral trioxide aggregate: a comprehensive literature review - Part III: clinical applications, drawbacks, and mechanism of action. *J Endod.* 2010; 36:400–413.
11. Chang SW. Chemical characteristics of mineral trioxide aggregate and its hydration reaction. *Restor Dent Endod.* 2012; 37:188–193.
12. S. Simon1, F. Rilliard, A. Berdall, P. Machtou. *International Endodontic Journal*, 40, 186–197, 2007.
13. Zhu WH, Pan J, Yong W, Zhao XY, Wang SM. Endodontic treatment with MTA of a mandibular first premolar with open apex: case report. *Oral Surg Oral Med Oral Pathol Oral Radiol Endod* 2008;106:73-75.
14. Nayak G, Hasan MF. Biodentine – a novel dentinal substitute for single visit apexification. *Restor Dent Endod* 2014;39(2):120-125
15. Balasubrahmaniam A, Sabna BS, Kumar MR, Jayasree.S. One visit apexification using a novel dental material Biodentine-a case report. *IOSR-JDMS* 2014; 13(5):90-92.
16. Pace R, Guiliani V, Nieri M, Nasso LD, Pagavino G. Mineral Trioxide Aggregate as apical plug in teeth with necrotic pulp and immature apices: A 10 year case series. *J Endod* 2014; Aug; 40(8):1250-4.

Source of support: Nil

Conflict of interest: None declared

This work is licensed under CC BY: ***Creative Commons Attribution 3.0 License.***