

ORIGINAL ARTICLE

EVALUATION OF STRENGTH OF MAGNETIC RESONANCE IMAGING IN PATIENTS UNDERGOING TREATMENT FOR RHEUMATOID ARTHRITIS: A RETROSPECTIVE ANALYSIS

Nitin Dashrath Wadhvani¹, Niranjan Bapusaheb Patil²

¹Professor and HOD, ²Professor, Department of Radiology, Dr DY Patil Medical College, Kolhapur, Maharashtra

ABSTRACT:

Background: Clinical course and progression of RA has been shown to be modified by biological treatment, mainly with anti-tumour necrosis factor (TNF) α agents. Magnetic resonance imaging (MRI) has been shown to be a highly sensitive technique for the detection of inflammatory soft tissue proliferation, bone oedema and early erosions, and since the implementation of MRI into the clinical practice, numerous cross-sectional papers concerning the MRI-detectable features of RA have been published. Hence; we assessed the effectiveness of MRI scans in patients with rheumatoid arthritis. **Materials & methods:** The present study was conducted in the department of the radiology of the institution and included retrospective assessment 600 patients with RA who underwent clinical assessment with MRI. Synovitis was scored on a 0–3 scale at three different locations: radioulnar joint, radiocarpal joint and intercarpal–carpometacarpal joints (total maximum score 9). A score of 0 is normal, with no enhancement or enhancement up to the thickness of normal synovium, while the scores from 1 to 3 (mild, moderate, severe) refer to increments of one-third of the presumed maximum volume of enhancing tissue in the synovial compartment. Blood samples were collected at some time prior to the MRIs and the presence or absence of RF and serum levels of CRP and anti-CCP antibodies were determined. All the results were analyzed by SPSS software. Chi-square test was used for the assessment of level of significance. **Results:** Percentage of males in group 1 and group 2 was 26 and 21 percent respectively. Mean duration of disease in group 1 and group 2 was 141 and 99 months respectively. Mean number of tender joints in group 1 and group 2 was 7.5 and 10.1 respectively. Significant results were obtained while comparing the mean duration of diseases and mean number of tender joints in group 1 and group 2 respectively. In patients with less than 3 years of diseases duration, in 8.5 percent of the patients in group 1, treatment was unchanged. **Conclusion:** Useful information regarding the treatment therapy is provided by a single MRI done during the phase of treatment.

Key words: MRI, Rheumatoid arthritis

Corresponding author: Dr. Nitin Dashrath Wadhvani, Professor, Department of Radiology, Dr DY Patil Medical College, Kolhapur, Maharashtra

This article may be cited as: Wadhvani ND, Patil NB. Evaluation of strength of magnetic resonance imaging in patients undergoing treatment for rheumatoid arthritis: A retrospective analysis. J Adv Med Dent Scie Res 2016;4(6):90-94.

Access this article online

Quick Response Code



Website: www.jamdsr.com

DOI:

10.21276/jamdsr.2016.4.6.20

INTRODUCTION

Clinical course and progression of RA has been shown to be modified by biological treatment, mainly with anti-tumour necrosis factor (TNF) α agents.^{1,2} Disease remission in rheumatoid arthritis has been traditionally considered when there is no clinical or biochemical evidence of disease activity.³ Rheumatoid arthritis (RA) is a chronic disease that if untreated results not only in pain, but also in progressive joint damage and functional decline. Up to 75% of the joint damage occurs within the first 5 years of disease onset and continues throughout the course of the disease.⁴ Magnetic resonance imaging (MRI) has been shown to be a highly sensitive technique for the detection

of inflammatory soft tissue proliferation, bone oedema and early erosions, and since the implementation of MRI into the clinical practice, numerous cross-sectional papers concerning the MRI-detectable features of RA have been published.⁵⁻⁷ Hence; we retrospectively analyzed the effectiveness of MRI scans of the hand/wrist or feet are utilized in a rheumatology practice to make clinical decisions regarding therapy of patients with RA.

MATERIALS & METHODS

The present study was conducted in the department of the radiology of the institution and included retrospective assessment 600 patients with RA who underwent clinical

assessment with MRI. Ethical approval was taken from the institutional ethical committee in written after explaining the entire research protocol. Clinical assessments were gathered and documented in structured data collection forms. The clinical and lab encounter abstracted was the encounter prior to the MRI being obtained. Coronal T1 and STIR MR images of the affected hands, wrists, or feet were performed with a low-field strength dedicated extremity unit. The extremities imaged were the dominant wrist and/or the most affected joint and/ or an extremity with questionable areas apparent on plain radiographs. The field of view for each sequence was 11 mm and the slice thickness was between 1.05 and 1.1 mm. Images was interpreted by one of four fellowship- trained musculoskeletal radiologists. Synovitis was scored on a 0–3 scale at three different locations: radioulnar joint, radiocarpal joint and intercarpal–carpometacarpal joints (total maximum score 9). A score of 0 is normal, with no enhancement or enhancement up to the thickness of normal synovium, while the scores from 1 to 3 (mild, moderate, severe) refer to increments of one-third of the presumed maximum volume of enhancing tissue in the synovial compartment. Blood samples were collected at some time prior to the MRIs and the presence or absence

of RF and serum levels of CRP and anti-CCP antibodies were determined. Anti-CCP antibodies were detected using ELISA with the second generation CCP test. ESR was also measured for each patient. RF and CCP were considered to be negative if they were less than 20 units. All the results were analyzed by SPSS software. Chi-square test was used for the assessment of level of significance.

RESULTS

Graph 1 shows the demographic details of the patients. Mean age of the patient sin group 1 and group 2 was 53.2 and 50.1 years respectively. Percentage of males in group 1 and group 2 was 26 and 21 percent respectively. Mean duration of disease in group 1 and group was 141 and 99 months respectively. Mean number of tender joints in group 1 and group 2 was 7.5 and 10.1 respectively. **Table 1** shows p-value for the demographic details of the patients. Significant results were obtained while comparing the mean duration of diseases and mean number of tender joints in group 1 and group 2 respectively. **Graph 2** shows RA treatment status in patients after baseline MRI. In patients with less than 3 years of diseases duration, in 8.5 percent of the patients in group 1, treatment was unchanged.

Graph 1: Demographic details of the patients

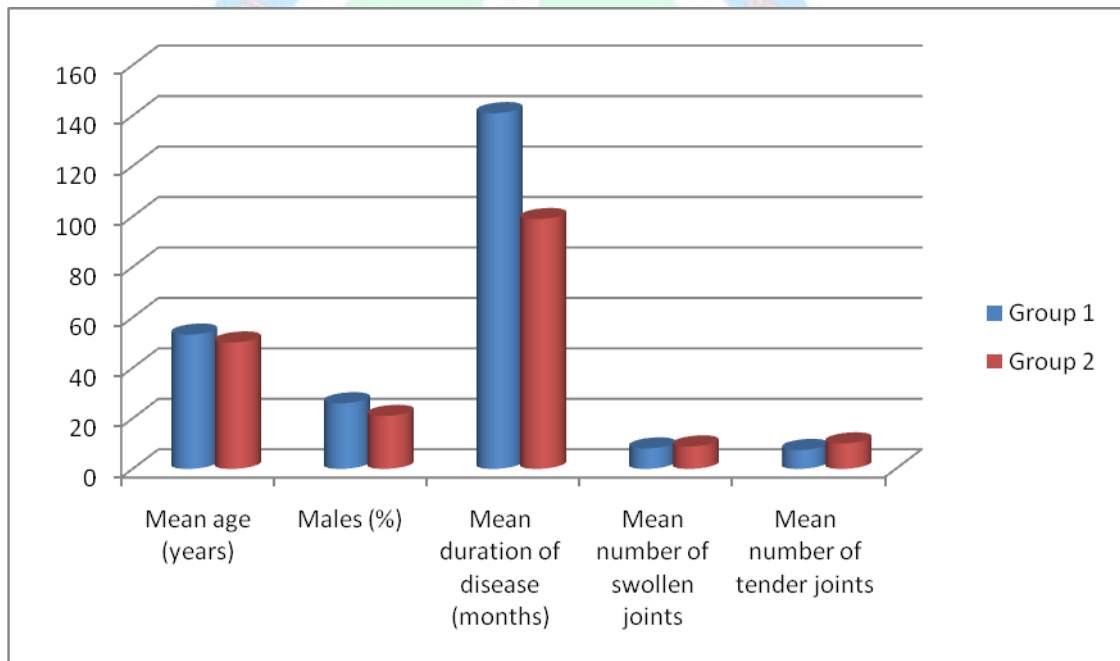


Table 1: p-value for the demographic details of the patients

Parameter	Group 1	Group 2	p-value
Mean age (years)	53.2	50.1	0.25
Males (%)	26	21	0.12
Mean duration of disease (months)	141	99	0.02*
Mean number of swollen joints	8.1	8.9	0.52
Mean number of tender joints	7.5	10.1	0.02*

*: Significant

Graph 2: RA treatment status in patients after baseline MRI

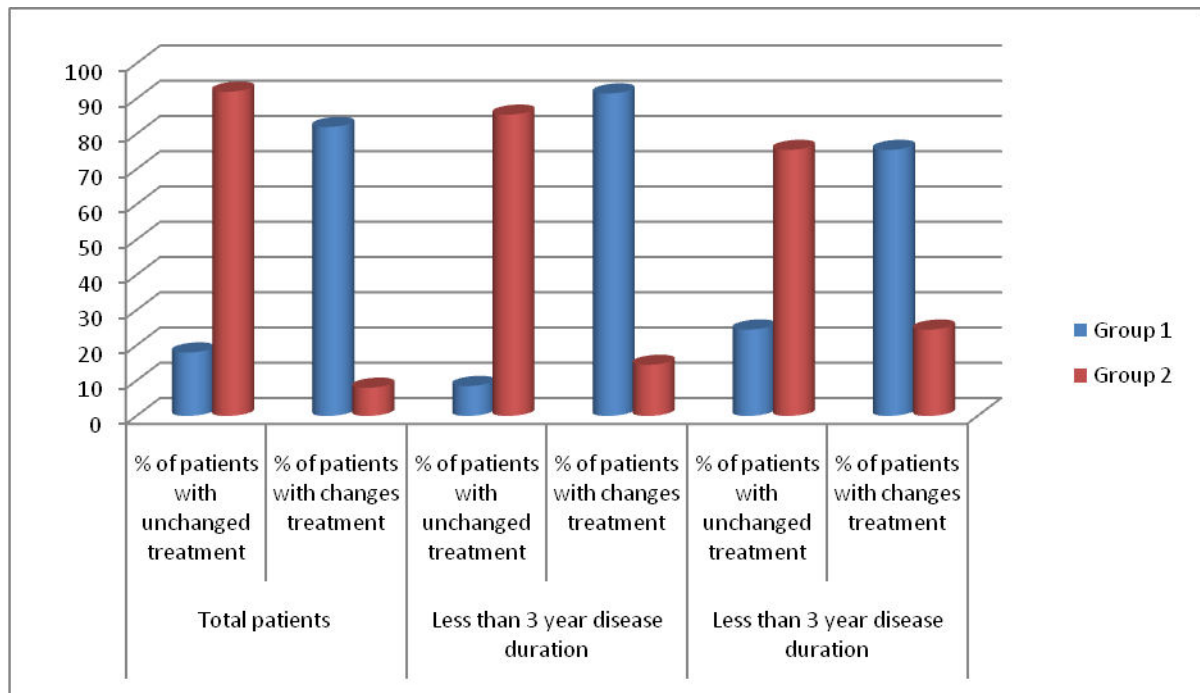


Table 2: p-value for the RA treatment status in patients after baseline MRI

Parameter		Group 1	Group 2	p-value
Total patients	% of patients with unchanged treatment	18	92	0.01*
	% of patients with changes treatment	82	8	0.01*
Less than 3 year disease duration	% of patients with unchanged treatment	8.5	85.5	0.01*
	% of patients with changes treatment	91.5	14.5	0.01*
Less than 3 year disease duration	% of patients with unchanged treatment	24.5	75.5	0.01*
	% of patients with changes treatment	75.5	24.5	0.01*

DISCUSSION

RA is a chronic inflammatory polyarthritis, which frequently leads to progressive joint destruction and disability. Regarding early diagnosis of RA, longitudinal studies have demonstrated that MRI is more sensitive than radiography in demonstrating progressive erosive joint damage.⁸ MRI is an important imaging technique that provides multiplanar images and is able to visualize a range of joint structures, including synovium, tendons, ligaments, bone, and cartilage. It does not use radiation, so it can be repeated as much as necessary, and allows longitudinal assessment. With the advances in sequence analysis software and lower costs, MRI is likely to become more accessible. MRI is recognized as the imaging technology of choice for visualization of the inflamed synovial membrane and bone edema. Furthermore, MRI has been shown to be a sensitive, non-invasive method for detection and quantification of bone erosions. Erosions are visible on MRI on average two years before they are visible on radiographs and may

become consistently visualized on radiographs of the metacarpophalangeal (MCP) joints only when 20%-30% of the bone is eroded on MRI.⁹⁻¹¹

In the present study, a relatively low level of clinical disease activity with a mean number of swollen or tender joints for both MRI-positive and MRI-negative patients was seen. Fox et al determined the impact of enhanced MRI on patient management in a group of patients referred for MRI by rheumatologists. After institutional review board approval, they evaluated all hand MRI examinations referred by the rheumatology department for synovitis evaluation between September 2007 and May 2009. The study included 48 patients with a mean age of 51 years. Significant management changes initially occurred in 79% of the positive and in 11% of the negative MR examinations with average follow-up of ~300 days. From the results, they concluded that enhanced MRI significantly altered clinical management in 50% of these patients with RA or suspected RA. Therefore, when the clinical picture in a patient with RA

or suspected RA is unclear, enhanced MRI can provide useful guidance for treatment modifications.¹² Brown et al studied 107 RA patients receiving disease-modifying antirheumatic drug therapy who were judged by their consultant rheumatologist to be in remission and 17 normal control subjects. Patients underwent clinical, laboratory, functional, and quality of life assessments. The Disease Activity Score 28-joint assessment and the American College of Rheumatology remission criteria, together with strict clinical definitions of remission, were applied. Imaging of the hands and wrists using standardized acquisition and scoring techniques with conventional 1.5T magnetic resonance imaging (MRI) and ultrasonography (US) were performed. Irrespective of which clinical criteria were applied to determine remission, the majority of patients continued to have evidence of active inflammation, as shown by findings on the imaging assessments. Most RA patients who satisfied the remission criteria with normal findings on clinical and laboratory studies had imaging-detected synovitis. This subclinical inflammation may explain the observed discrepancy between disease activity and outcome in RA. Imaging assessment may be necessary for the accurate evaluation of disease status and, in particular, for the definition of true remission.¹³ Palosaari et al investigated if disease assessment by contrast-enhanced dynamic and static magnetic resonance imaging (MRI) and quantitative nanocolloid (NC) scintigraphy gives useful additional information in early rheumatoid arthritis (RA). The baseline MRI bone oedema score ($\rho=0.67$), MRI synovitis score ($\rho=0.57$), ESR ($\rho=0.56$), CRP ($\rho=0.48$), E-rate ($\rho=0.47$) and (99m)Tc-NC uptake ($\rho=0.45$) were related with the change in the MRI erosion score from baseline to 2 yrs ($\rho=$ Spearman's correlation). In the multivariate logistic regression model, the bone marrow oedema score was the only baseline variable that predicted erosive progression at 2 yrs' follow-up (OR 4.2, 95% CI 1.3-13.8). The median (interquartile range) change in the erosion score from baseline to 2 yrs was 0 (0, 0) and 4 (2, 5) in the patients with ($n=9$) and without ($n=15$) a persistent clinical response over the 2 yrs, respectively ($P=0.001$). The non-responders who presented with erosive progression from 1 yr to 2 yrs had higher MRI synovitis scores, bone oedema scores, E-rate and (99m)Tc-NC uptake at 1-yr follow-up than the non-responders without progressive bone damage. The degree of local synovial inflammation at baseline, evaluated by dynamic and static MRI and quantitative NC scintigraphy, is closely related to the progression of wrist joint erosions during the first 2 yrs of the disease. Furthermore, at follow-up, if no persistent clinical response is achieved, these imaging methods may help to predict future erosiveness and help in clinical therapeutic decision making. Inflammatory changes (synovitis and bone marrow edema) and destructive changes (bone erosion) were evaluated by magnetic resonance imaging (MRI) in patients with rheumatoid arthritis (RA), and their relations with disease activity were assessed during treatment with tumor necrosis factor (TNF) inhibitors.

Ten patients with early active RA underwent MRI at 0 and 16 weeks of TNF-inhibitor treatment. The carpal bones of the dominant hand were evaluated by the outcome measures in rheumatology clinical trials MRI score for RA. After 16 weeks, the mean disease activity score (DAS 28) decreased significantly from 5.54 to 2.70, while the number of tender joints, number of swollen joints, and inflammatory parameters were also significantly improved. The mean synovitis and marrow edema scores determined by MRI showed a significant decrease from 6.1 to 2.2 and 12.8 to 6.2, respectively, while the annual bone-erosion progression score decreased from 12.6 to 2.0. Although synovitis persisted in some patients, imaging remission was achieved in two patients. In conclusion, TNF-inhibitor therapy achieved an early decrease of disease activity and MRI revealed amelioration of joint destruction. The MRI score for RA is useful for assessing the early response to TNF inhibitors.¹⁴⁻¹⁶

CONCLUSION

From the above results, the authors conclude that useful information regarding the treatment therapy is provided by a single MRI done during the phase of treatment. Future researches are recommended.

REFERENCES

1. Aletaha D, Neogi T, Silman AJ, Funovits J, Felson DT, Bingham CO 3rd et al. 2010 rheumatoid arthritis classification criteria: an American College of Rheumatology/European League Against Rheumatism collaborative initiative. *Ann Rheum Dis* 2010;69(9):1580-8.
2. Freeston JE, Bird P, Conaghan PG. The role of MRI in rheumatoid arthritis: research and clinical issues. *Curr Opin Rheumatol* 2009;21(2):95-101.
3. Wakefield RJ, Conaghan PG, Jarrett S, Emery P. Noninvasive techniques for assessing skeletal changes in inflammatory arthritis: imaging technique. *Curr Opin Rheumatol* 2004;16(4):435-42. [
4. Hodgson RJ, O'Connor P, Moots R. MRI of rheumatoid arthritis image quantitation for the assessment of disease activity, progression and response to therapy. *Rheumatology (Oxford)* 2008;47(1):13-21.
5. Sugimoto H, Takeda A, Hyodoh K. Early-stage rheumatoid arthritis: prospective study of the effectiveness of MR imaging for diagnosis. *Radiology* 2000;216(2):569-75.
6. Boutry N, Hachulla E, Flipo RM, Cortet B, Cotton A. MR imaging findings in hands in early rheumatoid arthritis: comparison with those in systemic lupus erythematosus and primary Sjögren syndrome. *Radiology* 2005;236(2):593-600.
7. Duer A, Østergaard M, Hørslev-Petersen K, Vallø J. Magnetic resonance imaging and bone scintigraphy in the differential diagnosis of unclassified arthritis. *Ann Rheum Dis* 2008;67(1):48-51.
8. Whiting PF, Smidt N, Sterne JA, Harbord R, Burton A, Burke M et al. Systematic review: accuracy of anti-citrullinated Peptide antibodies for diagnosing rheumatoid arthritis. *Ann Intern Med* 2010;152:456-64.
9. Narváez JA, Narváez J, De Lama E, De Albert M. MR imaging of early rheumatoid arthritis. *Radiographics* 2010;30(1):143-65.
10. Ejbjerg BJ, Vestergaard A, Jacobsen S, Thomsen HS, Østergaard M. The smallest detectable difference and

- sensitivity to change of magnetic resonance imaging and radiographic scoring of structural joint damage in rheumatoid arthritis finger, wrist, and toe joints: a comparison of the OMERACT rheumatoid arthritis magnetic resonance imaging score applied to different joint combinations and the Sharp/van der Heijde radiographic score. *Arthritis Rheum* 2005;52(8):2300-6.
11. Hetland ML, Stengaard-Pedersen K, Junker P, Østergaard M, Ejlberg BJ, Jacobsen S et al. Radiographic progression and remission rates in early rheumatoid arthritis - MRI bone oedema and anti-CCP predicted radiographic progression in the 5-year extension of the double-blind randomised CIMESTRA trial. *Ann Rheum Dis* 2010;69(10):1789-95.
 12. Conaghan PG, Ejlberg B, Lassere M, Bird P, Peterfy C, Emery P et al. A multicenter reliability study of extremity-magnetic resonance imaging in the longitudinal evaluation of rheumatoid arthritis. *J Rheumatol* 2007;34(4):857-8.
 13. Østergaard M, Ejlberg B, Szkudlarek M. Imaging in early rheumatoid arthritis: roles of magnetic resonance imaging, ultrasonography, conventional radiography and computed tomography. *Best Pract Res Clin Rheumatol* 2005;19(1):91-116.
 14. Forslind K, Larsson EM, Johansson A, Svensson B. Detection of joint pathology by magnetic resonance imaging in patients with early rheumatoid arthritis. *Br J Rheumatol* 1997;36(6):683-8.
 15. Pincus T, Sokka T. Should contemporary rheumatoid arthritis clinical trials be more like standard patient care and vice versa? *Ann Rheum Dis* 2004;63(Suppl 2):ii32-ii9.
 16. Sokka T, Pincus T. Most patients receiving routine care for rheumatoid arthritis in 2001 did not meet inclusion criteria for most recent clinical trials or American College of Rheumatology Criteria for Remission. *J Rheumatol* 2003;30:1138-46.

Source of support: Nil

Conflict of interest: None declared

This work is licensed under CC BY: *Creative Commons Attribution 3.0 License*.

