

Case Report

Management of Pink Tooth by Different Method of Obturation System: Case Report

Harakh Chand Baranwal, Neeraj Kumar, Ankita Singh, Prasad Patel Suresh

Department of Conservative Dentistry and Endodontics , Faculty of Dental Science, IMS, BHU , Uttar Pradesh, India

ABSTRACT:

Introduction: Root resorption is a process which involved loss of dental hard tissues. It may occur due to dental trauma, bleaching, and orthodontic treatment, and occasionally it may occur in the periodontal disease. Radiographic examinations are the main diagnostic add for identification of Root Resorption. It may be internal or external. Severe trauma is the main cause of Internal root resorption it may be occupied due to caries and pulp inflammation. It mainly seen in anterior teeth but it may be seen in posterior teeth. Internal resorption is usually asymptomatic. Internal resorption also know as pink teeth because of pulpal inflammation teeth appear pink. **Case reports:** The article describes a two case of internal root resorption involving the middle third of permanent maxillary incisor which was treated by the non-surgical method and obturated with a different method of obturation system. **Conclusion:** Root resorption is a complex process. Success of treatment depends on location, duration and size of the lesion. Internal resorption is difficult to predict and control. Prevention should be the best approach. Both obturation methods are equally effective in treatment of internal resorption.

Key word: Pink Tooth, Internal Resorption, Gutta Flow, Obturation System.

Received: 24 February, 2019

Revised: 20 March, 2019

Accepted: 23 March, 2019

Corresponding author: Dr. Neeraj Kumar, Junior resident, Department of Conservative Dentistry and Endodontics , Faculty of Dental Science, IMS, BHU , Uttar Pradesh, India

This article may be cited as: Baranwal HC, Kumar N, Singh A, Suresh PP. Management of Pink Tooth by Different Method of Obturation System: Case Report. J Adv Med Dent Scie Res 2019;7(4): 1-4.

BACKGROUND

Resorption can be defined as a condition associated with either a physiologic or a pathologic process resulting in a loss of dentin, cementum and/or bone.^[1] The internal resorption can be pathological and physiological. Physiological resorption is normal process of rhizolysis occurs in primary teeth. In permanent teeth, the resorptions are always pathological, as there is no physiological root resorption in them.^[2] Pathological resorption can be divided as internal and external, and combination of them.^[3]

Internal resorption is characterized by resorption of the inner part of the root canal and usually caused by trauma and chronic pulpitis which cause the formation of dentinoclasts cell. Internal resorption is asymptomatic, identify usually by radiographic examination. It is observed that the inner surface of the root canal undergo symmetrical expansion with regular and rounded contours. In some cases of resorption it is observed that formation of a barrier

in the inner surface, which is formed by the function of odontoblasts in a portion of the non-mineralized tissue. It cause by trauma and loss of pre-dentine layer. In cases of trauma, predentin and odontoblast layer are displace.^[3] Internal resorption is caused by own structure of pulp, or the structure close to the pulp, it does not release any toxic product hence does not cause pulp necrosis in a tooth.^[4] In some cases when total pulp necrosis occur then internal resorption process stabilizes and after necrosis periapical lesion is formed.^[5]

External root resorption shows the continuity of root canal, which may cause by delayed reaction to dental trauma, as a result of the orthodontic movement, orthognathic surgery, periodontal treatment, and tooth whitening without pulp vitality. Their exact cause is still unknown and no etiological factor is found hence is called idiopathic.^[3] Radiographically, it represents as a radiolucent area and which is present of uneven surface found at different area

of the root. At more advanced stages; the affected teeth have mobility, fracture or a pink color in crown.^[3]

CASE REPORT

CASE 1

A 25-year-old healthy boy was referred to the Department of Conservative Dentistry and Endodontics with the chief complaint discoloration (pink tooth) upper front teeth for 6 months. The patient's medical history was absolutely non-contributory. No history of pain in relation to upper central incisor but the patient did give a history of trauma about 9 years back. On clinical examination, tooth no 21 (FDI) was discolored and palatal surface also involved. [Fig 1 and 2] Tender on percussion is absent. No swelling, sinus tract or no erythema was found. The tooth 11 and 21 responded higher to thermal and electric pulp testing. An intraoral periapical radiograph showed a radiolucent, well-defined, oval enlargement of the r canal involving the middle portion of the teeth.[FIG-3] The outline of the root canal wall is distorted in the area of the defect. No radioopacity indicating deposition of any metaplastic tissue was evident in the resorptive defect. Based on history, clinical and radiographic findings a diagnosis was an internal root resorption was established. As the diagnosis was done, root

canal treatment was the treatment planned for the patient. Tooth no 21, 11 was isolated under rubber dam and it was disinfected with 5.2 % sodium hypochlorite-conservative access opening was done & the canal was negotiated with no 10 K-File up to the apex. The coronal pulp was non-vital while the bleeding was induced in the negotiation of the middle third of the canal space. Coronal flaring of the canal was carried out by Gates–Glidden drills (sizes 3&4).The working length was established x-ray.[FIG-4] The root canal shaping & cleaning was performed with manual stainless- steel hand files which were accompanied by copious irrigation of 5.2% sodium hypochlorite [NaOCl]. The NaOCl irrigation was passively activated using ultrasonic files [EndoActivator, Dentsply Maillefer]. The master apical file was ISO 0.50. The canal was dried with paper points and calcium hydroxide [Ca(OH)₂] intracanal medicament was placed in the canal. After 1 week, sterile water was used to flush the calcium hydroxide from the canal. After drying the canal, obturation was done with AH-Plus sealer (Dentsply, Maillefer) and gutta-percha using warm verticle compaction technique [System B and Obtura III gun]. The post-endodontic restoration was done with composite resin restoration. Root canal filling was verified with the postoperative radiograph. [Fig-5, and 6]

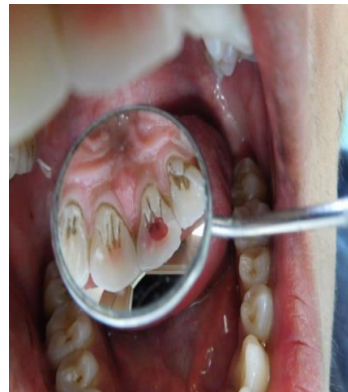
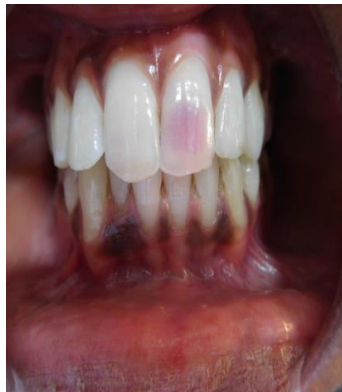
FIG 1 and 2: Pre-operative photograph

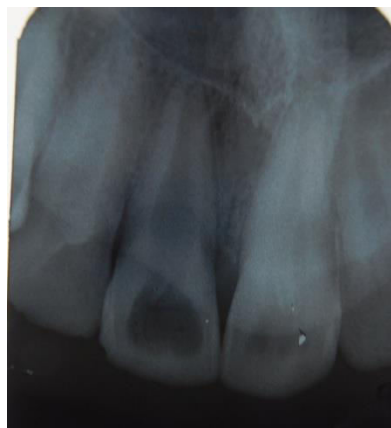
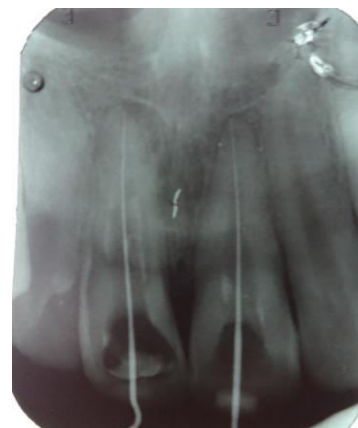
FIG-3 Preop radiograph



[FIG-4] Working length determination

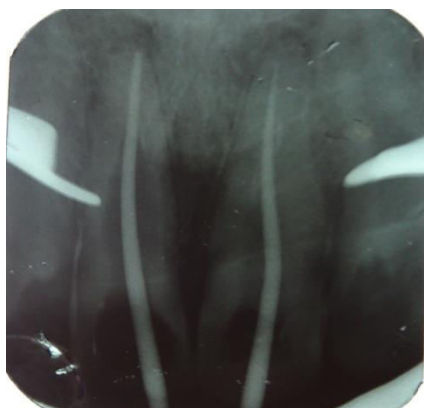

FIG-5 MASTER CONE

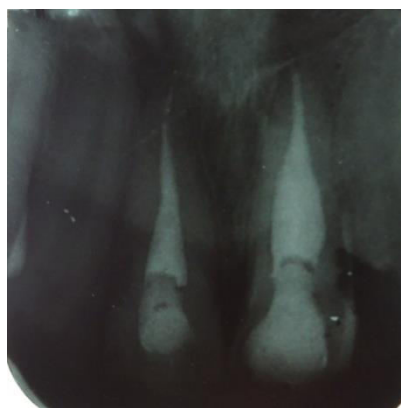


FIG-6 Post obturation by System B and Obtura III gun

CASE 2

A 22-year-old female patient presented with chief complaint of slight pain in the upper front tooth for 2 months. On examination TOP present in 11 teeth and history of root canal treatment in 11 and 21 teeth. on radiographic examination[FIG-7] show faulty root canal treatment on teeth 11,21 and 22 show internal resorption first we remove gutta-percha of teeth 11and 21. The root canal shaping & cleaning was performed with manual stainless- steel hand files which were accompanied by copious irrigation of 5.2% sodium hypochlorite [NaOCl] and obturated. Access opening was done of teeth 22& the canal was negotiated with 10 K-File up to the apex. Coronal flaring of the canal was carried out by Gates–Glidden drills (sizes 3&4). The working length was established by x-ray. [Fig-8] and Chemomechanical preparation is done. Master cone was confirm by x-ray.[Fig-9] and obturation done by gutta flow 2(COLTENE)[Fig-10]. The post-endodontic restoration was done with composite resin restoration

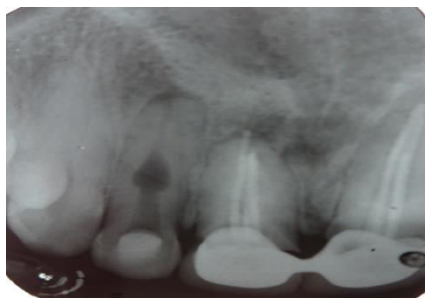

FIG- 7 Preop radiograph

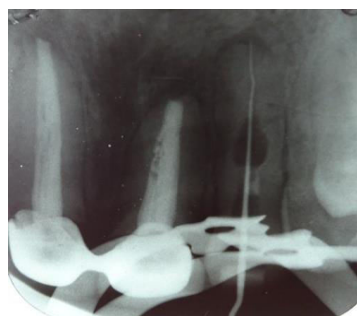


FIG- 8 Working length determination

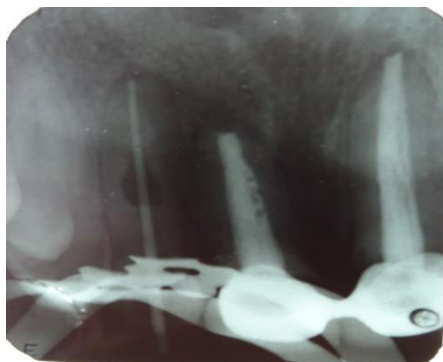


FIG-9 MASTER CONE

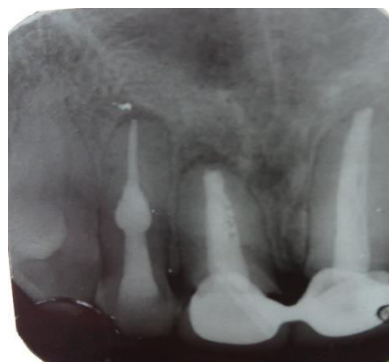

FIG-10 Post obturation by gutta flow

DISCUSSION

The first a case on internal resorption is reported by bell in 1830. After that there have been numerous case are reported.^[13] It is a multifactorial process which is associated with various factors, such as local factors, physiological resorption, systemic condition and idiopathic resorption. Managing resorbition can be challenging with unknown outcomes. Success of the treatment depend the location of lesion, size of the lesion and durartion of lesion.^[6] the most common cause of root resorption is severe trauma that results in necrosis of pulp, damage to the teeth which cause dentinal tubules are exposed. Bacteria that are found in the canal stimulate inflammation in the adjacent tissues and result in aggressive and progressive inflammatory resorption.^[6-7]

Internal resorption is the result of inflamed pulp and clastic precursor cells that are recruiting by blood vessels. Treatment of internal resorption is quite simple as control the process of internal root resorption by preventing the blood supply to the resorbing tissues and root canal therapy. The duration of the periapical inflammation are affecting the severity of resorption. Success of treatment is dependent on the etiology of the resorption. In the case where the resorption is due to necrosis and injury, than nonsurgical therapy is performed. Chemomechanical preparation is as an essential step for elimination of infection from the canal. The intracanal medicament may also help in eliminate bacteria found in between appointments.^[8]

Management of internal resorbition is done by Nonsurgical root canal therapy and calcium hydroxide dressing was given this was recommended by Andreasen.^[9-10] MTA is also used as repair material in internal resorbition due to better sealing ability, biocompatibility, and fibroblastic activity.^[11] cold filling gutta-percha system (GuttaFlow®2) can be use for obturation. Which is combination of two products : Gutta-percha with a particle size of lesser than 30 µm and sealer.^[12] Good flow have low solubility and tight seal of the root canal cause by slight expansion, hence, no forces apply by gutta flow on the weaker part of teeth when compare with thermomechanical or cold lateral compaction.

CONCLUSION

Root resorption is a complex process. Success of treatment depends on location, duration and size of the lesion. Internal resorption is difficult to predict and control. Prevention should be the best approach. Guttaflow show expansion which may cause fracture of tooth. Both obturation methods are equally effective in treatment of internal resorption.

REFERENCE

1. AAE. Glossary of Endodontic Terms;2012. 8th Edition.
2. Torres EAD, Ronquiz L, Villar LSV. Reabsorção radicular: revisão de literatura. Revista Científica Facimed. 2011;3(3):90-103.
3. Camargo SEA, Moraes MEL, Moraes LC, Camargo CHR. Principais características clínicas e radiográficas das reabsorções radiculares internas e externas. Revista de Odontologia da Universidade Cidade de São Paulo. 2008;20(2):195-203.
4. Consolaro A. O conceito de reabsorções dentárias ou as reabsorções dentárias não são multifatoriais, nem complexas, controvertidas ou polêmicas. Dental Press J Orthod. 2011;16(4):19-24.
5. Vaz IP, Noites R, Ferreira JC, Pires P, Barros J, Carvalho MF. Treatment of upper central incisors after trauma. RGO. 2011;59(2):305-11
6. Ne RF, Witherspoon DE, Gutmann JL. Tooth resorption. Quintessence Int. 1999;30(1):9-25.
7. Bakland LK. Root resorption. Dent Clin North Am. 1992;36(2):491-507
8. Fuss Z, Tsesis I, Lin S. Root resorption-diagnosis, classification and treatment choices based on stimulation factors. Den Traumatol. 2003;19(4):175-182.
9. Andreasen JO. External root resorption: Its implications in dental traumatology, pedodontics, periodontics, orthodontics and endodontics. Int Endod J. 1985;18(2):109-118.
10. Saad Y. Calcium hydroxide in the treatment of external root resorption. J Am Dent Assoc. 1989;118(5):579-581
11. Altundasar E, Demir B. Management of a perforating internal resorptive defect with mineral trioxide aggregate: A case report. J Endod. 2009;35(10):1441-1444.¹
12. Dental root canal sealing materials. Source: NIOM Norwegian Institute for Dental Material Testing ISO 6876. 2001
13. Bell T. The anatomy, physiology, and disease of the teeth. Philadelphia: Carey and Lee Publishing; 1830. p. 171-2

Source of support: Nil

Conflict of interest: None declared

This work is licensed under CC BY: **Creative Commons Attribution 3.0 License.**