

Original Article

Comparison of Transverse Diameter of Lumbar Vertebral Canal and Body Among Males and Females Study Population- A Clinical Study

Shazya Gul¹, Sheetal Chandel², Jasbir Kaur³, Ritu Tandon⁴

¹Senior Demonstrator, ^{3,4}Tutor, Department of Human Anatomy, ASCOMS & Hospital, Jammu, ²PG Scholar, Department of Human Anatomy, Govt. Medical College, Jammu

ABSTRACT:

Background: The causes of low back pain are multi-factorial, but the narrowing of the lumbar canal plays a significant role. Lumbar Spinal Canal Stenosis is considered to be the main etiology of lumbar pain. The present study was conducted to compare the transverse diameter of lumbar vertebral body and canal in males and females. **Materials & Methods:** The present study included 10 subjects of both genders. Their lumbar radiographs were collected and studied. In all radiographs, the transverse diameter of vertebral body (TDVb) and transverse diameter of vertebral canal (TDVc) was measured from L1 to L5 vertebral levels. **Results:** The mean TDVb at L1 (Males- 37.22, females- 36.1), L2 (Males- 38.44, females- 38.32), L3 (males- 39.64, females- 39.08), L4 (males- 42.38, females- 40.01) and L5 (males- 42.38, females- 42.15). The difference was non- significant ($P>0.05$). The mean TDVc at L1 was (males- 26.7, females- 28.25), L2 (males- 26.9, females- 28.6), L3 (males- 27.5, females- 28.6), L4 (males- 28.25, females- 30.12) and L5 (males- 28.29, females- 30.57). The difference was non- significant ($P>0.05$). **Conclusion:** We concluded that there is no significant difference in the transverse diameter of lumbar vertebral body and lumbar vertebral canal in males and females.

Key words: Vertebral body, Vertebral canal, Gender, Jammu.

Received: 20 October 2017

Revised: 28 October 2017

Accepted: 4 November 2017

Corresponding Author: Dr. Shazya Gul, Senior Demonstrator, Department of Human Anatomy, ASCOMS & Hospital, Jammu, India

This article may be cited as: Gul S, Chandel S, Kaur J, Tandon R. Comparison of Transverse Diameter of Lumbar Vertebral Canal and Body Among Males and Females Study Population- A Clinical Study. J Adv Med Dent Scie Res 2018;6(2):1-4.

INTRODUCTION

Low back pain is one of the most common health problems affecting up to 85% of people. The causes of low back pain are multi-factorial, but the narrowing of the lumbar canal plays a significant role. Various causes have been attributed to low backache, of which 'Lumbar Spinal Canal Stenosis' (LSS) as a causative is of great interest. Researchers have documented the clinical value of measurements of interpedicular distances in diagnosis of narrowing of spinal canal. Since then, the size of spinal canal has attracted increasing interest for its use in clinical practice. Thus measurement of transverse diameter of lumbar canal is an important tool for diagnosis of lumbar spinal stenosis.¹

The lumbar vertebrae are the five vertebrae between the rib cage and the pelvis. They are the largest segments of the

vertebral column and are characterized by the absence of the foramen transversarium within the transverse process and by the absence of facets on the sides of the body. They are designated L1 to L5, starting at the top. The lumbar vertebrae help support the weight of the body, and permit movement.²

Recent study shows that the normal values of transverse diameter (TDVc) show gender and regional variations and these values have been used to diagnose cases of LSS by morphometric evaluation. As this parameter is of paramount significance for diagnosing LSS, therefore a normal morphometric values in a population are essential to diagnose LSS. Few authors have measured normal values of lumbar interpedicular distances with the help of plain radiographs in various ethnic groups.³ Recently, it has been pointed out that instead of measuring the vertebral canal for

evaluating the degree of stenosis, it would be more reliable if the ratio of vertebral canal and of vertebral body i.e. canal body ratio (C/B) is taken as index for calculating the degree of stenosis.⁴ Considering this, the present study was conducted to compare the transverse diameter of lumbar vertebrae body and canal in males and females.

MATERIALS & METHODS

The present study included 10 subjects of both genders. Their lumbar radiographs were collected and studied. In all

radiographs, the transverse diameter of vertebral body (TDVb) was measured which is the shortest distance at the most constricted part of the vertebral body and the interpedicular distance of vertebral canal (TDVc) was taken as the distance between medial margins of pedicles in millimetres from L1 to L5 vertebral levels. Results thus obtained were subjected to statistical analysis. P value <0.05 was considered significant.

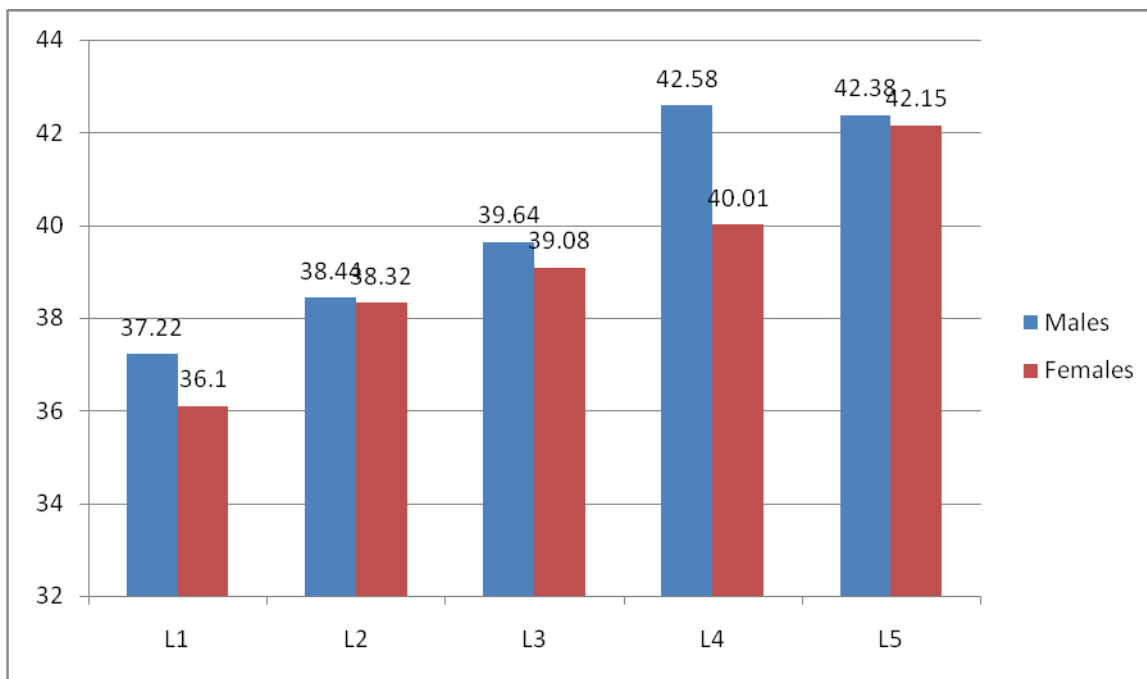
RESULTS

Table I Mean transverse diameter of vertebral body and canal at lumbar vertebral levels

Vertebral levels	Transverse diameter of vertebral body (TDVb) (mm)	Transverse diameter of vertebral canal (TDVc) (mm)
	Mean ±S.D	Mean ±S.D
L1	37.22±3.02	27.12±5.00
L2	38.17±4.12	27.40±5.15
L3	39.08±3.46	28.58±5.10
L4	41.35±4.01	29.46±5.25
L5	42.45±4.18	29.21±5.01

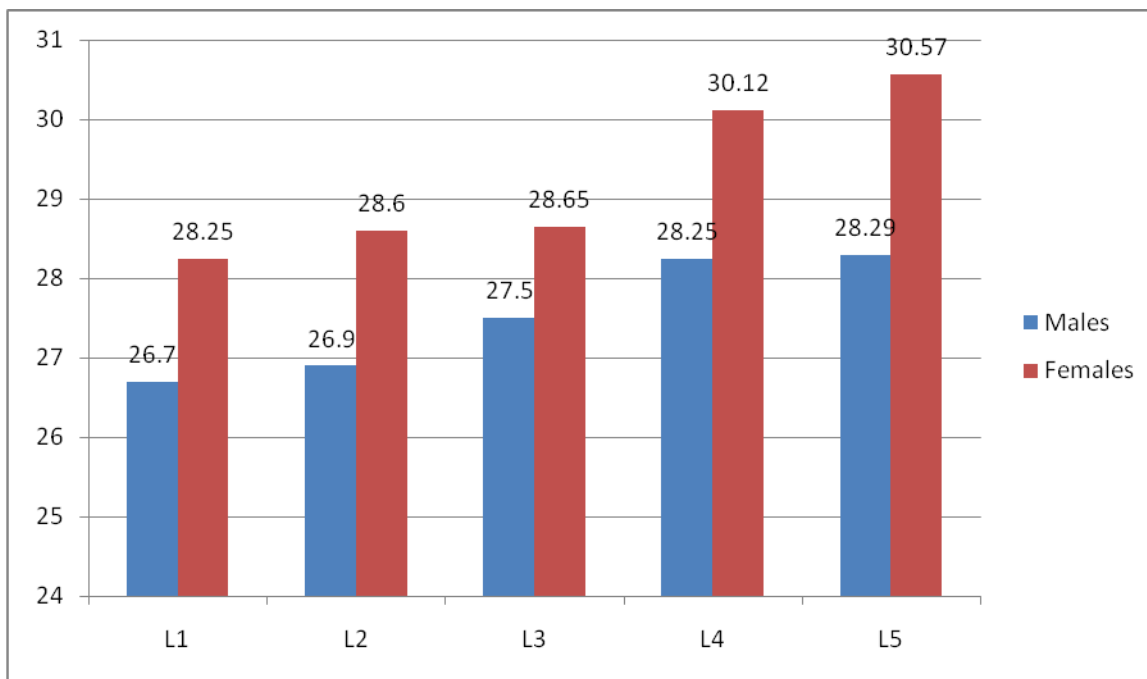
Table I shows that mean transverse diameter of vertebral body (TDVb) (mm) at L1 (37.22±3.02), L2 (38.17±4.12), L3 (39.08±3.46), L4 (41.35±4.01) and L5 (42.45±4.18) and the mean transverse diameter of vertebral canal (TDVc) (mm) at L1 (27.12±5.00), L2 (27.40±5.15), L3 (28.58±5.10), L4 (29.46±5.25) and L5 (29.21±5.01).

Graph I Comparison of (TDVb) in both genders



Graph I shows that mean TDVb at L1 (Males- 37.22, females- 36.1), L2 (Males- 38.44, females- 38.32), L3 (males- 39.64, females- 39.08), L4 (males- 42.38, females- 40.01) and L5 (males- 42.38, females- 42.15). The difference was non-significant (P>0.05).

Graph II Comparison of (TDVc) in both genders



Graph II shows mean TDVc at L1 (males- 26.7, females- 28.25), L2 (males- 26.9, females- 28.6), L3 (males- 27.5, females- 28.6), L4 (males- 28.25, females- 30.12) and L5 (males- 28.29, females- 30.57). The difference was non-significant ($P>0.05$).

DISCUSSION

Lumbar spinal stenosis is one of the most common cause for spinal surgical interventions nowadays. Diagnostic imaging techniques continue to play a pivotal role in the diagnosis, clinical and surgical management of lumbar spinal stenosis. Of all the diagnostic procedures, radio-diagnosis continues to be the most commonly applied methodology due to its cost effectiveness and easy availability.⁵ The present study was conducted to compare the transverse diameter of lumbar vertebrae body and canal in males and females.

In this study, 10 subjects of both genders were selected. We found that mean transverse diameter of vertebral body (TDVb) (mm) at L1 was 37.22 ± 3.02 , L2 was 38.17 ± 4.12 , L3 was 39.08 ± 3.46 , L4 was 41.35 ± 4.01 and L5 was 42.45 ± 4.18 and the mean transverse diameter of vertebral canal (TDVc) (mm) at L1 was 27.12 ± 5.00 , L2 was 27.40 ± 5.15 , L3 was 28.58 ± 5.10 , L4 was 29.46 ± 5.25 and L5 was 29.21 ± 5.01 . This is in agreement with Amonoo et al.⁶ The morphometric parameters of lumbar vertebral canal are assessed but the measurement of the transverse diameter (interpedicular distance) of lumbar canal is considered to be the most reliable indicator to define a stenotic canal.

We found that mean TDVb at L1, L2, L3, L4 and L5 in males were comparatively higher as compared to females. The transverse diameter of vertebral body increases cranio-

caudally suggesting change in size of the vertebral column with respect to its weight bearing functions. The increase in size of lower lumbar vertebrae is attributed to it being site of maximum load bearing, performing extensive flexion, extension, rotation and gliding movements. This is in agreement with Hinck et al.⁷

Similarly, TDVc value in all lumbar vertebrae was comparatively higher in females as compared to males. The first lumbar vertebra is level with the anterior end of the ninth rib. This level is also called the important transpyloric plane, since the pylorus of the stomach is at this level. Other important structures are also located at this level, they include; fundus of the gall bladder, celiac trunk, superior mesenteric artery, termination of spinal cord, beginning of filum terminalis, renal vessels, middle suprarenal arteries, and hila of kidneys.⁸

The fifth lumbar vertebra is characterized by its body being much deeper in front than behind, which accords with the prominence of the sacrovertebral articulation; by the smaller size of its spinous process; by the wide interval between the inferior articular processes, and by the thickness of its transverse processes, which spring from the body as well as from the pedicles.⁹ The fifth lumbar vertebra is by far the most common site of spondylolysis and spondylolisthesis. The importance of the radiographic measurement of the spinal canal was first emphasized in 19341 by Elseberg and Dyke who first established a normal range of interpedicular distances in the thoracic and lumbar spine and applied their method to the diagnosis of intraspinal tumours.¹⁰

CONCLUSION

The value of transverse diameter of lumbar canal was comparatively higher in females as compared to males while as transverse diameter of lumbar vertebral body was comparatively higher in males as compared to females. The measurement of transverse diameter of lumbar canal and body could be an important tool for diagnosis of lumbar canal stenosis.

REFERENCES

1. Fritz JM, Irrgang JJ. A comparison of a modified Oswestry low back pain disability questionnaire and the Quebec back pain disability scale. *Phys Ther.* 2001; 81:776-788.
2. Gupta M, Bharihoke V, Bhargava S.K. and Agrawal N. 'Size of the Vertebral Canal-A correlative study of measurements in radiographs and dried bones.' *J. Anat. Soc. India.* 1998; 47:1-6.
3. Nirvan A.B., Pensi C.A., Patel J.P., Saha G.V. & Dave R.V. 'A study of inter-pedicular distance of the lumbar vertebrae measured in plain antero posterior radiography'. *J Anat. Soc India.* 2005; 2:58-61.
4. Vinay KV, Vishal K. A study of transverse diameter of the lumbar spinal canal in normal south Indians using CR-35X digitizer. *Indian Journal of Fundamental and applied Life Sciences* 2012; 2:30-35.
5. Piera, V., Rodroquez, A., Cobos, A., Hernandez, R.& Cobos, P. Morphology of lumbar vertebral canal. *Acta Anat.* 1988;131:25-40.
6. Amonoo-Kuofi HS. The sagittal diameter of the lumbar vertebral canal in normal adult Nigerians. *J Anat* 1985;140:69-78.
7. Hinck, V.C, Clark, W.M. & Hopkins, C.E. Normal interpediculate distances (minimum and maximum) in children and adults. *Am. J. Roentg.* 1966; 97:141-153.
8. Anderson GB. Epidemiology of low back pain. *Acta Orthop Scand Suppl* 1998; 281:28-31.
9. Christenson PB. The radiologic study of the normal spine. *Radiol Clin North Am* 1977; 31: 147-57.
10. Schonstrom NS, Bolender N, Spengler DM. The pathomorphology of spinal stenosis as seen on CT scans of the lumbar spine. *Spine* 1985; 10: 806-11.

Source of support: Nil

Conflict of interest: None declared

This work is licensed under CC BY: *Creative Commons Attribution 3.0 License.*