

Original Article

Assessment of Postoperative Complications among Patients Undergoing Laparoscopic Cholecystectomy

K.C. Panwar¹, Abhishek Panwar²

¹Principal Specialist (General Surgery), M.G. Hospital, Bhilwara, Rajasthan, India.

²MS (General Surgery), Ex-Assistant Professor, SMS Medical College, Jaipur, Rajasthan, India.

ABSTRACT:

Background: Knowledge of relevant anatomy is important for the safe execution of any operative procedure. There is now a fair amount of data to suggest that the acceptance of laparoscopic cholecystectomy (LC) as the standard procedure, has led to an increase in bile duct injuries. Hence; we planned the present study to evaluate various complications seen in patients undergoing LC. **Materials & methods:** We planned included evaluation of various post-operative complications in patients undergoing cholecystectomy. A total of 120 patients were included present study. All patients treated with LC. Any complication found post operatively was recorded. The collected data was entered computer and managed statistically using SPSS computer program version 17. **Results:** The most common complication was adhesions (55), bleeding (38), empyema (22) and CBD (20), mucocele (24), anomaly of cystic duct (10) and bowel injury (8) and difficult calot's triangle (2). The difference was significant ($P < 0.05$). Wound infection was seen in 75 patients. Others were jaundice (32), biliary fistula (28), nausea/vomiting (24), biliary strictures (15) and incisional hernia (17). **Conclusion:** Commonly encountered post-operative complications in patients undergoing LC include wound infection, jaundice, biliary fistula, nausea/vomiting, biliary strictures and incisional hernia.

Key words: Cholecystectomy, Laproscopic, Gall stones

Received: 18 January 2018

Revised: 07 February 2018

Accepted: 09 February 2018

Corresponding Author: Dr. AbhishekPanwar, MS (General Surgery), Ex-Assistant Professor, SMS Medical College, Jaipur, Rajasthan, India.

This article may be cited as: Panwar KC, Panwar A. Assessment of Postoperative Complications among Patients Undergoing Laparoscopic Cholecystectomy. J Adv Med Dent Sci Res 2018;6(3):1-3.

INTRODUCTION

Knowledge of relevant anatomy is important for the safe execution of any operative procedure.¹ Specifically, in the context of a cholecystectomy, it has been recognized since long that misinterpretation of normal anatomy as well as the presence of anatomical variations contribute to the occurrence of major postoperative complications especially biliary injuries. Such injuries in turn can cause significant morbidity and occasionally even mortality.²⁻⁴ They are also one of the commonest causes of litigation against abdominal surgeons in the developed world. There is now a fair amount of data to suggest that the acceptance of laparoscopic cholecystectomy (LC) as the standard procedure, has led to an increase in bile duct injuries.⁵ The operation is not completely risk-free, some incidents and complications being more frequent than with open cholecystectomy (OC).^{6,7} Hence; we planned the present study to evaluate various complications seen in patients undergoing LC.

MATERIALS & METHODS

We planned the present study in the department of general surgery of the M.G. Hospital, Bhilwara, Rajasthan, and included evaluation of various post-operative complications in patients undergoing cholecystectomy. Ethical approval was obtained from institutional ethical committee and written consent was obtained after explaining in detail the entire research protocol. A total of 120 patients were included present study. Inclusion criteria for the present study included:

- Patients planned to undergo LC,
- Patients with negative history of any systemic illness,
- Patients with negative history of any known drug allergy,
- Patients with negative history of any form of immunosuppressant therapy,
- Patients between the age group of 25 to 50 years.

After meeting the inclusion criteria, a total of 100 patients were included in the present study.

All patients treated with LC. Any complication found post operatively was recorded. The collected data was entered computer and managed statistically using SPSS computer program version 17. Chi- square was used. P value < 0.05 was considered significant.

RESULTS

Out of 120 subjects, males were 50 and females were 70. The difference was non- significant (P> 0.05) (Table I). In this study, 25-40 years age group consisted of 15 males and 20 females. Age group 40-55 comprised of 22 males and 40 females. Age group >55 years had 13 males and 10 females. The difference was significant (P-0.01). Graph I shows that most common complication was adhesions (55), bleeding (38), empyema (22) and CBD (20), mucocele (24), anomaly of cystic duct (10) and bowel injury (8) and difficult calot’s triangle (2). The difference was significant (P< 0.05). Wound infection

was seen in 75 patients. Others were jaundice (32), biliary fistula (28), nausea/vomiting (24), biliary strictures (15) and incisional hernia (17). The difference was significant (P-0.05) (graph II).

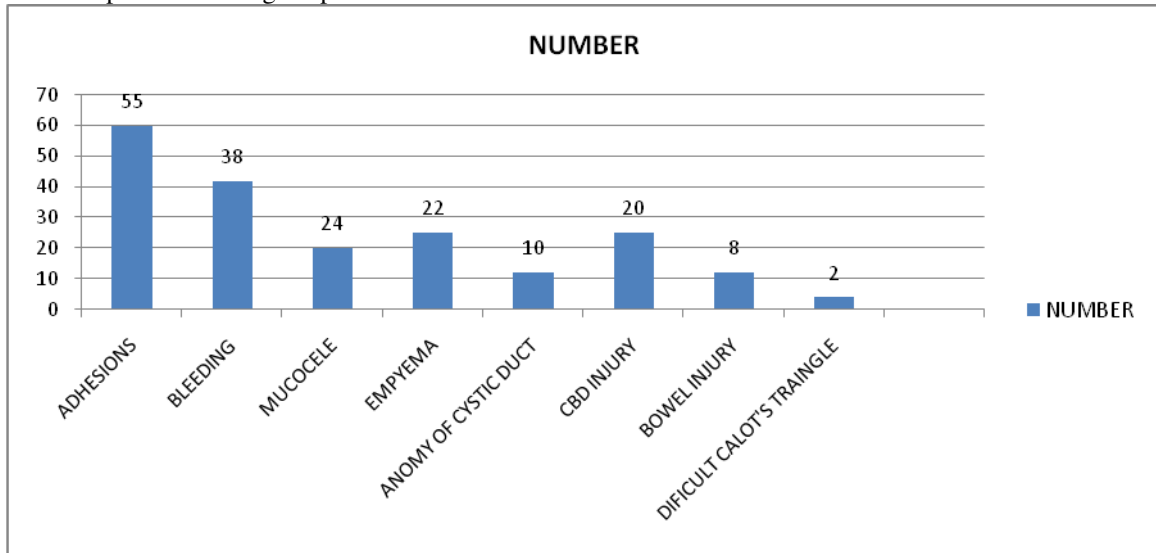
Table I Distribution of patients

Male	Female	P value
50	70	0.2

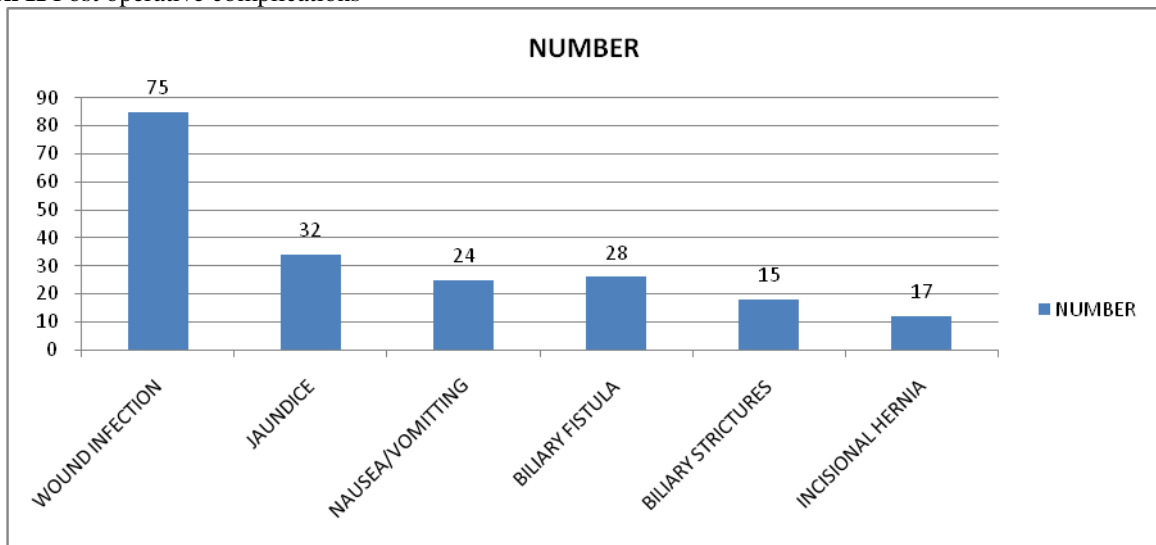
Table II Distribution of patients in different age groups

Age groups	Male	Female	P value
25-40	15	20	0.01
40-55	22	40	
>55	13	10	
Total	50	70	

Graph I Intraoperative findings in patients



Graph II Post operative complications



DISCUSSION

Deziel DJ et al evaluated complications of LC by a survey of surgical department chairpersons at 4,292 US hospitals. The 77,604 cases were reported by 1,750 respondents. Laparotomy was required for treatment of a complication in 1.2% of patients. The mean rate of bile duct injury was 0.6% and was significantly lower at institutions that had performed more than 100 cases. Bile duct injuries were recognized postoperatively in half of the cases and most frequently required anastomotic repair. Intraoperative cholangiography was practiced selectively by 52% of the respondents and routinely by 31%. Bowel and vascular injuries, which occurred in 0.14% and 0.25% of cases, respectively, were the most lethal complications. Postoperative bile leak was recognized in 0.3% of patients, most commonly originating from the cystic duct. Eighteen of 33 postoperative deaths resulted from operative injury. These data demonstrated that laparoscopic cholecystectomy is associated with low rates of morbidity and mortality but a significant rate of bile duct injury.⁸

Duca S et al analyzed several aspects of complications associated with LC procedure and their treatment possibilities. Over the last 9 years 9542 laparoscopic cholecystectomies have been performed, of which 13.9% were carried out for acute cholecystitis, 38.4% in obese patients and 7.6% in patients aged > 65 years. The main postoperative complications were bile leakage and choleperitoneum (54 cases), haemorrhage (15 cases), subhepatic abscess (10 cases) and retained bile duct stones (11 cases). Classic re-interventions were practiced in 28.8% of cases with complications. Mini-invasive techniques were used in 42.2% of cases with complications: laparoscopic re-interventions (15 cases) for choleperitoneum, haemoperitoneum and subhepatic abscess and endoscopic sphincterotomy (22 cases) for prolonged bile leak on subhepatic drain and for early diagnosed remnant lithiasis of the common bile duct. All cases healed. Another 26 patients were treated conservatively. With a precise diagnosis and a good indication, the mini-invasive treatment of complications was completed with good results. 16 laparoscopic re-operations and 22 endoscopic sphincterotomies were performed (for the treatment of bile leakage and remnant gallbladder stones).⁹

Khan MW et al analyzed their experience in laparoscopic cholecystectomy (LC) and its complications and their management. Amongst the total 4957 laparoscopic cholecystectomy (LC) performed by the authors between April 1995 to May 2005 the male, female ratio was 1:5.6 (744 and 4213). 15.33%(760) of LC were carried out for the patients with acute cholecystitis. The age ranged from 9 years to 98 years. Mean operating time was 37 minutes (7 m to 187 m). Average hospital stay was 2.23 days (20 h to 7d). Peri-cholecystic adhesions including cholecysto-enteric fistulae and acute inflammation were the main reason for difficult dissection. This could be anticipated from the history of recurrent attack, high fever, severe pain and thick walled gall bladder (GB) on ultrasonography

(USG). The main per-operative problem the authors came across was hemorrhage 5.2%(258), iatrogenic perforation of the gallbladder 15.12%(755) and common bile duct (CBD) injuries 0.12%(7). Conversion to open procedure was necessary in 0.68%(36) cases, most commonly due to obscure anatomy as a result of chronic inflammatory adhesions 0.56%(28), the other reasons for conversion were to deal with the CBD injury 0.04%(2), cholecystocolic fistula 0.02%(1), unsuspected malignancy 0.06%(3) and uncontrolled bleeding 0.04%(2). The postoperative complications were port site infection and stitch granuloma 0.75%(37), bile leakage 0.08%(4), hemorrhage 0.06%(3), sub-hepatic abscess 0.02%(1), peritonitis due to gut perforation 0.04%(2) and retained bile duct stones 0.06%(3). Two deaths were due to septicemia resulting from gut perforation. Laparoscopic cholecystectomy is a safe procedure in the hands of a surgeon with adequate exposure to open surgery and properly oriented in minimally invasive surgery. Complications could be reduced to minimum if meticulous principle of dissection is followed.¹⁰

CONCLUSION

From the above results, the authors concluded that Gall bladder diseases are commonly seen among old age group. It is the disease of elderly women. Laparoscopic cholecystectomy is the treatment of choice. Post-operative complications are wound infection, jaundice, biliary fistula, nausea/vomiting, biliary strictures and incisional hernia.

REFERENCES

1. Adams DB. The importance of extra hepatic biliary anatomy in preventing complications at laparoscopic cholecystectomy. *Surg Clin N America*. 1993;73:861-71.
2. Eisendrath DN. Anomalies of the bile ducts and blood vessels as the cause of accidents in biliary surgery. *JAMA*. 1918;71:864-7.
3. Strasberg SM, Hertl M, Soper NJ. An analysis of the problem of biliary injury during laparoscopic cholecystectomy. *J Am Coll Surg*. 1995;180:101-25.
4. Xu F, Xu CG, Xu DZ. A new method of preventing bile duct injury in laparoscopic cholecystectomy. *World J Gastroenterol*. 2004;10:2916-8.
5. Hugh TB. New strategies to prevent laparoscopic bile duct injury-surgeons can learn from pilots. *Surgery*. 2002;132:826-35
6. Hugh TB, Kelly MD, Mekisic A. Rouviere's sulcus; a useful landmark in laparoscopic cholecystectomy. *Br J Surg*. 1997;84:1253-4.
7. Deziel DJ, Millikan KW, Economou SG, et al. Complications of laparoscopic cholecystectomy: a national survey of 4292 hospitals and an analysis of 77604 cases. *Am J Surg*. 1993;165:9-14.
8. Deziel DJ, Millikan KW, Economou SG, Doolas A, Ko ST, Airan MC. Complications of laparoscopic cholecystectomy: a national survey of 4,292 hospitals and an analysis of 77,604 cases. *Am J Surg*. 1993 Jan;165(1):9-14.
9. Duca S, Iancu C, Bălă O, Al-Hajjar N, Graur F, Puia IC, Munteanu D. Mini-invasive treatment of complications following laparoscopic cholecystectomy. *Acta Chir Belg*. 2004 Jun;104(3):309-12.
10. Khan MW, Aziz MM. Experience in laparoscopic cholecystectomy. *Mymensingh Med J*. 2010 Jan;19(1):77-84.