

Original Research

A Dermascopy study of cases of Alopecia areata

Col (Dr) Navtej Singh¹, Col (Dr) Vinay Gera²

¹Dept of Skin & Cosmetology, Command Hospital, Kolkata, West Bengal, India;

² Department of Dermatology Base Hospital Lucknow, U.P., India

ABSTRACT:

Background: Alopecia areata (AA) is a common, clinically heterogenous, immune-mediated, non-scarring hair loss disorder. The present study was conducted to assess the cases of Alopecia areata. **Materials & Methods:** The present study was conducted on 65 cases of Alopecia areata of both genders. Detailed clinical history followed by general physical examination, systemic examination and mucocutaneous examination was done in all. AA was graded as yellow dots, black dots, exclamation mark hairs, short vellus hairs and broken hairs. Hair loss was graded as- S0, no hair loss; S1, <25% hair loss; S2, 26%–50% hair loss; S3, 51%–75% hair loss; S4, 76%–99% hair loss; and S5, total scalp hair loss. **Results:** Out of 65 cases, males were 43 and females were 22. Grading of hair loss was S1 seen in 12, S2 in 6, S3 in 10, S4 in 13 and S5 in 24. The difference was significant ($P < 0.05$). Dermoscopic findings in patients were yellow dots in 20, vellus hair in 15, black dots in 14, exclamation mark in 6 and broken hairs in 2. The difference was significant ($P < 0.05$). **Conclusion:** Dermascopy is method of choice in AA cases. We found most common type as yellow dots and vellus hairs.

Key words: Alopecia areata, Dermascopy, Hair.

Received: 26 February, 2019

Revised: 29 March, 2019

Accepted: 30 March, 2019

Corresponding author: Col (Dr) Vinay Gera, Department of Dermatology Base Hospital Lucknow, U.P., India

This article may be cited as: Singh N, Gera V. A Dermascopy study of cases of Alopecia areata. J Adv Med Dent Sci Res 2019;7(5): 80-82.

INTRODUCTION

Alopecia areata (AA) is a common, clinically heterogenous, immune-mediated, non-scarring hair loss disorder. At any given time approximately 0.2% of world population suffers from Alopecia Areata (AA) with an estimated lifetime risk of 1.7%.¹ There is no clear conclusion about whether the disease varies according to sex. There appears to be no significant difference in the incidence of AA between males and females as both formal population studies found none, and hospital-based studies are mixed in citing a female vs male predominance.²

It is one of the most common forms of hair loss seen by dermatologists and accounts for 25% of all the alopecia cases.³ AA accounts for 2-3% of all new outpatient attendance in dermatology services. It is common throughout the world and has been estimated to affect between 0.2% and 2% of the US population. The incidence of AA in the general population is unknown but is less than 1%.⁴ At any given time 0.16%-0.2% of the population has

AA; approximately 1.7% of the population will experience an episode of AA during their lifetime. Dermascopy is a noninvasive diagnostic procedure used increasingly in dermatological practice not only for evaluation of pigmented skin lesions but also for hair disorders.⁵ The present study was conducted to assess the cases of Alopecia areata.

MATERIALS & METHODS

The present study was conducted in the department of Dermatology. It comprised of 65 cases of Alopecia areata of both genders reported to the department. The study was approved from the institutional ethical committee. All were informed regarding the study and written consent was obtained.

Data such as name, age, gender etc. was recorded. Detailed clinical history followed by general physical examination, systemic examination and mucocutaneous examination was done in all. The site was selected and lesion was observed

through the dermoscope. The cross-polarized lens of the dermoscope absorbs all the scattered light and hence allows only light in a single plane to pass through it. The photographs of the lesion were taken and recorded. AA was graded as yellow dots, black dots, exclamation mark hairs,

short vellus hairs and broken hairs. Hair loss was graded as- S0, no hair loss; S1, <25% hair loss; S2, 26%–50% hair loss; S3, 51%–75% hair loss; S4, 76%–99% hair loss; and S5, total scalp hair loss. Results were subjected to statistical analysis. P value less than 0.05 was considered significant.

RESULTS

Table I Distribution of patients

| Total- 65 | | |
|-----------|-------|---------|
| Gender | Males | Females |
| Number | 43 | 22 |

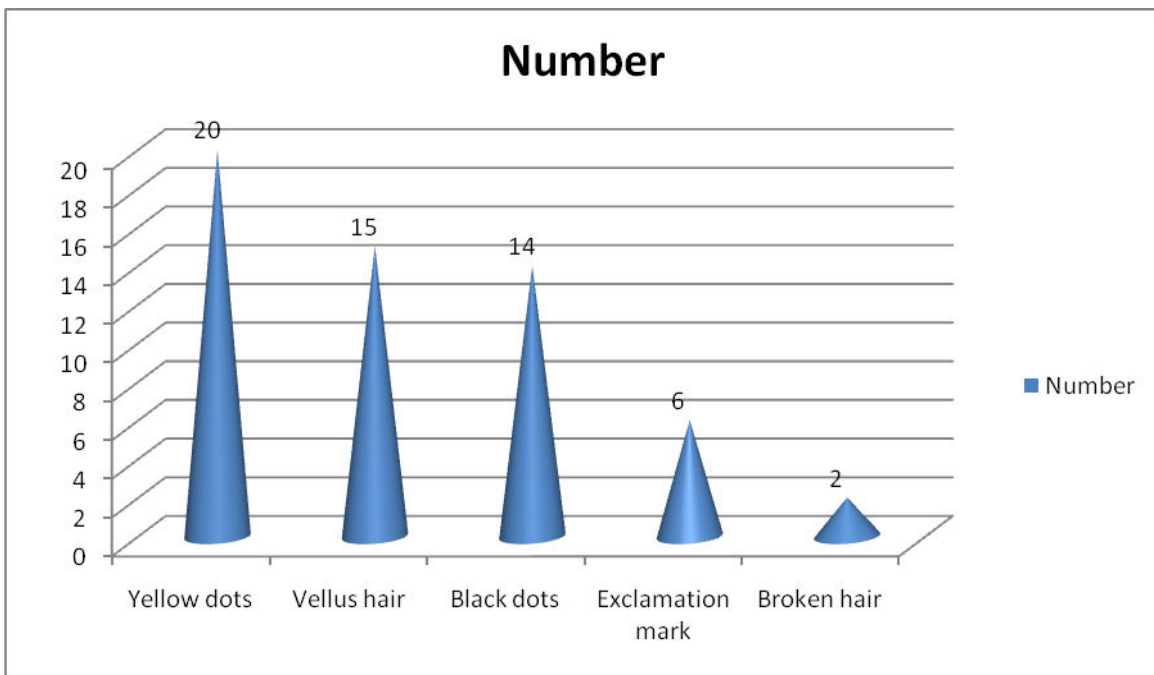
Table I shows that out of 65 cases, males were 43 and females were 22.

Table II Amount of hair loss

| Grading | Number | P value |
|---------|--------|---------|
| S1 | 12 | 0.021 |
| S2 | 6 | |
| S3 | 10 | |
| S4 | 13 | |
| S5 | 24 | |

Table II shows that grading of hair loss was S1 seen in 12, S2 in 6, S3 in 10, S4 in 13 and S5 in 24. The difference was significant (P< 0.05).

Graph I Dermoscopic findings



Graph I shows that dermoscopic findings in patients were yellow dots in 20, vellus hair in 15, black dots in 14, exclamation mark in 6 and broken hairs in 2. The difference was significant (P< 0.05).

DISCUSSION

AA is an autoimmune hair loss which frequently starts in childhood. Its presentation had an extreme variability not only in the time of initial onset but also in the duration, extent, and pattern of hair loss during any given episode of active loss.⁶ Moreover, the course of disease is unpredictable, with spontaneous regrowth of hair occurring in 80% of patients within the 1st year, and sudden relapse at any given time. Due to the clinical variability and unpredictable nature of spontaneous regrowth, diagnosis and management may be difficult and challenging.⁷ The present study was conducted to assess the cases of Alopecia areata.

In this study, out of 65 cases, males were 22 and females were 43. We found that grading of hair loss was S1 seen in 12, S2 in 6, S3 in 10, S4 in 13 and S5 in 24. Bapu et al⁸ found that the most common dermoscopic findings were yellow dots (84.1%), vellus hairs (62.6%), black dots (48.4%), exclamation mark (30.9%), and broken hair (9.5%), in decreasing order. Furthermore, the most common dermoscopic findings in patients on diphencyprone were vellus hairs and yellow dots. Yellow dots and vellus hairs were most common in patients with alopecia universalis. However, broken hairs and exclamation mark hairs were mostly observed in patchy multiple AA patients. Yellow dots and exclamation mark hairs were also significantly more common in patients with positive pull test. Furthermore, vellus hairs were more common in patients with remitting disease pattern. With regard to scalp severity, yellow dots related positively, while vellus hairs, broken hairs, and exclamation mark hairs related negatively with severity of disease.

We found that dermoscopic findings in patients were yellow dots in 20, vellus hair in 15, black dots in 14, exclamation mark in 6 and broken hairs in 2. Mahmoudi et al⁹ found that the youngest patient was a 4-year-old male and the oldest was 68-year-old female with a mean of 28.04 years in the present study. The maximum number of patients belonged to <20 years age group (36%). Among 50 cases, the highest duration was >6 months of 16 patients (32%) followed by 4-6 months of 18 patients (36%) and 1-3 months with 13 patients (26%) and <1 month with 3(6%) patients. 30 patients(60%) had lesions of size ≤ 2 cms, followed by 18 patients (36%) with size ranging from 3-5

cms, 2 patients(4%) have lesions of size ≥ 5 . Nail changes were noted in 9 patients (18%) and absent in 41 patients (82%). Recurrence of lesions of AA was present in 5 patients (10%).

Dermatoscopy (also known as dermoscopy or epiluminescence microscopy) is the examination of skin lesions with a 'dermatoscope'. This traditionally consists of a magnifier (typically x10), a non-polarised light source, a transparent plate and a liquid medium between the instrument and the skin, and allows inspection of skin lesions unobstructed by skin surface reflections. Modern dermatoscopes dispense with the use of liquid medium and instead use polarised light to cancel out skin surface reflections.¹⁰

CONCLUSION

Dermoscopy is method of choice in AA cases. We found most common type as yellow dots and vellus hairs.

REFERENCES

1. Wadhwa S. L., Uday, Khopkar and Jayakar, Thomas, Disorders of Hair, Chapter 25 in IADVL Textbook and Atlas of Dermatology, Valia R.G., Valia A. R., ISI Ed, Bombay: Bhalani Publishing House, 1998; 630-664.
2. Sharma V. K. Dhawan G, Kumar B. Profile of Alopecia Areata in Northern India. *Int J Dermatol* 1996; 35(1):22-27.
3. Shellow, William V. R. et. al., Profile of Alopecia Areata: A Questionnaire Analysis of Patient and Family. *Int J Dermatol*. 1992; 31(3):186-189.
4. Wasserman D, Guzman-Sanchez DA, Scott K, McMichael A. Alopecia areata. *Int J Dermatol* 2007; 46: 121-31.
5. Gordon KA, Tosti A. Alopecia: Evaluation and treatment. *Clin Cosmet Invest Dermatol* 2011;4:101-6.
6. Hillmann K, Blume-Peytavi U. Diagnosis of hair disorders. *Semin Cutan Med Surg* 2009;28:33-8.
7. Miteva M, Tosti A. Hair and scalp dermatoscopy. *J Am Acad Dermatol* 2012;67:1040-8.
8. Bapu NG, Chandrashekar L, Munisamy M, Thappa DM, Mohanan S. Dermoscopic findings of alopecia areata in dark skinned individuals: An analysis of 116 cases. *Int J Trichology* 2014;6:156-9.
9. Mahmoudi H, Salehi M, Moghadas S, Ghandi N, Teimourpour A, Daneshpazhooch M. Dermoscopic findings in 126 patients with alopecia areata: A cross-sectional study. *Int J Trichol* 2018;10:118-23.