

## CASE REPORT

# PLACEMENT OF DENTAL IMPLANT IN POSTERIOR MAXILLARY RIDGE USING INDIRECT SINUS LIFT TECHNIQUE WITHOUT GRAFT: A CASE REPORT

S.P.S Sooch<sup>1</sup>, Puja<sup>2</sup>, Seema Aggarwal<sup>3</sup>

<sup>1</sup>Associate Professor, <sup>2</sup>Junior Resident (MDS Final year), <sup>3</sup>Junior Resident (MDS First Year)

Dept of Oral and Maxillofacial Surgery, Punjab Govt Dental College and Hospital, Amritsar 143001, India

### ABSTRACT:

An adequate quality and quantity of bone is essential for successful implant therapy. The posterior edentulous maxillary region present special challenges to the implantologist that is unique to this region compared with other areas of mouth. Most important among these is the presence of maxillary sinus. To increase the amount of bone in the maxilla, sinus lift procedure have been developed. For this there are mainly two techniques: Direct approach which includes approaching the sinus laterally using either one step or two step antrostomy and the indirect approach which include approaching the sinus through alveolar crest using an osteotome. The indirect approach is less invasive as compared to direct approach. In the present case closed sinus floor elevation method without the use of any bone graft or bone augmentation material was done and the result was satisfactory.

Key words: sinus lift, Implant, Indirect approach, Schneiderian membrane

Corresponding author: Dr. Puja, Girls Hostel Punjab Govt Dental College and Hospital , Batala Road , Amritsar 143001, India, Email address: pujatopkhana4@gmail.com

This article may be cited as: Sooch SPS, Puja, Aggarwal S. Placement of dental impant in posterior maxillary ridge using indirect sinus lift technique without graft: A Case Report. J Adv Med Dent Scie Res 2016;4(3):67-71.

### INTRODUCTION

The placement of dental implants has revolutionized our ability as oral health care practitioners to manage and restore the edentulous posterior maxilla with a fixed prosthesis. The challenge of dental implant therapy in the posterior maxilla has driven the profession to develop new techniques for the management and treatment of the deficient maxillary alveolar ridge. Unlike the posterior mandible, where avoidance and management of the inferior alveolar nerve are paramount, the critical structure in the posterior maxilla is the sinus.<sup>1</sup>

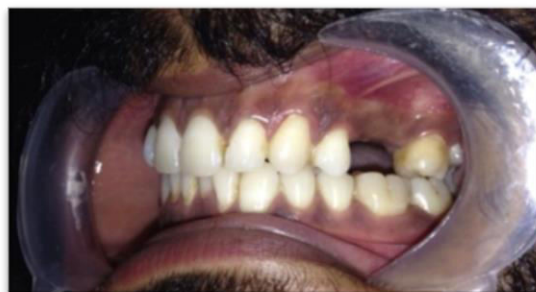Two different techniques of sinus augmentation are described in the literature: Direct<sup>2</sup> and Indirect.<sup>3-4</sup> The indication for indirect sinus augmentation is a minimum bone thickness of 5 mm underneath the sinus; otherwise, the direct sinus floor augmentation or a 2-stage indirect augmentation technique must be implemented. However, Misch<sup>5</sup> considered that 8 mm subantral bone height is the limit for the indirect sinus augmentation technique, 5–8 mm bone height is indicated for 1-stage direct augmentation with

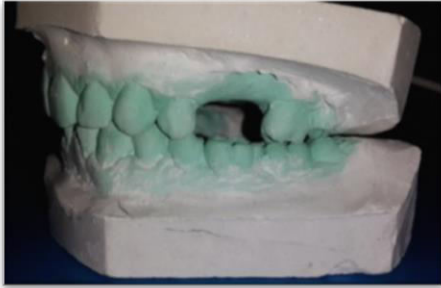implants, and cases with less than 5 mm bone height are indicated for the 2-stage direct augmentation technique.<sup>6</sup> The indirect approach being less invasive is more preferred over the direct one.<sup>7</sup> This case report describes one such indirect approach for maxillary sinus lift up in which implant placement was carried out simultaneously with elevation of the sinus floor.

### CASE REPORT

A 26-year-old male patient reported with the chief complaint of difficulty in chewing from right side because of loss of teeth in left upper back region. On oral examination, left upper 2<sup>nd</sup> premolar and left upper first molar was missing (Figures 1A and B).

A

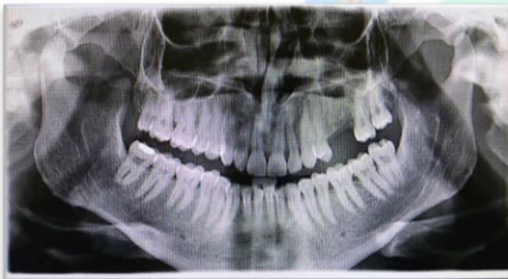



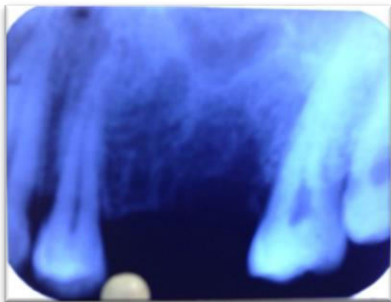
B

**Figure 1 A and B:** Preoperative photographs showing site for implant placement

On radiographic examination, the available bone height in edentulous region was found to be around 7 mm from the maxillary sinus lining. In this case, criteria, such as position of the implant, pre-existing tooth form and position, its relation with the opposing arch, soft tissue anatomy, maxillary sinus anatomy and bone dimensions were considered. After thorough oral and radiographic examination, two-stage surgery was planned. It was decided to lift up the sinus lining with an indirect approach through alveolar crest and simultaneously placing the implant



A



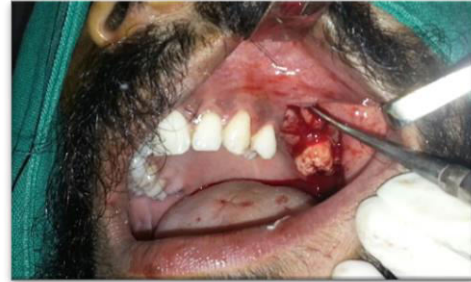B

**Figure 2:** Radiographs showing available bone height

The treatment was phased out in the following manner:

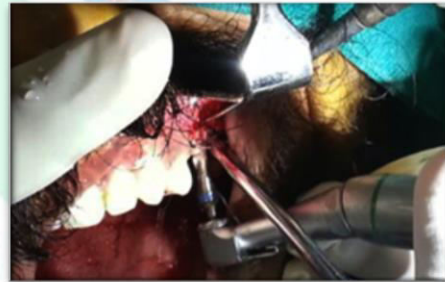1. Under strict aseptic environment and proper antibiotic coverage, Phenargan (1ml) as premedication was given intramuscularly 1 hour prior to surgery.
2. After proper draping with sterile sheets, local anaesthesia in the required area was given. A

midcrestal, full-thickness incision was performed. Once the flap was reflected the indirect approach begins with a marking drill of 1.90mm to mark the implant site (Figure. 3)



**Figure 3:** Midcrestal full-thickness incision

After the site was marked, a pilot drill with built in stopper dia. 2.40mm was used at a drill speed of 800-900 rpm with copious sterile saline irrigation. Then successive twist drills of 2.8mm, 3.2mm were used to prepare the osteotomy 2 mm short of the sinus floor. Final drill (conical drill dia. 3.30- 4.10) mm was not used so that implant compressed the bone so as to achieve primary stability.

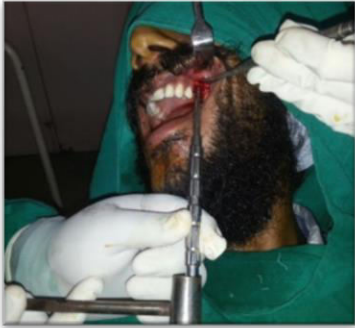

**Figure 4:** Drilling in the implant site

5. Convex shaped osteotome of the same diameter as the final osteotomy was selected. The osteotome was inserted and tapped firmly in 0.5 to 10mm increments beyond the osteotomy until reaching its final vertical position, upto 2mm beyond the prepared implant osteotomy. (Figure A and B).No intervening graft material was used.



A



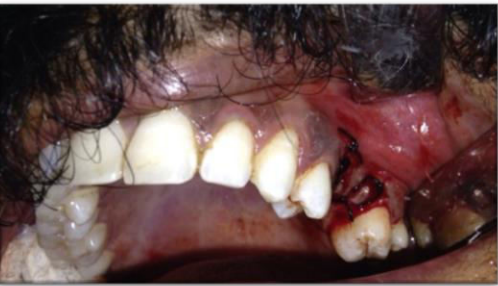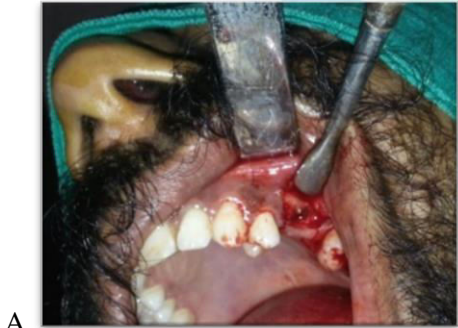**Figure 5:** A-Showing MIS OSTEOTOMES SET for indirect sinus Lift Procedure; **5 B-** showing use of Osteotome for Sinus Lift Up

6. A slow elevation of the sinus floor was less likely to tear the sinus mucosa.

This surgical approach compressed the bone below the antrum, caused a greenstick-type fracture in the antral floor, and slowly elevated the unprepared bone and sinus membrane over the broad-based osteotome.

7. A MIS SEVEN implant 8mm length and 4.2mm diameter was then inserted gently into the prepared site. The primary stability of the implant was checked.

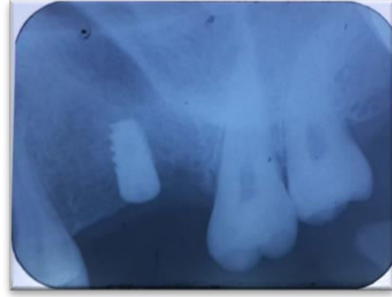8. The cover screw was then placed, the implants were covered with the mucosa and sutures were placed. (Figure. 6 A and B)



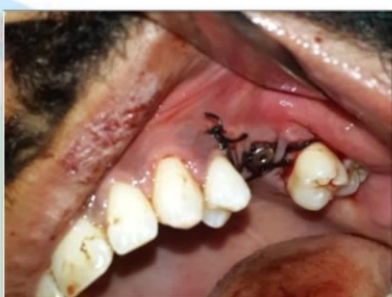**Figure 6 A and B:** Photograph showing cover screw and suturing

9. After 7 days, sutures were removed. There were no sinus related complications and no other complications related to the procedure.

After 6 months, prior to implant exposure, radiograph was taken so as to check for the osseointegration (Figure. 7). After satisfactory results, the implant was exposed and covered with the gingival former, so as to get the proper contour of the gingiva. (Figure. 8)



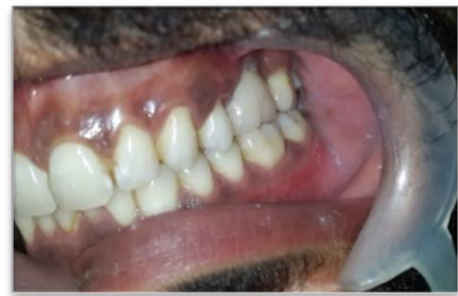**Figure 7:** Intraoral periapical photograph after 6 months showing satisfactory osseointegration



**Figure 8:** Gingival former placement

10. After a week, abutment was chosen and with the help of transfer coping, impression was made so as to get the master cast. The wax pattern was fabricated and casted and a metal framework was obtained.

11. The implant supported metal ceramic fixed prosthesis was fabricated (Figure 9).



**Figure 9:** Postoperative photograph showing final prosthesis

Patient was instructed about the maintenance of oral hygiene by means of dental floss, interdental brush and mouthwash. Also, the patient was called upon for recall visits after 1 week, 1 and 3 months.

Also in this case two teeth were missing i.e. left upper second premolar and left upper first molar. The mesiodistal space between the remaining adjacent teeth i.e. left upper first premolar and left upper second molar was 11mm. and the ideal width for the placement of two implants in the edentulous space should be around 13 mm, if we consider minimum distance of 1.5mm from adjacent natural tooth and 3mm between two implants. Here we are considering to insert two implants of width 3.3 mm and 3.75mm. So in total this gives 13.05mm. And we had mesiodistal width of 11 mm. therefore, we decided to put single implant with single prosthesis in our case.

At a follow up of 3<sup>rd</sup> month patient was satisfactory with the outcome.

## DISCUSSION

An adequate quality and quantity of bone is essential for successful implant therapy. The posterior edentulous maxillary region present special challenges to the implantologist that is unique to this region compared with other areas of mouth. Most important among these is the presence of maxillary sinus.

The schneiderian membrane which lines the sinus is adherent to the underlying bone. The structure beneath the sinus consist of the alveolar ridge and the posterior maxillary teeth. As the edentulous area continues to atrophy there is a continuing loss of bone height and density and increase in antral pneumatization. It is therefore common to find the sinus floor close to the alveolar crest. To increase the amount of bone in the maxilla sinus lift procedure have been developed

The most widely used approaches for sinus lift are:

- Direct approach which includes approaching the sinus laterally using either one step or two step antrostomy
- The indirect approach which include approaching the sinus through alveolar crest using an osteotome<sup>7</sup>

Lateral antrostomy (Direct approach) technique was first described by Tatum in 1976, first published by Boyne and James in 1980, and is commonly referred to as lateral antrostomy approach to the maxillary sinus floor. Currently, this method has become a

common surgical technique, as it allows regeneration of bone in the posterior maxilla. The primary procedural approach involves surgical access through the lateral wall of the zygomatic buttress of the maxilla followed by elevation of the sinus membrane and placement of bone-grafting material.

Complications of the lateral antrostomy technique may occur intraoperatively or postoperatively. Common intraoperative complications are perforation of the sinus membrane, bleeding and perforation of the buccal flap (very rarely).<sup>8</sup>

In crestal approach (indirect approach): The endosteal implant osteotomy is prepared as determined by the density of bone protocol, which is usually D3 bone. The depth of the osteotomy is approximately 1 to 2 mm short of the floor of the antrum. The implant osteotomy is prepared to the appropriate final diameter, short of the antral floor, following the established protocol for bone density. A flat-end or cupped-shape osteotome of the same diameter as the final osteotomy is selected. The osteotome is inserted and tapped firmly in 0.5- to 1.0-mm increments beyond the osteotomy until reaching its final vertical position, up to 2 mm beyond the prepared implant osteotomy. This surgical approach compresses the bone below the antrum, causes a greenstick-type fracture in the antral floor, and slowly elevates the unprepared bone and sinus membrane over the broad-based osteotome.<sup>9</sup>

The crestal approach is minimally invasive but permits only a limited amount of augmentation. Therefore, practitioners should select the type of procedure appropriate to the particular clinical needs. In addition, all relevant anatomic structures in the vicinity should be respected to minimize surgical complications.<sup>10</sup>

Hanan MR Shokier and Naglla shawky in 2009 conducted a study to evaluate the success rate of closed sinus lift with simultaneous implantation at 60 months postoperatively. The result of the study showed that at the end of the followup period all implants showed proper osseointegration, the bone density and height below elevated sinus lining increased in both grafted and ungrafted sides. The increase in the grafted side was not significant.<sup>11</sup>

Considering all these factors, the present study evaluated the closed sinus floor elevation method without the use of any bone graft or bone augmentation material.

In this case report, the radiographic examination revealed sinus to be 7 mm from the alveolar ridge, A

MIS SEVEN implant of 8 mm length and 4.2 mm diameter was used after elevation of sinus lining. Around 2 mm of rise in the sinus membrane was done so that after placement of implant, sufficient amount of space remains between the implant and sinus membrane.

The advantages of using indirect method over the direct one is that this procedure is less complex, less invasive and have a shorter healing and waiting period. The advantage of not using graft is that the procedure is less time-consuming, and comparatively inexpensive. Morbidity is lower than autogenous bone grafting since no extra graft material is needed.

### CONCLUSION

The goal of an indirect sinus lift technique without graft placement is to reduce the number of surgical procedures and to shorten the time-frame between surgery and restoration placement without compromising the implant success rate. Within its limitations, this study demonstrated that it is possible to successfully place the implant in posterior maxilla on simultaneously without graft using indirect sinus lift technique.

### REFERENCES

1. Tiwana PS, Kushner GM, Haug RH. Maxillary sinus augmentation. *Dent Clin N Am* 2006;50:409–424.
2. Tatum OH Jr. Osseous grafts in intra-oral sites. *J Oral Implantol*. 1996; 22:51–52.
3. Summers RB. The osteotome technique: part 3—less invasive methods of elevating the sinus floor. *Compend Contin Educ Dent*. 1994;15:698–710.
4. Coatoam GW. Indirect sinus augmentation procedures using one-stage anatomically shaped root form implants. *J Oral Implantol*. 1997;23:25–42
5. Misch CE. Maxillary sinus augmentation for endosteal implants: organized alternative treatment plans. *Int J Oral Implantol*. 1987;4:49–58.
6. Agamy TM, Niedermeier W. Indirect Sinus Floor Elevation for Osseointegrated Prosthesis. A 10-Year Prospective Study. *J Oral Implantology* 2010; 36(2): 113-121.
7. Agnihotri A, Agnihotri D. Maxillary sinus lift up: an indirect approach for implant placement in posterior maxilla. *Int J Oral Implant Clin Res*. 2012;3(2):101-4
8. Hussam B and Olena N. lateral antrostomy technique for maxillary sinus augmentation , C.E. article\_ lateral antrostomy technique , implants 1\_2013)
9. Misch CE. *Contemporary Implant Dentistry*. (3<sup>rd</sup> edition)
10. Woo and BTL. Maxillary Sinus Floor Elevation: Review of Anatomy and Two Techniques *Implant Dentistry* 2004;13:
11. Hanan M.R Shokier and Naglaa Shawky Long term follow up for Closed Technique of sinus lift with simultaneous implantation with and without grafting Using Direct Digital Radiography and CT scan *Cairo Dental Journal* 2009;43:52.

**Source of support:** Nil

**Conflict of interest:** None declared

This work is licensed under CC BY: **Creative Commons Attribution 3.0 License**.