

## ORIGINAL ARTICLE

# CLINICAL AND RADIOGRAPHICAL SIGNS IN PATIENTS WITH SPINAL TUBERCULOSIS- A CLINICAL STUDY

Sanjay Singh<sup>1</sup>, Lalit Kumar Mishra<sup>2</sup>

<sup>1</sup>Associate Professor, <sup>2</sup>Professor, Department of T.B. & Chest, Career Institute of Medical Sciences and Hospital, Lucknow, U.P, India


### ABSTRACT:

**Background:** TB is presently a global epidemic with over two billion people, equal to one third of the world's population currently estimated to be infected, with 8.8 million new TB cases identified worldwide and 1.4 million deaths annually. The present study was conducted to evaluate the cases of spinal TB among patients suffering from TB. **Materials & Methods:** This study was conducted in department of Chest and Tuberculosis in year 2013. It comprised of 40 patients with TB. All patients were diagnosed with the criteria suggestive of TB and Montoux test. Imaging technique such as MRI and CT scan was also done to reach the diagnosis. **Results:** Out of 40 patients, 18 were males and 22 were females. The difference was non- significant ( $P > 0.05$ ). Age group 15-30 years had males (8) and females (10). Age group 30-45 years had males (6) and females (8). Age group 30-45 years had males (4) and females (4). The difference was non- significant ( $P > 0.05$ ). Common symptoms seen in patients were backache (36), fever (18), loss of appetite/weight (20), night sweats (8), kyphoscoliosis (6), gibbus deformity (4), lower limb neuro -deficit (12) and sphincter deformity (4). MRI and CT findings in patients were end plate sclerosis (11) and (9) respectively. Paraspinal soft tissue masses (7) and (5) respectively. Unilateral psoas abscess (2) and (1) respectively, Discitis (1) and (2) respectively. Extradural cord compression (1) and (2) in MRI and CT scan respectively. Intrathecal root compression (1) in CT scan. Spinal cord and root compression (4) in MRI. Body destruction (1) and (2) in MRI and CT scan respectively. **Conclusion:** Spinal tuberculosis is mostly seen in younger age group as in our study. Clinical features and radiographical signs are of diagnostic value which helps in early identification of disease and management.

**Key words:** Kyphoscoliosis, Montoux, Spinal tuberculosis

Corresponding Author: Dr. Sanjay Singh, Professor, Department of T.B. & Chest, Career Institute of Medical Sciences and Hospital, Lucknow, U.P, India

This article may be cited as: Singh S, Mishra LK. Clinical and radiographical signs in patients with spinal tuberculosis- A clinical study. J Adv Med Dent Scie Res 2017;5(1):83-86.

Access this article online	
<b>Quick Response Code</b> 	Website: <a href="http://www.jamdsr.com">www.jamdsr.com</a>
	DOI: 10.21276/jamdsr.2017.5.1.17

## INTRODUCTION

Tuberculosis (TB) is one of the oldest diseases affecting mankind and has been found in skeletal remains from the ancient mummies of Egypt and Peru. The disease is caused by the bacillus *Mycobacterium tuberculosis*, and occasionally by *Mycobacterium bovis*, and *Mycobacterium africanum*. It is the most common infectious disease causing deaths in humans.<sup>1</sup>

TB is presently a global epidemic with over two billion people, equal to one third of the world's population currently estimated to be infected, with 8.8 million new TB cases identified worldwide and 1.4 million deaths annually.<sup>2</sup> Global estimates indicate that women account for about 3.6 million cases of TB. The situation is more complicated in countries like India where TB kills more women than any other infectious disease and more than all

causes of maternal mortality combined. Moreover, about 100,000 women are rejected by their families each year because of TB, strongly impacting their children and families. In India alone, 30,000 children leave school annually, on account of their parents' TB.<sup>3</sup>

Pathogenesis of skeletal TB is related to reactivation of haematogenous foci or spread from adjacent paravertebral lymph nodes. Weight bearing joints (spine 40%, hips 13%, and knee 10%) are most commonly affected. Spinal TB (STB, Pott's disease) is uncommon in developed countries, but is encountered frequently in the endemic regions. This often involves two or more adjacent vertebral bodies and destruction of these causes spinal deformities and neurological complications.<sup>4</sup>

The present study was conducted to evaluate the cases of spinal TB among patients suffering from TB.

**MATERIALS & METHODS**

This study was conducted in department of Chest and Tuberculosis in year 2013. It comprised of 40 patients with TB. Patients were informed regarding the study and consent was taken. Patient’s information regarding name, age, gender etc was recorded on case history performa. The diagnosis of STB was made based on a combination of clinico-radiological and biochemical tests. The criteria for diagnosis were as follows; 1. Symptoms over one month duration, 2. specific features on MR/CT imaging, 3. exclusion of alternative spinal disease, 4. raised inflammatory markers or positive Mantoux testing or both. If patients had only the above criteria, they were categorized as probable STB; if also showed confirmatory microscopical or histopathological evidence on examination of paraspinal aspirates or tissue biopsy when performed, they were categorized as definite STB. Both probable and definite STB categories were included in this study, while others with possible STB, but did not fulfill the above diagnostic criteria were excluded. Results were tabulated and subjected for correct inferences. P value < 0.05 was considered significant.

**RESULTS**

Table I shows that out of 40 patients, 18 were males and 22 were females. The difference was non- significant (P > 0.05). Table II shows that age group 15-30 years had males (8) and females (10). Age group 30-45 years had males (6) and females (8). Age group 45-60 years had males (4) and females (4). The difference was non- significant (P > 0.05). Graph I shows that common symptoms seen in patients were backache (36), fever (18), loss of appetite/ weight (20), night sweats (8), kyphoscoliosis (6), gibbus deformity (4), lower limb neuro -deficit (12) and sphincter deformity (4). Graph II shows MRI and CT findings in patients were end plate sclerosis (11) and (9) respectively. Paraspinal soft tissue masses (7) and (5) respectively. Unilateral psoas abscess (2) and (1) respectively, Discitis (1) and (2) respectively. Extradural cord compression (1) and (2) in MRI and CT scan respectively. Intrathecal root compression (1) in CT scan. Spinal cord and root compression (4) in MRI. Body destruction (1) and (2) in MRI and CT scan respectively.

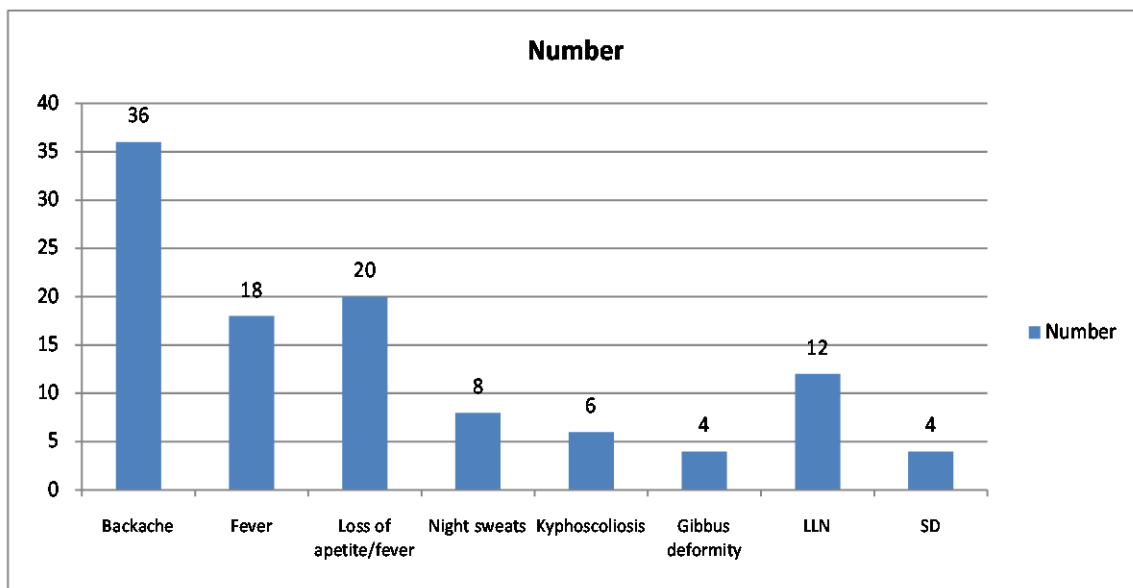
**Table I** Distribution of patients

Total - 40		
Male	Female	P value
18	22	0.2

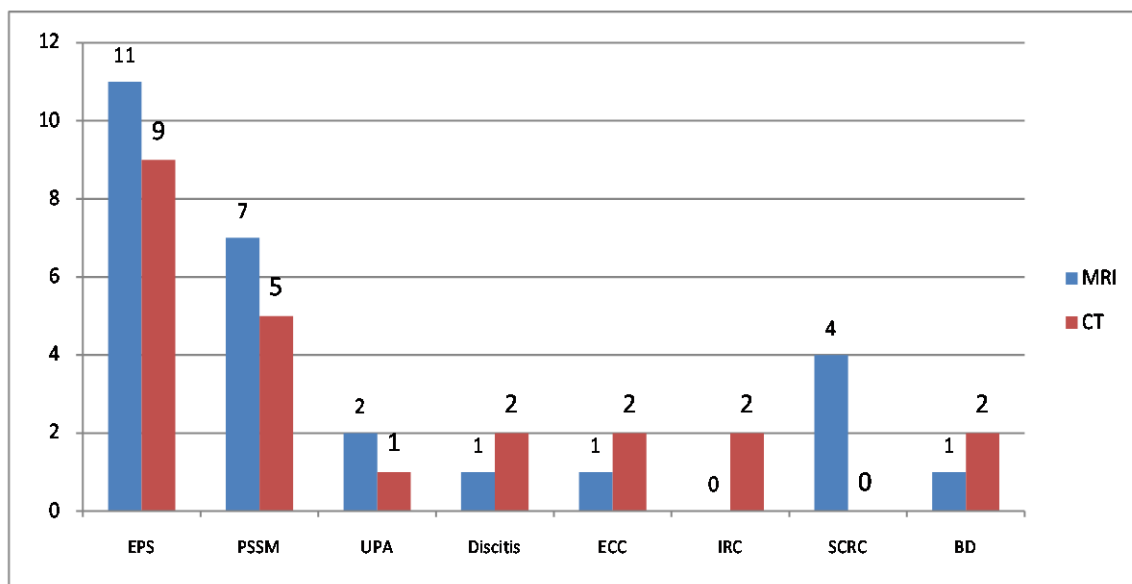
**Table II** Distribution of patients on the basis of age

Age group	Males	Females
15-30	8	10
30-45	6	8
45-60	4	4
<b>Total</b>	<b>18</b>	<b>22</b>

**Graph I** Symptoms reported in patients



**Graph II** MRI and CT findings in patients



**DISCUSSION**

Spinal tuberculosis is usually a secondary infection from a primary site in the lung or genitourinary system. Spread to the spine is hematogenous in most instances, Delayed hypersensitivity immune reaction. Initially, a pre-pus inflammatory reaction with Langerhan’s giant cells, epithelioid cells, and lymphocytes.<sup>5</sup> The granulation tissue proliferates, producing thrombosis of vessels. Tissue necrosis and breakdown of inflammatory cells result in a paraspinal abscess. The pus may be localized, or it may track along tissue planes. Progressive necrosis of bone leads to a kyphotic deformity. Typically, the infection begins in the anterior aspect of the vertebral body adjacent to the disk. The infection then spreads to the adjacent vertebral bodies under the longitudinal ligaments. Noncontiguous (skip) lesions are also seen occasionally.<sup>6</sup> The present study was conducted to evaluate the cases of spinal TB among patients suffering from TB. This study was conducted in department of Chest and Tuberculosis in year 2013. It comprised of 40 patients with TB.

Out of 40 patients, 18 were males and 22 were females. We found that maximum number of patients was seen in age group 15-30 years with 8 males 10 females. Our results are in agreement with Chin Yun weng et al.<sup>7</sup> However study done by Nussbaum ES et al<sup>8</sup> found that maximum number of spinal TB patients was seen in 4<sup>th</sup> decade of life. We found that common symptoms seen in patients were backache, fever, loss of appetite/ weight, night sweats, kyphoscoliosis, gibbus deformity, lower limb neuro-deficit and sphincter deformity. Cormican L et al<sup>9</sup> found that night sweats and loss of weight are consistent features in patients with TB.

Diagnosis of STB is challenging worldwide, due to lack of advanced radiological and operative facilities in the

developing world and due to low suspicion in the developed world. Imaging features of STB have been well described. We found that on MRI and CT scan, findings in patients were end plate sclerosis, paraspinal soft tissue masses, unilateral psoas abscess, discitis, extradural cord compression, intrathecal root compression, spinal cord and root compression and body destruction. Moorthy S et al<sup>10</sup> found that extradural cord compression and intrathecal root compression are the serious radiological signs seen in patients with STB.

Relative disc sparing is considered virtually pathognomonic for STB. However, mild reduction of disc height can be seen early in the disease, as was seen in our patients also. This apparent disc narrowing is postulated to be due to herniation of the disc in to partially destroy vertebral bodies, rather than true spread of infection.

**CONCLUSION**

Spinal tuberculosis is mostly seen in younger age group as in our study. Clinical features and radiographical signs are of diagnostic value which helps in early identification of disease and management.

**REFERENCES**

1. Joseffer SS, Cooper PR. Modern imaging of spinal tuberculosis. *J Neurosurg Spine*. 2005; 2: 145-50.
2. Stabler A, Reiser MF. Imaging of spinal infection. *Radiol Clin North Am*. 2001; 39: 115-35.
3. Turgut M. Spinal tuberculosis (Pott’s disease): its clinical presentation, surgical management, and outcome. A survey study on 694 patients. *Neurosurg Rev*. 2001; 24: 8-13.
4. MacDonnell AH, Baird RW, Bronze MS. Intramedullary tuberculomas of the spinal cord: case report and review. *Rev Inf Dis*. 1990; 12: 432-9.

5. Davidson PT, Horowitz I. Skeletal tuberculosis: A review with patient presentations and discussion. *Am J Med.* 1970; 48: 77-84.
6. Jain AK, Dhammi IK. Tuberculosis of the Spine: A Review. *Current Orthopaedic Practice.* 2007; 460: 39- 49.
7. Ching-Yun Weng, Chin-Yu Chi, Pai-Jun Shih, Cheng- Mao Ho, Po-Chang Lin, Chia-Hui Chouc, et al. Spinal tuberculosis in non-HIV infected patients: 10-year experience of a medical centre in Central Taiwan. *J Microbiol Immunol Infect.* 2010; 43: 464-9.
8. Nussbaum ES, Rockswold GL, Bergman TA, Erickson DL, Seljeskog EL. Spinal tuberculosis: a diagnostic and management challenge. *J Neurosurg.* 1995; 83: 243-7.
9. Cormican L, Hammal R, Messenger J, Milburn HJ. Current difficulties in the diagnosis and management of spinal tuberculosis. *Postgrad Med J.* 2006; 82: 46-51.
10. Moorthy S, Prabhu NK: Pictorial essay – Spectrum of MR imaging findings in spinal tuberculosis. *AJR.* 2002; 179: 979-83.

**Source of support:** Nil

**Conflict of interest:** None declared

This work is licensed under CC BY: *Creative Commons Attribution 3.0 License.*