

## Journal of Advanced Medical and Dental Sciences Research

@Society of Scientific Research and Studies

Journal home page: [www.jamdsr.com](http://www.jamdsr.com)

doi: 10.21276/jamdsr

(e) ISSN Online: 2321-9599; (p) ISSN Print: 2348-6805

### Original Article

## Comparative Reliability of Cheilioscopy, Rugoscopy and Radiography in Gender Determination

Andleeb Manhas, Sadaf Antoo, Swati, Amit Nayar, Aman Sharma

Department of Oral Pathology and Microbiology Swami Devi Dyal Hospital and Dental College, Panchkula, Haryana, India

#### ABSTRACT:

**Aim:** To compare the reliability of Cheilioscopy, Rugoscopy and Dentofacial radiography in gender determination. To study the prevalent rugae pattern and lip print patterns in males and females in college going students in Haryana and to assess the usefulness of mandibular ramus as an aid in gender determination. **Material and Methods:** A total of 60 subjects, 30 males and 30 females were selected, their ages ranging between 20 - 30 years. All subjects will be healthy individuals free of congenital abnormalities, inflammation, trauma or orthodontic treatment. Lip prints, rugae impressions and a standard OPG was recorded for each patient.

**Results and Conclusion:** Lip prints, though give an indication to the gender of an individual compared with records has been accepted in the court of Law). Most of the thickness of the lips), or Type I' (Vertical grooves not running across the entire thickness of the lips individual, cannot be used as conclusive in Dental Profiling (even though the use of Lip prints, w). The Type lip prints studied by us fell into the Type I (Vertical grooves running across the entire I was more prevalent in Females, while Type I' was more prevalent in Males. However, we need to take into consideration several other factors, such as the difference in thickness of lips between males and females before we can consider this as conclusive. For the rugae pattern, we found that curved pattern were more prevalent in the population studied by us in both males and females. Following this, wavy pattern was more prevalent in females and straight pattern in males. *The* study of the mandible has offered scope towards providing a reliable parameter in gender identification. 5 variables in the mandible were recorded: Maximum Ramus width, Minimum Ramus width, Condylar Height, Projection height of the ramus, and Coronoid Height. The findings were found to be quantitatively more in males than females. This offers a potential to be used as a potential tool in gender identification. *The* study of the mandible has offered scope towards providing a reliable parameter in gender identification. 5 variables in the mandible were recorded: Maximum Ramus width, Minimum Ramus width, Condylar Height, Projection height of the ramus, and Coronoid Height. The findings were found to be quantitatively more in males than females. This offers a potential to be used as a potential tool in gender identification.

**Key words:** Cheilioscopy, lip prints, rugoscopy and radiography.

Received: 11 September 2018

Revised: 22 October 2018

Accepted: 25 October 2018

**Corresponding Author:** Dr. Andleeb Manhas, Department of Oral Pathology and Microbiology Swami Devi Dyal Hospital and Dental College, Panchkula, Haryana, India

**This article may be cited as:** Manhas A, Antoo S, Swati, Nayar A, Sharma A. Comparative Reliability of Cheilioscopy, Rugoscopy and Radiography in Gender Determination. J Adv Med Dent Scie Res 2018;6(11):62-67.

#### INTRODUCTION:

Human identification is a challenging subject that man has been confronted with. Human identification is based on scientific principles, mainly involving fingerprints, DNA comparisons and dental records.<sup>2</sup> Although DNA testing is considered to be the gold standard in forensic science but is costly procedure and cannot be conducted for everybody.<sup>3</sup> There are some limitations to the use of fingerprints that occur in situations where the hands are damaged or mutilated and while teeth are more durable, identification using dental records may also prove to be inconclusive, since many ante mortem dental records may be inaccurate or incomplete. Also, under certain

incidences when hard tissues (teeth) of the oral cavity are lost due to factors such as trauma, visual means of identification is significant in non-mutilated palatal tissues. The palate is protected to a large extent by the teeth and other tissue of the head & neck due to its anatomical location, and therefore in conditions where the teeth are charred or destroyed, the palatal morphology is salvageable. Thus, in forensic dentistry, the unique characteristic pattern of palatal rugae can be used as an identification tool. Palatal rugae also known as Plica Palatinae Transverse, refer to a series of transverse ridges on the anterior part of the palatal mucosa. Palatal rugae have been shown to be highly individual and consistent in

shape throughout life. Application of palatal rugae patterns for personal identification was suggested by Allen in 1889. The term “**Palatal rugoscopy**” was first proposed by the Spanish investigator Trobo Hermosa. Identification of palatal rugae pattern is based on classification by Thomas *et al.* This classification includes number, length, shape and identification pattern of rugae. The identification of an individual by the use of Lip Prints is referred to as **Chelioscopy**. Lip prints deal with the characteristics found on the lips. This form of identification is gradually becoming popular throughout the world. The use of radiography in sex determination has been recognized for considerable period of time. As evident from earlier studies, skull is the most dimorphic and easily sexed portion of the skeleton after pelvis, providing accuracy up to 92%<sup>6</sup>. But in cases where intact skull is not found, mandible may play a vital role in sex determination as it is most dimorphic, largest, and strongest bone of the skull. Male bones are generally bigger and more robust than female bones. Recent times have seen the emergence of chelioscopy and palatoscopy as reliable indicators of genders. At the same time, numerous other studies have reported the use of Radiography in identifying the gender of an individual. It is therefore, plausible that increasing the number of variable may lead to an improved accuracy in gender determination in Forensic Odontology. The present, therefore, study aims to ascertain the use of lip prints and palatal rugae pattern and dentofacial radiography in gender differentiation.

#### **MATERIAL AND METHODS:**

This cross sectional study was conducted in the department of Oral Pathology and microbiology at Swami Devi Dyal Hospital and Dental College, Barwala.

#### **Sample collection:**

A total of 60 subjects, 30 males and 30 females were selected, their ages ranging between 20 - 30 years. All subjects will be healthy individuals free of congenital abnormalities, inflammation, trauma or orthodontic treatment. Lip prints, rugae impressions and a standard OPG was recorded for each patient using the following criteria.

#### **METHODOLOGY FOR CHELIOSCOPY**

##### **Inclusion and Exclusion criteria:**

Patients reporting for routine dental check up were included in the study. Care was taken to select individuals with no lesions on the lips. Individuals with known hypersensitivity to lipsticks were not included in the study.

##### **METHOD:**

A lip impression was made with the help of a dark coloured lipstick. A thin layer of lipstick was applied evenly on the vermilion border and left for 3 min and the impression was taken on a strip of cellophane tape, on the glued portion. The strip of the tape was gently pressed

from the right side of subject's lips to the left end. It was taken care that during the process, the lips of the subject should be relaxed and slightly separated. Care was taken that the tape covered the entire length and breadth of both the upper and the lower lip. The tape bearing the lip prints was then lifted and pasted onto a white bond paper (Figure 1A&B). This served as a permanent record. The same technique has been used for both upper and lower lips. The impressions were subsequently visualized with the use of a magnifying lens. The number of lines and furrows present, their length, branching and combinations were noted. The lip prints obtained were coded, while noting the name and sex of the respective individuals. At the time of analysis the sex of the print was not disclosed. In this study, we followed the classification of patterns of the lines on the lips proposed by Suzuki and Tsuchihashi (1970)<sup>14</sup>.

Type 1 :Clear-cut vertical grooves that run across the entire lips

Type 1': Similar to type 1, but do not cover the entire lip

Type 2 :Branched grooves

Type 3 :Intersected grooves

Type 4 :Reticular grooves

Type 5: Grooves do not fall into any of the type 1-4 and cannot be differentiated morphologically (undetermined)

The sex of the individual was determined as per the predominant pattern prevalent in the individual. The results obtained were then verified from the coded data collected at the beginning of the study.

#### **METHODOLOGY FOR RUGOSCOPY**

To record palatal rugae, alginate impressions of the maxillary arch were made (Coltoprint NCR) and poured with improved dental stone {Kaldent, Kalabhai} (Figure 2&3). A dental plaster base was made and casts were preserved for interpretation. The outline of the rugae was traced on these casts using a sharp graphite pencil under adequate light moving the pencil at right angle to the cast. A photograph of the cast was then taken following standardization. The palatal rugae pattern were then analyzed on these photographs with the help of magnifying lens according to classification given by Thomas and Kotze (1983) and Kapali et al. (Figure 4 A & B).

Rugae were tested for both genders and for both sides of the palate using the following parameters:

1. Total number of rugae
2. Size of rugae
3. Predominant shape

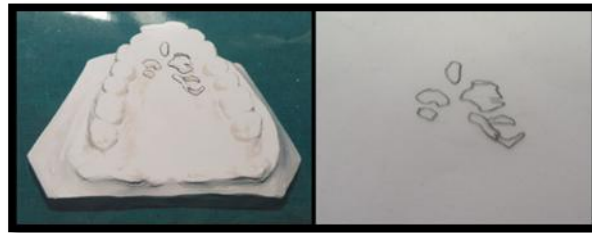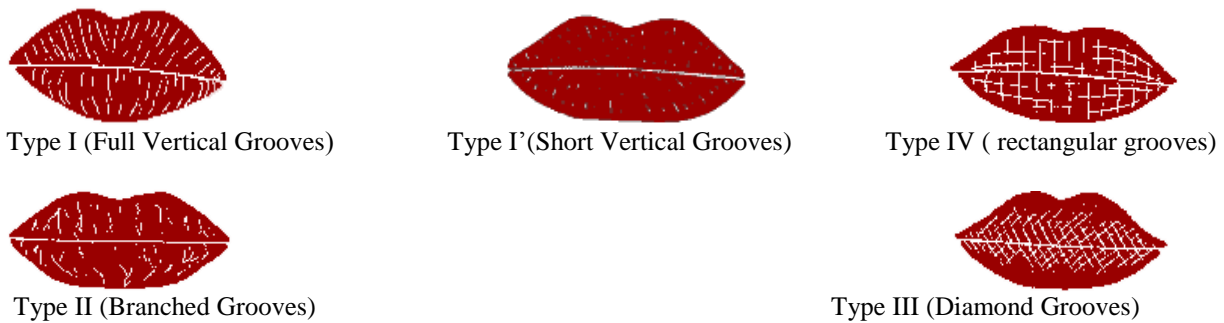
#### **METHODOLOGY FOR DENTOFACIAL RADIOGRAPHY**

The patients were asked to stand in front of OPG machine. The head was positioned according to lateral forehead and chin rest and the patient was asked to bite on the bite block. The radiograph was taken with a OPG machine (GME) for 15 seconds at 60 to 88 Kva. Ideal OPG of completely dentate subject was selected for the study. (Figure 5A&B). Pathological fracture,

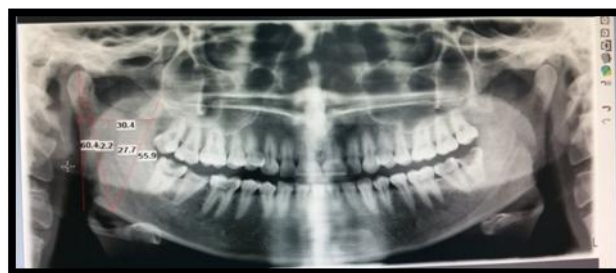
developmental disturbances of mandible, deformed and edentulous mandible were excluded from the study. The following parameters were measured of the right side using mouse –driven method.

- 1) **Maximum ramus breadth:** The distance between the most anterior point on the mandibular ramus and a line connecting the most posterior point on the condyle and the angle of jaw.
- 2) **Minimum ramus breadth:** Smallest anterior-posterior diameter of the ramus.
- 3) **Condylar height/ maximum ramus height:** Height of the ramus of the mandible from the most superior point on the mandibular condyle to the tubercle, or most protruding portion of the inferior border of the ramus.
- 4) **Projective height of ramus:** projective height of the ramus between the highest point of the mandibular condyle and lower margin of the bone.
- 5) **Coronoid height:** Projective distance between coronoid and lower walls of the bone.

**Figure 1:** Pictomicrographs showing classification of various lip patterns according to Suzuki and Tsuchihashi. (1970 and 1974)



**Figure 2:** Maxillary impression making with perforated metal tray



**Figure 3:** Showing measurements of mandibular ramus orthopantomographs



**Figure 4:** Showing lip prints taken of the subjects with lipstick

**RESULTS:**

**TABLE 1: DISTRIBUTION OF NUMBER AND PERCENTAGE OF INDIVIDUAL LIP PRINT PATTERNS ACCORDING TO GENDER**

Predominant lip print pattern	Male	Percentage (%)	Female	Percentage (%)	TOTAL %	Chi sq	P value
Type I	5	16.67	8	26.67	13 (21.67%)	4.31	0.037
Type I'	7	23.30	7	23.30	14 (23.3%)	-	-
Type II	7	23.30	5	16.67	12 ( 20%)	3.31	0.033
Type III	7	23.30	4	13.33	11 (18.33%)	2.71	0.047
Type IV	3	10.00	4	13.33	7 (11.67%)	1.11	0.065
Type V	1	3.33	2	6.67	3 (5%)	1.71	0.052
<b>Total</b>	30		30				

Out of total 60 samples studied type I' lip pattern showed the maximum occurrence of 23.3%, followed by type I (21.67%), then Type II (20%), Type III (11%), Type IV (11.67%) and least was type V (5%).

When males and females were compared with each other it was seen that in males type I' pattern showed maximum occurrence i.e 23.30% while in females type I pattern was predominant i.e 26.67% . Type V pattern was found to be least observed in both males and females (males-3.33% & females- 3%).

**TABLE 2: COMPARISON OF DIFFERENT SHAPES OF RUGAE IN MALES AND FEMALES**

Type	%	Total			Males			Females			P value
		Total	Mean	SD	Total	Mean	SD	Total	Mean	SD	
Straight	28.00	176	2.93		95	3.16		81	2.70	0.55	0.049
Curved	46.00	290	4.83		157	5.23		133	4.43	0.91	0.033
Wavy	15.00	95	1.58		43	1.43		52	1.73	0.19	0.027
Divergent	6.20	39	0.65		21	0.70		19	0.63	0.22	0.061
Convergent	4.2	30	0.50		13	0.43		17	0.57	0.11	0.057
<b>Total</b>		630			325			305			

The frequency of different shapes of 630 total rugae was found to be – 290 (46.00%) curved, 176 (28.00%) straight, 95 (15.00%) wavy, 39 (6.20%) unification divergent followed by 30 (4.20%) unification convergent.

Further it was observed that both in males and females curved type of rugae were found to be maximum (Males: 54.10% with a mean of 5.23, Females: 45.86% with a mean of 4.43). Next in descending order were straight type of rugae (Males: 53.98% with a mean of 3.16, Females: 46.02% with a mean of 2.70), Wavy (Males: 45.26% with a mean of 1.43, Females: 54.73% with a mean of 1.73), Unification divergent (Males: 53.85% with a mean of 0.7, Females: 48.72% with a mean of 0.63), Unification convergent (Males: 43.33% with a mean of 0.43, Females: 56.67% with a mean of 0.57) However when different shapes of rugae were compared between males and females, It was found that, males had a higher mean proportion of curved, straight and divergent type of rugae as compared to females. In females a higher mean proportion of wavy and unification convergent was seen.

**TABLE 3: COMPARISON OF RUGAE ACCORDING TO SIZE IN MALES AND FEMALES**

Type	%	Total			Males			Females			P value
		Total	Mean	SD	Total	Mean	SD	Total	Mean	SD	
Primary	81.90	516	8.60		266	8.86		250	8.33	0.89	0.03
Secondary	14.92	94	1.56		48	1.60		45	1.50	0.34	0.59
Fragmentary	3.17	20	0.33		11	0.37		10	0.33	0.29	0.61
<b>Total</b>		630			325			305			

Out of total 630 rugae in 60 individuals, it was found that 516 (81.90% with a mean of 8.6) were primary rugae, 94 (14.92% with a mean of 1.56) were secondary rugae and 20 (3.17% with a mean of 0.33) were fragmentary rugae.

In males as well as females, the mean number of primary rugae were observed to be maximum (Males: 8.86, Females: 8.33) followed by secondary rugae (Males: 1.6, Females: 1.5) and fragmentary rugae (Males: 0.37, Females: 0.33). No significant difference was found in the type of rugae based on size when males and females were compared with each other.

**TABLE 4: MEAN VALUES OF ALL FIVE MANDIBULAR RAMUS MEASUREMENTS FOR BOTH MALE AND FEMALE**

	VARIABLE (PARAMETERS)	MALE	FEMALE
1.	MAX.RAMUS BREADTH	34.4	32.1
2.	MIN RAMUS BREADTH	29.3	29.3
3.	CONDYLAR HEIGHT	68.7	64.9
4.	PROJECTIVE HEIGHT OF RAMUS	68.1	63.2
5.	CORONOID HEIGHT	61.9	58.5

This table shows Descriptive statistics of all five mandibular ramus measurements for both sexes are shown. Max. ramus breadth in males showed a mean of 34.4 and in females 32.1., Min ramus breadth in males showed a mean of 29.3 and in females 29.3, condylar height with mean of 68.7 in males and 64.9 in females, projection height with mean of 68.1 in males and 63.2 in females and last parameter of condylar height showed an mean of 61.9 in males and 58.3 in females.

**DISCUSSION**

When ante-mortem dental records are unavailable and other methods of identification are unreliable or not possible, the forensic odontologist can assist in limiting the population pool to which the deceased / suspect is likely to belong, a process known as **Dental Profiling**. Dental Profiling helps narrow down the range of variable parameters such as age, gender, ancestry background, socio-economic status etc. Dental profiling uses dental and skeletal characteristics in age determination , blood antigens and restorative material from remains by comparing antemortem and post mortem records via cheilioscopy and palatoscopy are some of the methods practiced in the field of forensic Odontology.

Forensic odontology has achieved giant strides in recent times and the use of palatal rugae in post mortem identification has gained prominence over several decades and many studies have been carried out on rugae patterns .Palatal rugoscopy is the study of rugae pattern in order to establish the identity of a person .Palatal rugae are irregular, asymmetrical ridges present on the anterior palate just behind the incisive papillae on either side of median palatine raphe.

The results of our study showed that Type I pattern of lip prints was most commonly found in females, while Type I was more prevalent in males. These findings were in accordance with previous studies of similar nature. Keeping in mind the similarity between Type I and Type I', it may be further hypothesized that the lip prints are essentially the same in a specific racial group, and that variations between males and females are essentially variations of the same basic pattern. The investigators in this study are skeptical of the use of Lip prints alone for gender identification. However, there is no doubt, as has also been proven by literature, that lip prints are unique for an individual, and are even as specific as Finger prints. However, we feel Lip prints may at best be used as an adjunct to gender identification in association with other means like Rugoscopy and Radiography.

It had been established by several observation that no two palates are alike in their configuration and once formed, they do not undergo any changes except in length due to normal growth, remaining in the same position throughout a person's entire life. Most of the time, diseases , chemical aggression or trauma do not seem to change the palatal rugae form . however some reports state that though rugae remain fairly stable in number and morphology , the alignment may be altered in case of trauma , loss of tooth , persistent pressure , extreme finger sucking , orthodontic tooth movement .

Palatal rugoscopy was first proposed in 1932, by a Spanish investigator TrobanHermaso. It has been suggested that a classification system that is simple and reliable should be used in rugae studies to enhance reproducibility .Researches had found difficulty in the task of classification of rugae patterns due to the subjective nature of observation and variability in the interpretation within and between observers . Since then, various classifications had been proposed by et al (1996) , Thomas and Kotze (1983) , Trobo(1994 ) , Carrea(1937) , etc. Palatal rugae can resist decomposition changes for up to seven days of death .Thomas and Wyk successfully identified a severely burnt edentulous bodies by comparing the rugae to those on the victim's old denture. In our study, we found the number of palatal rugae to be more in males than females. Further, it was also observed in our study that curved rugae were maximum in both males and females. It was observed that after curved rugae, straight rugae were the most common in males, while wavy pattern was more common in females. This again lent credence to our hypothesis that lip prints and palatal rugae present typical patterns in specific population groups, while it is more difficult to identify the gender on the basis of dental profiling.

The recent years have seen the advent and increase in the use of radiography of the bones for identification of the gender. The tooth-pulp ratio has been widely studied and extensive research is available for the same. However, the same poses a limitation in edentulous patients, or where teeth are otherwise lost / destroyed beyond use. Moreover, root canal treatment, which is quite a common treatment halts the dentin formation (as odontoblasts are lost in the process), and therefore this method has its limitations. The use of radiography in general forensic identifications has significant contributions. Following this pattern, the use of radiography in Head and neck region is also gaining importance. In our study, we attempted to add this parameter to the already extensively investigated cheilioscopy and rugoscopy in order to increase the

accuracy of the findings. In our study, the total ramus width, condylar height, projection height and coronoid height values were more in males than in females. Though all of these findings were not statistically significant, but the variations are sufficient to warrant further studies. In our opinion, the use of radiography of the mandible in conjunction with cheilioscopy and rugoscopy together offer the potential to be a reliable means of identification in dental Profiling. Moreover, all the procedures studied here are easy to perform, with the minimum basic equipment. Further studied and a sound knowledge of these, therefore, will be of immense help in rapid field investigations.

#### CONCLUSION:

To summarize, the authors of this study feel that as Forensic Dentistry is evolving as a full fledged speciality, we as Forensic Odontologists need to start looking beyond the teeth. The para-dental structures provide an enormous amount of information and this information can easily be put to use for the benefit of mankind, provided we are willing to harness this knowledge. Over the years, there has been numerous research on the role of Lip prints and Palatal rugae in Postmortem Dental Profiling. In this study, we have studied the use of Lip prints for gender identification. The results of our study showed that Lip prints, though give an indication to the gender of an individual, cannot be used as conclusive in Dental Profiling (even though the use of Lip prints, when compared with records has been accepted in the court of Law). Most of the lip prints studied by us fell into the Type I (Vertical grooves running across the entire thickness of the lips), or Type I' (Vertical grooves not running across the entire thickness of the lips). The Type I was more prevalent in Females, while Type I' was more prevalent in Males. However, we need to take into consideration several other factors, such as the difference in thickness of lips between males and females before we can consider this as conclusive.

#### REFERENCES:

1. Saraf A ,Bedia S., Indurkar A., Degwekar S., Bhowate R.. Rugae patterns as an adjunct to sex differentiation in forensic identification. J Forensic Odontostomatol 2011; 29:1:14-19.
2. Sharma P, Saxena S, Rathod V. Comparative reliability of cheilioscopy and palatoscopy in human identification. Indian J Dent Res 2009;20(4): 453-457.
3. Krishnappa S, Srinath S, Bhadwaj P, C H Mallya. Palatal rugoscopy: implementation in forensic odontology- a review. J adv med dent scie 2013; 1(2):53-59.
4. Saraswathi TR, Gauri Mishra, Ranganathan K. study of lip prints. Journal of Forensic Dental Sciences 2009; 1 (1):28-31
5. Castello, A., Alvarez, M. &Verdu, F. (2004). Just Lip Prints? No: there could be something else. The FASEB Journal, 615 – 616.
6. Saini V, Srivastava R, Rai RK, Shamal SN, Singh TB, Tripathi SK. Mandibular ramus :An indicator for sex in fragmentary mandible. J Forensic Sci ;56(Suppl 1):S 13-6
7. Scheuer L. Application of osteology to forensic medicine. ClinAnat. 2002; 15:297-312.
8. Humphrey LT, Dean MC, Stringer CB. Morphological Variation in great ape and modern human mandibles. J Anat 1999; 195:491-513.
9. Vodanovic M, Dumancic J, Demo Z, Mihelic D. Determination of sex by discriminant function analysis of mandible from two Croatia archaeological sites. Acta stomatol Croat 2006; 40:263-77
10. Kasprzak J. Possibilities of cheilioscopy. Forensic Sci Int. 1990;46:145–51.
11. Thomas CJ, van Wyk CW. The palatal rugae in an identification. J Forensic Odontostomatol. 1988;6:21–7.
12. Prabhu RV, Dinkar AD, Prabhu VD, Rao PK. Cheilioscopy: Revisited. J Forensic Dent Sci. 2012;4:47–52.
13. Saraswathi TR, Mishra G, Ranganathan K. Study of lip prints. J Forensic Dent Sci. 2009;1:28–31
14. Suzuki, K., Tsuchihashi, Y. Personal Identification by Means of Lip Prints. Journal of Forensic Medicine, 1970; 52 – 57.
15. Tsuchihashi, Y. Studies on Personal Identification by Means of Lip Prints. Forensic Science, 1974; 233 – 248.

**Source of support:** Nil

**Conflict of interest:** None declared

This work is licensed under CC BY: *Creative Commons Attribution 3.0 License*.