

Original Research

Prevalence of Oral Precancerous Lesions in HIV Patients in North West Region of Rajasthan

Shivam Sethi¹, Ajeet Kumar Gadhwal², Kheta Ram³, Kapil Chahar⁴, Jitendra Acharya⁵

^{1,3}Final Year Resident, ^{2,4}Senior Resident, Department of Medicine S.P. Medical College Bikaner, Rajasthan, India;

⁵Senior Demonstrator Department of Dentistry S.P. Medical College Bikaner, Rajasthan, India

ABSTRACT

Introduction: Due to the increase in tobacco habits, oral potentially malignant and malignant lesions incidence increases thus increasing the burden of cancer on our nation. Thus the prevalence studies on oral cancers are significant to reveal the health status of that region and thus need of treatment. Premalignant pathologies include all those lesions which are precursors of oral squamous cell carcinoma/oral cancer. This retrospective study was planned to assess the prevalence of potentially malignant and malignant oral lesions in Bikaner India from 2015 to 2016. **Material and Methods:** Hospital based retrospective study was conducted in Bikaner from 2015 to 2016. Data was manually retrieved year wise with reference to age, sex, site involved and histopathological findings in hiv patients. **Results:** 200 oral biopsies were reviewed. Of these, 130 biopsies were premalignant, 40 were malignant and 30 were others. The buccal mucosa was the most frequently involved site followed by tongue and gingiva in HIV patients. Oral lichen planus constituted the highest number of patients in premalignant group, while in malignant group, squamous cell carcinoma was most prevalent. **Conclusion:** This study revealed that pre-malignant and malignant oral lesions were widespread in the patients visiting the hospital in North West region of Rajasthan.

Key words: Malignant, Premalignant, Histopathological Features, Tobacco, Prevalence.

Received: 6 November, 2019

Revised: 21 December, 2019

Accepted: 23 December, 2019

Corresponding author: Dr. Ajeet Kumar Gadhwal, Senior Resident, Department of Medicine S.P. Medical College Bikaner, Rajasthan, India

This article may be cited as: Sethi S, Gadhwal AK, Ram K, Chahar K, Acharya J. Prevalence of Oral Precancerous Lesions in HIV Patients in North West Region of Rajasthan. J Adv Med Dent Scie Res 2020;8(1):55-57.

INTRODUCTION

Oral cancer in India, which still is a developing nation, is a major health problem in world. Worldwide studies have shown the annual incidence of 3,000,000 oral cancer cases.¹ In India Incidence rates per 100,000 population were 12.8 in men and 7.5 in women.² Rarely it is seen in young people and mostly occurs in the elderly people during the fifth to eighth decade of life.³ Generally predisposing factors for oral carcinoma are alcohol, tobacco use and smokeless tobacco, betel nut chewing and human papilloma virus (HPV). Poor dental care and poor diet may also contribute to Oral cancer.⁴ Oral cancer incidence is highest in India and 90

to 95% of the oral cancers is oral squamous cell carcinoma.⁵ Cases of oral cancer amplified from 1 million in 2012 to 1.7 million in 2035 according to different research agencies on cancer thus indicating that the death rate due to oral cancer will also increase in the same period. Pre malignant lesions and conditions like oral submucous fibrosis, leukoplakia, erythroplakia, and lichen planus are commonly seen in India, and carry an increased risk for malignant transfor-mation.⁶

The scale of oral cancer varies from place to place within the country.⁷ In Bikaner patients are referred from many primary health centers and district hospitals.

MATERIAL AND METHODS

Hospital based retrospective study from 2015 to 2016 was planned in already diagnosed HIV patients and data was collected year-wise in the perspective of age, sex, site involved, and final histopathological diagnosis. All cases which were previously histopathologically diagnosed between 2015 to 2016 in the department as premalignant and malignant lesions were taken. There were no inclusion or exclusion criteria. All cases were considered and then reviewed.

RESULTS

Out of which 130(43.3%) patients were reported to be pre-malignant, 40(13.3%) were malignant, and 30 (10%) were others (Figure-1). Of the total cases, 130 were males and 70 were females (Figure-2). Of the malignant cases, 25 were males and 15 were females. Of

the pre malignant cases, 80 were males and 50 were females. In the group of 40 patients with malignancy, 22(55%) had well-differentiated squamous cell carcinoma, 9(22.5%) had moderately-differentiated carcinoma, 5(12.5%) had poorly-differentiated carcinoma, 2(5%) had verrucous carcinoma, 1(2.5%) had basaloid squamous cell carcinoma and 1(2.5%) had ameloblastic carcinoma (P.I.O.C) (Figure-3). In the potentially malignant group, 60 were reported as lichen planus (46.1%), 42 were reported as OSMF (32.3%), 18 were reported as leukoplakia (13.8%), and 10(7.6%) cases were erythroplakia (Figure-4).

In age-wise distribution majority of the patients were reported in the age group of 25-48 years. Oral Buccal mucosa was most frequently involved based on site involvement, followed by the tongue 90 and gingiva.

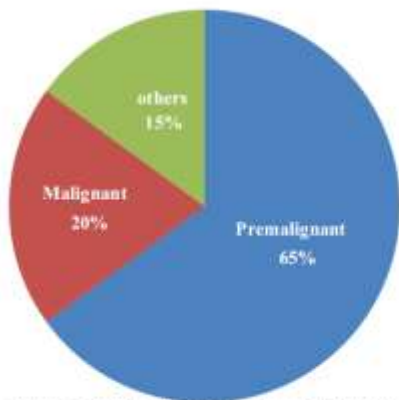


Figure-1: showing prevalence of premalignant and malignant lesions

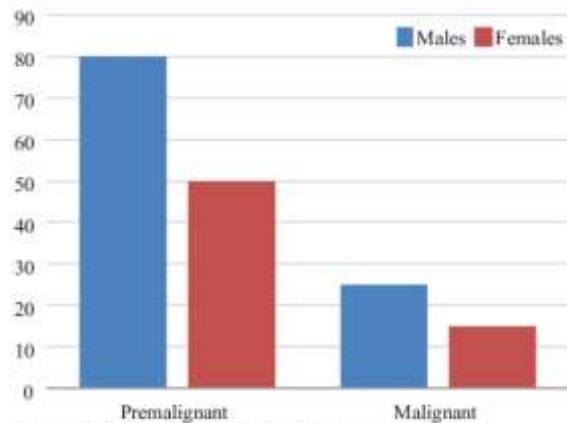


Figure-2: showing frequency distribution of as per gender

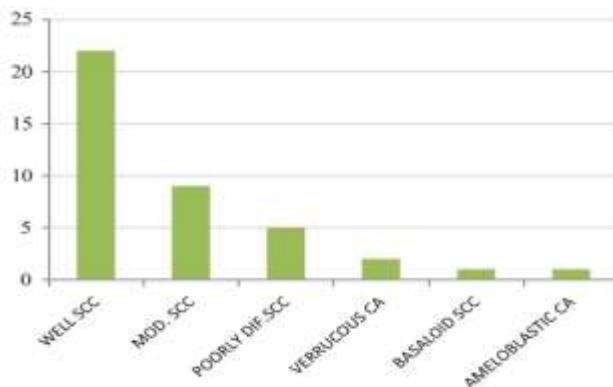


Figure-3: showing frequency distribution of malignant lesions

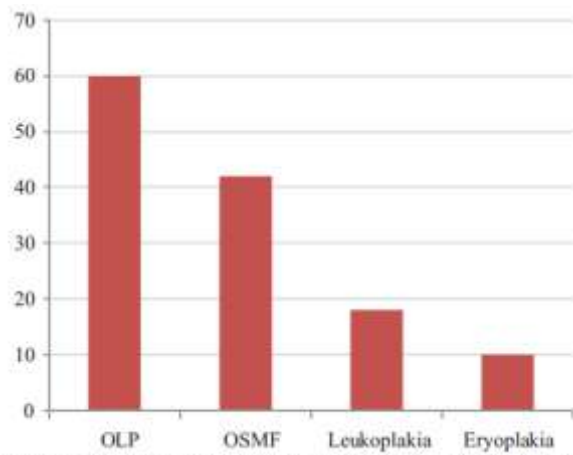


Figure-4: showing frequency distribution of premalignant lesions

DISCUSSION

Prevalence studies in oral pathology can be done on visiting outpatients or examining on whole population, however examining outpatients is easier to perform than whole population examination due to its method but it gives information about the whole population.⁸

Malignant neoplasm incidence varies from one region to another, because of different factors and the potential predisposing etiologies.⁹ the mortality rate has remained largely unchanged for decades despite advances in surgery and radiotherapy, which remain the standard treatment options, with a 5-year survival rate of around 50%. In OSCC surgery along with radiotherapy is the treatment of choice in primary stages however in the later stages combination therapy such as surgery, radiotherapy or chemotherapy has responded well.¹⁰

In our study 40 (13.3%) were malignant lesions while as in other research studies 23.3% of were histopathologically diagnosed as oral cancers (OSCC).¹¹ while as in other studies done in Thiruvananthapuram have shown that OSCC constituted 14% of all cancers.¹² Most frequently encountered white lesions in clinics are leukoplakia which is generally seen at ages between 5th and 7th decade with a male predominance.

The prevalence of oral leukoplakia done by Dambi et al in 2001¹³ varies from 1% to 13% and mostly effecting buccal mucosa, floor of the mouth, tongue and soft palate.¹⁴ However In our study 13.8% prevalence was seen. 7.6% was prevalence of erythroplakia. In our study which is seen less frequently than leukoplakia but it is more life threatening. In other studies the prevalence was quite high.

Oral lichen planus, which is located bilaterally and its cause not fully understood. Axell and Rundquist found a prevalence of 1.9% among Swedish people and Axell et al., 1990 reported rates of 3.8% and 2.1% in Thai and Malaysian outpatients respectively. In our study, 46.1% prevalence rate was observed. Oral submucous fibrosis which is commonly seen in India with betel nut as a main culprit 32% cases were observed in our study.

Oral cavity could be used in early detection of precancerous and cancerous lesions as it is more accessible to complete examination, but usually it gets detected in later stages. Use of recent advances in oral screening and detection aids such as Vizylite and VELscope help in detection in early stage, or even in the pre-malignant stage.

CONCLUSION

In terms of prevalence, frequency and presentation awareness of the precancerous and malignant lesions of oral cavity in already diagnosed HIV patients is beneficial for them to making early and better diagnosis and treatment. Based on knowledge early detection of pre malignant and malignant lesions

minimize potential complications and enhances life expectancy of the patient.

REFERENCES

1. Ken Russell Coelho. Challenges of the Oral Cancer Burden in India. *Journal of Cancer Epidemiology*. 2012;2012:1-17.
2. G Kiran et al. Demographics And Histopathological Patterns Of Oral Squamous Cell Carcinoma At A tertiary Level Referral Hospital In Hyderabad, India: A 5 Year Retrospective Study. *Journal Of Orofacial Research*. 2012;2:198-201.
3. Iype E M, Pandey M, Mathew A, Thomas G, Sebastian P, Nair M K. Oral Cancer Among Patients Under The Age Of 35 Years. *J Post Grad Med*. 2001;5:171.
4. Varshitha. A. Prevalence of Oral Cancer In India. *J. Pharm. Sci. and Res*. 2015;7: 845-848.
5. Liviu Feller, Johan Lemmer. Oral Squamous Cell Carcinoma: Epidemiology, Clinical Presentation and Treatment. *Journal of Cancer Therapy*. 2012;3:263-268.
6. Pankaj Chaturvedi, Deepa R Nair, Uday Pawar, Ritesh Pruthy. Oral cancer: Premalignant conditions and screening - an update. *Journal of Cancer Research and Therapeutics*. 2012;8:57-66.
7. Ajit Mishra et al. Prevalence of Oral Cancer in Chhattisgarh- An Epidemiological study. *Chhattisgarh Journal of Health Sciences*. 2013;1:1-4.
8. Suhail latoo, Pushparaja Shetty, Owais Gowhar. Prevalence Of Oral Precancerous Lesions Among Population Of Sasihitlu Village, Mukka, Dakshin Kannada District, Karnataka, India. *International Journal of Current Research*. 2016;08:26421-26423.
9. Raefa Anis, Kamis Gaballah. Oral cancer in the UAE: a multicenter, retrospective study. *Libyan J Med*. 2013;8:1-6.
10. Anastasios K. Markopoulos. Current Aspects on Oral Squamous Cell Carcinoma. *The Open Dentistry Journal*. 2012;6:126-130.
11. Shyam, et al. Prevalence of oral potentially malignant and malignant lesions at a tertiary level hospital in Hyderabad, India. *Journal of Dr. NTR University of Health Sciences*. 2014;3:S13-16.
12. Padmakumary G, Varghese C. Annual Report. 1997. Hospital Cancer Registry. Thiruvananthapuram, India: Regional Cancer Centre. 2000;3-7.
13. Dambi, C., Voros-Bolog, T., Czegledy, A., Hermann, P., Vincze, N., Banoczy, J. Risk group assessment of oral precancer attached to X-ray lung-screening examinations. *Community Dent Oral Epidemiol*. 2001;29:9-13.
14. Van der Wall, I., Schepman, K. P., van der Meij, E. H., Smeele, L. E. Oral leukoplakia: a clinicopathological review. *Oral Oncol*. 1997;33:291-01.