

## Journal of Advanced Medical and Dental Sciences Research

@Society of Scientific Research and Studies

Journal home page: [www.jamdsr.com](http://www.jamdsr.com)

doi: 10.21276/jamdsr

(e) ISSN Online: 2321-9599; (p) ISSN Print: 2348-6805

# CASE REPORT

## Non Surgical Management of Periapical Lesion Using Calcium Hydroxide: A Two Year Follow Up

Vinisha Pandey<sup>1</sup>, Vipin Kumar<sup>2</sup>, Reshu Singh<sup>3</sup>, Subhra Dey<sup>4</sup>, Harshit Singhania<sup>5</sup>, Vriti Kohli<sup>6</sup>

<sup>1</sup>Associate Professor, Department of Conservative Dentistry and Endodontics, Institute of Dental Studies & Technologies (IDST), Modinagar, Uttar Pradesh, India

<sup>2</sup>Periodontist and Implantologist, Graded specialist, Army Dental Corps

<sup>3</sup>Associate Professor, Department of Prosthodontics, Rama Dental College, Kanpur, U.P., India

<sup>4</sup>Associate Professor, Department of Conservative Dentistry and Endodontics, Index Institute of Dental Sciences, Indore, M.P., India

<sup>5</sup>B.D.S., Dental Surgeon, Rama Dental College, U.P., India

<sup>6</sup>BDS Student, Rama Dental College, Kanpur, U.P., India

### ABSTRACT:

Periapical lesions usually develop in non vital teeth as a result of a chronic aggression by the presence of pathogenic microorganisms into the root canal which may appear as radiolucent lesions in radiographs. Treatment of such lesions varies from non surgical to surgical means depending upon individual case. In the era of minimally invasive dentistry, non surgical endodontic approach has been highly recommended to promote periapical healing. Calcium hydroxide plays a pivotal role in such procedures since it has very effective anti-bacterial properties and special ability of tissue repair by hard tissue formation. The case report series below describes the regression of periapical lesions using nonsurgical endodontic treatment along with calcium hydroxide based medicament.

**Key words:** Calcium hydroxide, periapical healing, endodontic therapy, non-surgical, canal disinfection.

Received: 3 January 2018

Revised: 16 May 2018

Accepted: 25 May 2018

**Corresponding author:** Dr. Vinisha Pandey, Associate Professor, Department of Conservative Dentistry and Endodontics, Institute of Dental Studies & Technologies (IDST), Modinagar, Uttar Pradesh, India

**This article may be cited as:** Pandey V, Kumar V, Singh R, Dey S, Singhania H, Kohli V. Non Surgical Management of Periapical Lesion Using Calcium Hydroxide: A Two Year Follow Up. J Adv Med Dent Sci Res 2018;6(8):44-48.

### INTRODUCTION:

Microbial invasion of the pulpal tissues occurs either through dental caries, trauma or any developmental tooth anatomy causing pulpal infection and subsequent pulpal necrosis. The necrotic root canal system provides a very favourable environment for the growth of microorganisms inside the root canal system. Thus, it is responsible for formation of numerous microbial stains and their by-products along with tissue breakdown products which usually leach out into the surrounding periradicular tissue region.<sup>1</sup> Since, a very close physio-pathological relationship exists between the pulp and periradicular area, these generally trigger an inflammatory process in the periapical tissues progressively affecting them through the process of resorption and subsequent immunopathological mechanisms lead to the formation of periapical lesions in the form of periapical granulomas, abscesses or periapical

cysts. Such periapical lesions are generally diagnosed either during routine dental radiographic examination or during an episode of acute pain elicited by the patient.<sup>2,3</sup> Most periapical lesions can be classified as periapical granuloma, abscess or cyst. Incidence of periapical granuloma ranges between 9.3 and 87.1%, abscess between 28.7 to 70.7% and periapical cyst varies between 6 to 55%.<sup>4</sup>

Thus, all inflammatory periapical lesions should always be initially treated by conservative non-surgical technique. Surgical intervention is recommended only when nonsurgical techniques have failed. Moreover, surgical techniques have major drawbacks which limit its use in the routine management of periapical lesions. Various studies have reconfirmed that non-surgical treatment with adequate infection control can help to create favourable environment in the healing of large periapical lesions upto 85%.<sup>5,6</sup>

The ultimate goal of endodontic therapy is to eliminate or significantly reduce the pathogenic microorganisms inside the root canal system and to enable the teeth to return to its healthy state of function without any surgical intervention. Chemo-mechanical preparation techniques alone can't adequately clean the root canal system of microorganisms. Microorganisms tend to proliferate at the intra-appointment time. Hence, a suitable intracanal medicament like calcium hydroxide has to be delivered in the intra-canal space to prevent inter-appointment flare-ups. Calcium hydroxide has been extensively used as an intra-canal medicament in the field of endodontics for many years because of its good antibacterial properties and its ability to encourage osseous repair and promote healing.<sup>7,8</sup>

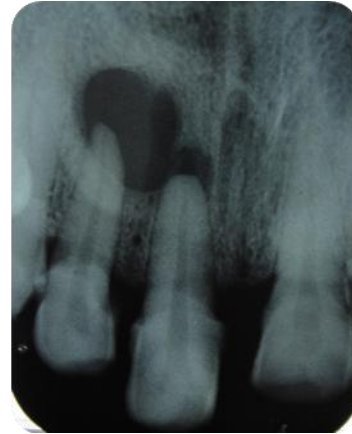
This article presents case of treatment of large periapical lesion using calcium hydroxide as an intra-canal medicament.

A 57 year old female patient with a non contributory medical history reported to the department of Conservative dentistry and endodontics with pus drainage from the upper front tooth region. On taking case history, patient reported that she had a traumatic injury due to bicycle accident 8 years back. She had never visited any dentist before since she was asymptomatic earlier. On clinical examination, there was slight extrusion of the tooth 11 and 12 was found discoloured. Sinus formation was evident with respect to 11. Both the teeth were sensitive to percussion and palpation but there was no mobility. Diagnostic radiographs were taken which demonstrated well defined and circumscribed large radiolucent lesion around the apices of the maxillary incisors.

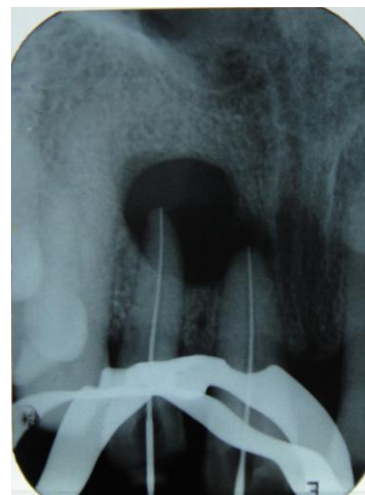
Keeping in mind the age of the patient and the intra oral conditions a non surgical management was planned and an informed consent was obtained.

Non surgical endodontic treatment was initiated. Access cavity preparation was done under local anaesthesia and rubber dam isolation. Following the access cavity preparation, copious mucopurulent exudate was drained through the root canal space by using number 15 size k file to trephine beyond the apical foramen. Then, when the drainage ceased the working length were determined using k files keeping 1 mm short of the radiographic apex. The canals were then prepared using 15-40 k files and copious irrigation was done using 3% sodium hypochlorite, metrogyl solution and saline. The canals were dried using sterile paper points. Preformed radiopaque calcium hydroxide paste (Metapex) was introduced as a medicament into the periapical region and was also filled into the root canal space. The access cavity was then sealed using intermediate restorative cement. Metapex dressing was changed after 1 month. The patient reported asymptomatic after 4 months and an IOPA was taken to confirm the healing process. Intra oral periapical radiograph revealed gradual decrease in size of the periapical lesion. Later, when the canals were found dry without any exudates they were obturated using gutta percha and calcium hydroxide based sealer Sealapex (Kerr, Italy) by lateral condensation technique. A

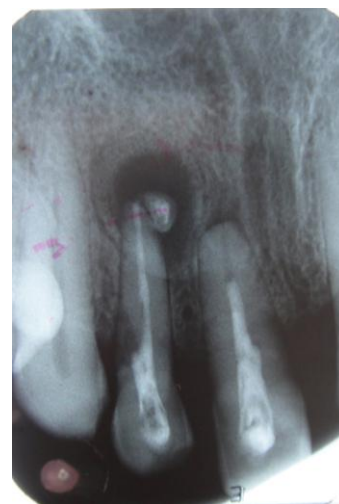
permanent restoration was later placed after a week. The patient was then scheduled for clinical and radiographic follow up checkups after every 6 months for upto a period of 2 years. Intra Oral Periapical radiograph was taken each time which demonstrated excellent periapical healing over the period of time.



**Preoperative Intra Oral Periapical Radiograph Showing Well Defined Circumscribed Radiolucent Lesion**

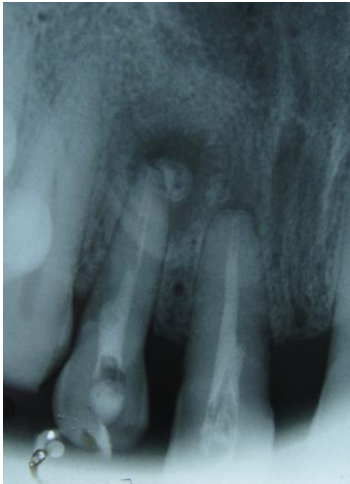

**Working Length Established**

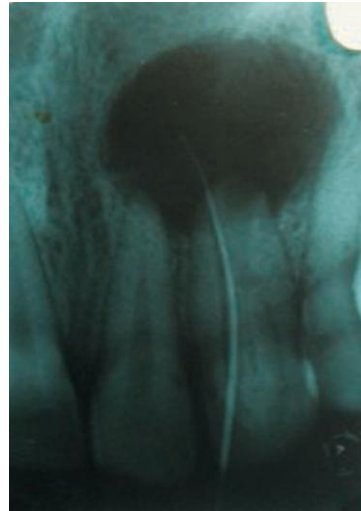


**Placement of Calcium Hydroxide (METAPEX) The lesion has already started healing**

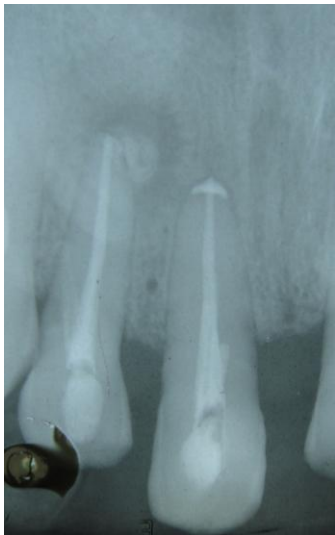**CASE 2**



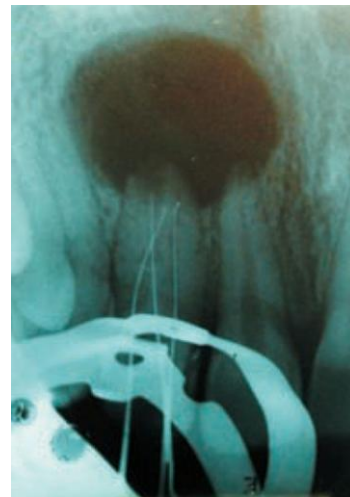
**Follow up at 06 months**



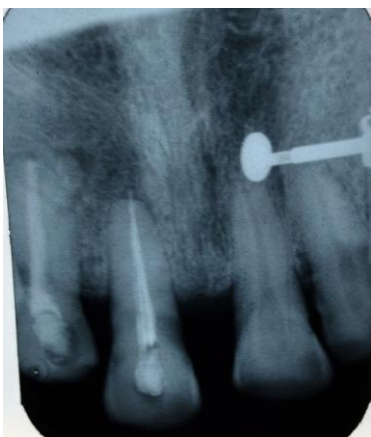**Pre-operative radiograph with gutta-percha tracing**



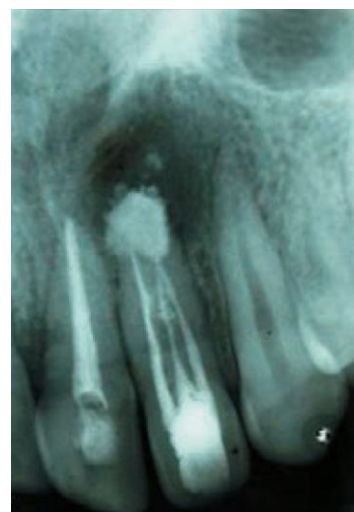**Follow up after 12 months**



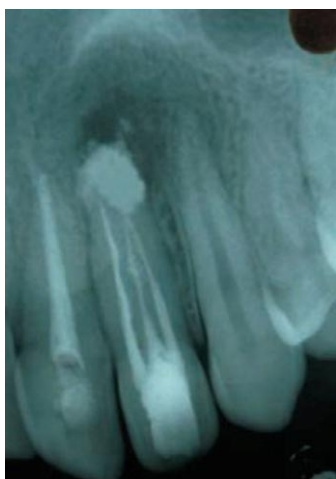**Working length radiograph**



**Follow up after 2 years**



**Radiograph taken at 3 months follow-up**



**Radiograph taken at 6 months follow-up**

**DISCUSSION:**

The main aim of endodontic treatment is the complete elimination of microbial flora from the root canal system and promotes periapical healing. Periapical tissues have a rich blood supply, lymphatic drainage and number of undifferentiated mesenchymal cells which promote good healing potential through treatment procedures aiming at removal of the etiologic factors. Microbial flora plays a very important role in the development of apical periodontitis and subsequent periapical lesions. Necrotic pulp provides a very good nutritional environment for the development of pathogenic bacteria which in turn multiplies and release various toxins into the periapical area, thereby initiating an inflammatory reaction and development of periapical lesion. Immuno-pathologic mechanisms also play a key role in the initiation of periapical lesions.<sup>9,10</sup>

During endodontic treatment, complete elimination of bacteria by instrumentation alone is impossible. Hence, proper irrigation and intra-canal medication protocol should be followed for the complete three dimensional cleaning and disinfection of the root canal environment. Bhaskar<sup>11</sup> suggested that instrumentation if exceeded 1mm beyond the apex resulted in inflammatory reaction which destroys the cystic lining and converts the cyst into granuloma. Further, if the causative factors are removed, granuloma heals by itself. By this procedure, drainage is established and degeneration of epithelial cells occurs through strangulation by proliferation of fibroblasts and collagen. Contrarily, this can cause increased epithelial proliferation and cystic expansion hampering healing process<sup>12</sup>. Hence, in this case instrumentation was done 0.5-1 mm short of the apex to avoid additional trauma. So, for reducing the microbial load, meticulous debridement using irrigant such as sodium hypochlorite as an irrigant and calcium hydroxide as an intra-canal medicament is essential. Calcium hydroxide was first introduced by Hermann in 1920. The antimicrobial activity of calcium hydroxide is due to its dissociation into calcium and hydroxyl ions in a high pH environment which inhibits enzymatic activities such as metabolism, growth and cellular division which are essential for microbial growth. It damages the bacterial cytoplasmic

membranes, causes denaturation of proteins and damage to bacterial DNA. It is also extended into the periapical cystic lesions to promote healing. It exhibits anti-inflammatory action, anticlastic property by inhibition of phospholipase, activation of alkaline phosphatase and destruction of cystic epithelium and thus allowing connective tissue to invaginate into the lesion<sup>13</sup>. Numerous studies have proved that nonsurgical conservative management of extensive periapical lesions using calcium hydroxide as an intra-canal medicament is successful. Periapical surgery is less recommended since it being an invasive procedure involves risk of damaging the bone support and underlying important anatomic structures which might cause more post-operative pain and discomfort. Patients who are more psychologically anxious about a surgical procedure require primarily a nonsurgical approach first. In case it doesn't heal, then later surgical intervention may be required.<sup>14</sup> Calcium hydroxide has a direct effect on the inflamed tissues and epithelial cystic linings to favour periapical healing and osseous repair. Their action is due to the leaching of calcium and hydroxyl ions to the surrounding inflamed tissues in the presence of high pH characterized by initial degenerative response immediately below in the vicinity followed by rapid mineralization and ossification process. The alkalinity of calcium hydroxide also neutralizes the lactic acid from osteoclasts and prevents dissolution of the mineralized portions of the teeth. It is also known to activate alkaline phosphatase and calcium dependent adenosine triphosphatase reaction to stimulate hard tissue formation. It denatures the toxic proteins found in the infected root canal system. The antibacterial components of the calcium hydroxide based root canal sealer also prevents regrowth of residual bacteria and reduce bacterial re-entry into the root canal after endodontic treatment.<sup>8, 15,16</sup>

The vehicle used as a carrier for calcium hydroxide medicament plays a very important role. The velocity of ionic dissociation, which causes solubilisation of paste and resorption at various rates by the periapical tissues and from the root canal system is determined by the type of vehicle used. Generally, three types of vehicles are used: aqueous, viscous or oily. Higher the viscosity of the vehicle, slower is the dissociation process. Oily vehicle being the most viscous has the least solubility among the other vehicles used which promotes diffusion of the paste within the tissues. Hence, paste remains within the root canal for a longer period of time. It is changed less frequently in between the appointments and fresh paste is introduced if required. The calcium hydroxide paste used in the case reports was metapex which contains Ca (OH)<sub>2</sub>, silicone oil and iodoform.<sup>17,18</sup> Sometimes, giving intra-canal medicament alone is insufficient to control the infection. So, the teeth are obturated with a calcium hydroxide based root canal sealer. It is now believed that the activated macrophages in the periapical lesions are primarily responsible for the delayed healing of such lesions in the absence of bacterial antigens. Thus, a futuristic approach would be the placement of biodegradable local sustained drug delivery points into

the lesion area to deactivate the macrophages and enhance the healing rate. This can be achieved by the placement of calcium hydroxide sealer during obturation of the teeth with lesions. It has also been proved that the active draining sinus tracts can be healed by conservative endodontic treatment alone. Calcium hydroxide has shown to neutralise the acidic exudates due to its strong alkaline pH. Clinical signs and symptoms and radiographic signs such as change of density within the lesion, trabecular reformation and lamina dura reformation should be checked during follow-up visits through radiographs especially in asymptomatic teeth and healthy soft tissues.<sup>19,20</sup>

#### CONCLUSION:

In this case report, complete periapical healing was observed through thorough cleaning and prolonged disinfecting procedures using calcium hydroxide as an intra-canal medicament and root canal sealer during obturation. Thus, it eliminated the need for the use of invasive periapical surgery. Hence, the role of conservative endodontic treatment is justified.

#### REFERENCES

1. Moller AJ, Fabricius L, Dahlen G, Ohman AE, Heyden G. Influence on periapical tissues of indigenous oral bacteria and necrotic pulp tissue in monkeys. *Scand J Dent Res* 1981;89:475-84.
2. Barbakow FH, Cleaton-Jones PE, Friedman D. Endodontic treatment of teeth with periapical radiolucent areas in a general dental practice. *Oral Surg* 1981;51:552-59.
3. Wood NK. Periapical lesions. *Dent Clin North Am* 1984;28:725-66.
4. Lalonde ER, Leubke RG. The frequency and distribution of periapical cysts and granulomas. *Oral Surg Oral Med Oral Pathol* 1986;25:861-68.
5. Sjogren U, Hagglund B, Sundqvist G, Wing K. Factors affecting the long-term results of endodontic treatment. *J Endod* 1990;16:31-37.
6. Shah N. Nonsurgical management of periapical lesions: A prospective study. *Oral Surg Oral Med Oral Pathol* 1988;66:365-71.
7. Caliskan MK, Sen BH. Endodontic treatment of teeth with apical periodontitis using calcium hydroxide: A long term study. *Endod Dent Traumatol* 1996;12:215-21.
8. Desai S and Chandler N. Calcium hydroxide based root canal sealers: a review. *J Endod* 2009;35(4):475-80.
9. Torabinejad M, Bakland LK. Immunopathogenesis of chronic periapical lesions. *Oral Surg* 1978;46:685-8.
10. Ninomiya J, Nakanishi K, Takemoto T et al. Cellular immune-competence of infected root canal contents in pathogenesis of periapical lesions. *J Endod* 1997;23:213-16.
11. Bhaskar SN. Periapical lesions-types, incidence and clinical features. *Oral Surg Oral Med Oral Pathol* 1996;21:657-71.
12. Seltzer S. Endodontology-biologic considerations in endodontic procedures. 2<sup>nd</sup> ed. Philadelphia, PA: Lea and Febiger 1998.
13. J.F. Sequeira Jr and H.P. Lopes. Mechanisms of antimicrobial activity of calcium hydroxide: a critical review. *Int Endod J* 1999;32(5):361-69.
14. Oztan MD. Endodontic treatment of teeth associated with a large periapical lesion. *Int Endod J* 2002;35:73-78.
15. Fava LRG, Saunders WP. Calcium hydroxide pastes: classification and clinical indications-A review. *Int Endod J* 1999;32:257-82.
16. Farhad A, Mohammadi Z. Calcium hydroxide: a review. *Int Dent J* 2005;55:293-301.
17. I.C Gomes Camoes, MR Salles and Chevitaese O. Ca<sup>2+</sup> diffusion through dentin of Ca (OH)<sub>2</sub> associated with seven different vehicles. *J Endod* 2003;29(12):822-25.
18. Mohammadi Z and P.M.H Dummer. Properties and applications of calcium hydroxide in endodontics and dental traumatology. *Int Endod J* 2011;44(8):697-730.
19. Huuonen S, Orstavik D. Radiological aspects of apical periodontitis. *Endod Topics* 2002;1:3-25.
20. Leonardo MR, Silveria FF, Silva LA, Tanomaru Filho M, Utrilla LS. Calcium hydroxide root canal dressing. Histopathological evaluation of periapical repair at different time periods. *Braz Dent J* 2002;13:17-22.

Source of support: Nil

Conflict of interest: None declared

This work is licensed under CC BY: *Creative Commons Attribution 3.0 License*.