

# Journal of Advanced Medical and Dental Sciences Research

@Society of Scientific Research and Studies

Journal home page: [www.jamdsr.com](http://www.jamdsr.com)

doi: 10.21276/jamdsr

(e) ISSN Online: 2321-9599; (p) ISSN Print: 2348-6805

SJIF (Impact factor) 2017= 6.261;

Index Copernicus value 2016 = 76.77

## Original Article

### Assessment of the Treatment Outcomes in cases with Bile Leakage following Cholecystectomy

R B Singh<sup>1</sup>, Pankaj Kumar Mishra<sup>2</sup>

<sup>1</sup>Medical Superintendent and Assistant Professor, Surgery, <sup>2</sup>Professor, Community medicine, Mayo Institute of Medical Sciences, Barabanki, U.P., India

#### ABSTRACT:

**Background:** The most desirable treatment of choice of treatment of bile leakage following cholecystectomy is Endoscopic retrograde cholangio pancreatography (ERCP) with placement of a biliary stent or drain. **Aim of the study:** To study the treatment outcomes in cases with bile leakage following cholecystectomy. **Materials and methods:** The study was conducted in the department of general surgery of the medical institute. We included 45 patients admitting to the Department of General Surgery with biliary leakage after cholecystectomy or developed biliary leakage after cholecystectomy from January 2017 to June 2017. Patients between the ages of 14 years to 60 years were included in the study. We collected data such as clinical presentations following biliary leak, timing of detection of bile leak post operatively (< 24 hour or > 24 hour), acute or chronic cholecystitis at the time of operation, amount of bile leak, duration of bile leak, postoperative investigation (MRCP, CT abdomen, USG) for bile leak, various modalities of management and its outcome, site of bile leak. **Results:** In the present study a total of 45 cases were included in the study. The age of the patients ranged between 14 to 60 years with mean age at 42.21 years. No. of male patients was 29 and no. of female patients was 16. No. of cases which underwent open cholecystectomy was 29 and no. of cases which underwent laparoscopic cholecystectomy was 16. The major bile duct injury was seen in 7 patients who underwent open cholecystectomy and 6 patients who underwent laparoscopic cholecystectomy. We observed that conservative treatment with controlled external fistula was performed on 35 patients. Operative treatment was performed on 10 patients. **Conclusion:** The injury to bile duct during cholecystectomy procedure can be very deliberating to the patients and proper steps should be taken for early diagnosis and treatment to avoid such deliberating condition. In our study, conservative treatment was significantly efficacious.

**Key words:** Bile leakage, laparoscopic cholecystectomy, open cholecystectomy.

**Corresponding author:** Dr. Pankaj Kumar Mishra, Professor, Community medicine, Mayo Institute of Medical Sciences, Barabanki, U.P., India

**This article may be cited as:** Singh RB, Mishra PK. Assessment of the Treatment Outcomes in cases with Bile Leakage following Cholecystectomy. J Adv Med Dent Scie Res 2018;6(3):41-44.

#### INTRODUCTION:

Bile leakage can be defined as persistent leakage of bile from the biliary tree. Bile leakage following laparoscopic cholecystectomy is not a common finding but still its occurrence is reported to be 0.3-2.7%. The most common etiology for bile leakage is injury to common bile duct. Bile leak can result in a biliary fistula, a subhepatic/ subphrenic collection or generalized peritonitis. If not diagnosed and treated earlier, these conditions can lead to significant morbidity and mortality in some cases. The most desirable treatment of choice of treatment of bile leakage following cholecystectomy is Endoscopic retrograde cholangio pancreatography (ERCP) with placement of a biliary stent or drain. Hence, the present study was conducted to study

the treatment outcomes in cases with bile leakage following cholecystectomy.

#### MATERIALS AND METHODS:

The study was conducted in the department of general surgery of the medical institute. The ethical clearance for the study was obtained from the ethical board of the institute prior to commencement of the study. We included 45 patients admitting to the Department of General Surgery with the diagnosis of biliary leakage after undergoing cholecystectomy. Patients between the ages of 14 years to 60 years were included in the study. The patients having other systemic diseases such as leukemia, diabetes mellitus were excluded from the study. We collected data such as clinical presentations following biliary leak, timing of

detection of bile leak post operatively (< 24 hour or > 24 hour), acute or chronic cholecystitis at the time of operation, amount of bile leak, duration of bile leak, postoperative investigation (MRCP, CT abdomen, USG) for bile leak, various modalities of management and its outcome, site of bile leak. The data was tabulated and evaluated statistically. The statistical analysis of the data was done using SPSS version 20.0 for windows. The Student's t-test and Chi-square test were used to check the significance of the data. The p-value less than 0.05 was predetermined as statistically significant.

**RESULTS:**

In the present study a total of 45 cases were included in the study. The age of the patients ranged between 14 to 60 years with mean age at 42.21 years. No. of male patients was 29 and no. of female patients was 16. **Table 1** shows the incidence of major bile duct injury after cholecystectomy. No. of cases which underwent open cholecystectomy was 29 and no. of cases which underwent laparoscopic cholecystectomy was 16.

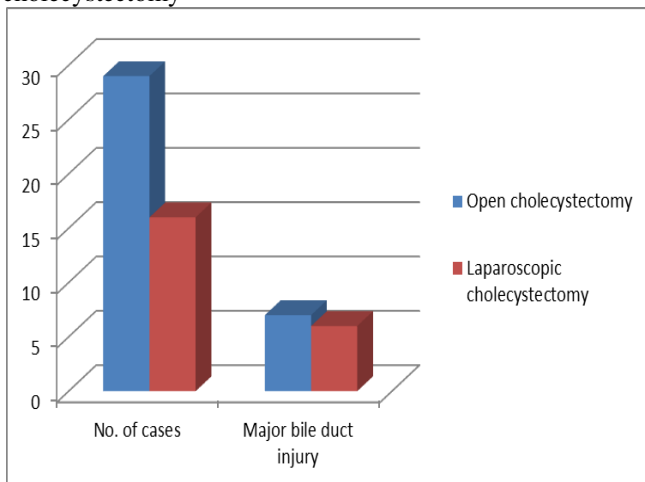
**Table 1:** Incidence of major bile duct injury after cholecystectomy

Type of cholecystectomy	No. of cases	Major bile duct injury
Open cholecystectomy	29	7
Laparoscopic cholecystectomy	16	6

**Table 2:** No. of cases with mode of treatment followed for management of biliary leak

Management of biliary leak	No. of cases	p-value
Conservative treatment with controlled external fistula		0.02
Operative treatment <ul style="list-style-type: none"> <li>• Suturing of cystic duct</li> <li>• Primary suturing</li> <li>• Hepaticojejunostomy</li> </ul>		

**Figure 1:** Incidence of major bile duct injury after cholecystectomy



The major bile duct injury was seen in 7 patients who underwent open cholecystectomy and 6 patients who underwent laparoscopic cholecystectomy [Fig 1]. **Table 2** shows the no. of cases with mode of treatment followed for management of biliary leak. We observed that conservative treatment with controlled external fistula was performed on 35 patients. Operative treatment was performed on 10 patients. Suturing of cystic duct was performed on 2 patients, primary suturing was performed on 2 patients and hepaticojejunostomy was performed on 6 patients. The results on comparing were found to be statistically significant with p-value less than 0.05.

**DISCUSSION:**

In the present time the most common surgical procedure performed is cholecystectomy. It is a very safe procedure but there is occurrence of biliary leakage following cholecystectomy in few cases. The bile leak can result in bilomas, bile ascites, biliary peritonitis, and even death. Proper management in short span of time is very necessary to save the patients. In the present study we observed that majority of patients underwent conservative treatment for bile leakage following cholecystectomy with 100% success rate. Operative management was performed on 10 patients. The success rate of operative procedure was also good at 88%. The results were compared with other studies from the literature which revealed consistent results. Buanes T et al conducted a study from April 1993 to July 1995. Altogether 3860 procedures were enrolled in the Norwegian National Cholecystectomy Registry (NNCR), 777 (20.2%) being open operations. 3083 (79.8%) were initiated laparoscopically, 313 (10.2%) of these converted to open technique. Mortality within 30 days after open cholecystectomy was 1.9%, after a converted procedure 1.0% and 0.14% after laparoscopic cholecystectomy. This gives seven deaths after 3083 procedures, i.e. 0.23%. Postoperative death still occurs approximately 10 times more frequently after open cholecystectomy. However, this is partly due to selection of high risk cases to open technique. Postoperative bile leak was observed in 25 patients in the laparoscopic, 13 (4.2%) in the converted and 19 (2.4%) in the open group. Bile leak contributed significantly to serious complications. 37 major problems were observed in 25 of the patients. Five patients died (8.8%). Among the 57 bile leak patients, common bile duct (CBD) injury was found in 13 (22.8%). Additional 19 CBD injuries occurred, presenting with other symptoms such as icterus, or being recognized during the first operation. The frequency of CBD injury in the laparoscopic group was 14 (0.5%), in the converted group 12 (3.8%) and in the open group 6 (0.8%). None of the patients with CBD injury underwent intraoperative cholangiography. The results showed that open cholecystectomy cannot be considered a safe procedure for high risk patients; secondly, that postoperative bile leak contributes significantly to postoperative mortality and hence is a serious condition

generating from CBD injury in about 1/5 of all cases. Sultan AM et al undertook study to describe the management of post-cholecystectomy biliary fistula according to the type of cholecystectomy. A retrospective analysis of 111 patients was undertaken. They were divided into open cholecystectomy (OC) and laparoscopic cholecystectomy (LC) groups. Of the 111 patients, 38 (34.2%) underwent LC and 73 (65.8%) underwent OC. Endoscopic retrograde cholangiopancreatography (ERCP) diagnosed major bile duct injury (BDI) in 27 patients (38.6%) in the OC group and in 3 patients (7.9%) in the LC group. Endoscopic management was not feasible in 15 patients (13.5%) because of failed cannulation (n=3) or complete ligation of the common bile duct (n=12). Endoscopic therapy stopped leakage in 35 patients (92.1%) and 58 patients (82.9%) following LC and OC, respectively, after the exclusion of 3 patients in whom cannulation failed. Major BDI was more commonly detected after OC. Leakage was controlled endoscopically in 77 patients (98.7%) with minor BDI and in 16 patients (53.3%) with major BDI. It was concluded that major BDI is more common in patients presenting with bile leakage after OC. ERCP is the first-choice treatment for minor BDI.<sup>11,12</sup>

Shawhan RR et al determined the incidence of BL after selective intraoperative cholangiogram (IOC) at a teaching hospital and identify risk factors for predicting BLs. A retrospective review was performed analyzing all cholecystectomy with IOCs between September 2004 and September 2011. Residents performed under staff supervision. Of 1,799 cholecystectomies performed during the study period, only 96 (5.3%) were with IOCs (mean age 43, 65% female) and 4 BLs occurred (4.2%, 1 major duct injury, 3 cystic duct stump leaks). Univariate analysis demonstrated that male gender, significant medical comorbidities, case duration, preoperative endoscopic retrograde cholangiopancreatography, and surgery type (laparoscopic versus open) increased the patient's risk of BL; however, age, performance of secondary procedures, common bile duct exploration, resident level (PGY), and diagnosis did not increase BL risk. Multivariate regression revealed that only surgery type lead to an increased risk of BL. Patient factors and PGY level did not significantly affect BL rates, although open and converted procedures were associated with higher rates, suggesting an increased risk of a BL with more complex cases. Kim KH et al evaluated the efficacy of the endoscopic management of bile leakage after cholecystectomy. A total of 32 patients who underwent endoscopic retrograde cholangiopancreatography (ERCP), because of bile leakage after cholecystectomy, from January 2000 to December 2012 were reviewed retrospectively. The clinical parameters, types of management, and procedure-related complications were documented. Most bile leakages presented as percutaneous bile drainage through a Hemovac (68.8%), followed by abdominal pain (18.8%). The sites of bile leaks were the cystic duct stump in 25 patients,

intrahepatic ducts in four, liver beds in two, and the common bile duct in one. Biliary stenting with or without sphincterotomy was performed in 22 and eight patients, respectively. Of the four cases of bile leak combined with bile duct stricture, one patient had severe bile duct obstruction and the others had mild stricture. Concerning endoscopic modalities, endoscopic therapy for bile leak was successful in 30 patients (93.8%). Two patients developed transient post-ERCP pancreatitis, which was mild, and both recovered without clinical sequelae. It was concluded that the endoscopic approach of ERCP should be considered a primary modality for the diagnosis and treatment of bile leakage after cholecystectomy.<sup>13, 14</sup>

#### CONCLUSION:

Within the limitations of the study we conclude that the injury to bile duct during cholecystectomy procedure can be very deliberating to the patients and proper steps should be taken for early diagnosis and treatment to avoid such deliberating condition. In our study, conservative treatment was significantly efficacious.

#### REFERENCES:

1. Vecchio R, MacFadyen BV, Latteri S. Laparoscopic cholecystectomy: an analysis of 114,005 cases of United States series. *Int Surg.* 1998;83:215–9.
2. Merrie AE, Booth MW, Shah A, Pettigrew RA, McCall JL. Bile duct imaging and injury. A regional audit of laparoscopic cholecystectomy. *Aust NZ J Surg.* 1997;67:706–11.
3. McMahon AJ, Fullarton G, Baxter JN, O'Dwyer PJ. Bile duct injury and bile leakage in laparoscopic cholecystectomy. *Br J Surg.* 1995;82:307–13.
4. Buanes T, Waage A, Mjåland O, Solheim K. Bile leak after cholecystectomy significance and treatment. Results from the National Norwegian Cholecystectomy Registry. *Int Surg.* 1996;81:276–9.
5. Brooks DC, Becker JM, Connors PJ, Carr-Locke DL. Management of bile leaks following laparoscopic cholecystectomy. *SurgEndosc.* 1993;7:292–5.
6. Kozarek RA, Traverso LW. Endoscopic stent placement for cystic duct leak following laparoscopic cholecystectomy. *GastrointestEndosc.* 1991;37:71–3.
7. Ponsky JL. Complications of laparoscopic cholecystectomy. *Am J Surg.* 1991;161:393–5.
8. Morgenstein L, Wong L., Berci G. Twelve hundred open cholecystectomies before the laparoscopic era: a standard for comparison. *Arch Surg.* 1992;127:400–3.
9. Palestrant AM, Vine HS, Sacks BA, Weinstein M, Ellison H. Nonoperative drainage of fluid collections following operations on the biliary tract. *SurgGynaecol Obstet.* 1983;156:305–9.
10. The Southern Surgeons Club. A prospect analysis of 1518 laparoscopic holecystectomies. *N Engl J Med* 1991;324:1073–8.
11. Buanes T, Waage A, Mjåland O, Solheim K. Bile leak after cholecystectomy significance and treatment: results from the National Norwegian Cholecystectomy Registry. *Int Surg.* 1996 Jul-Sep;81(3):276-9.
12. Sultan AM, Elnakeeb AM, Elshobary MM, et al. Management of post-cholecystectomy biliary fistula according to type of

- cholecystectomy. *Endoscopy International Open*. 2015;3(1):E91-E98. doi:10.1055/s-0034-1390747.
13. Shawhan RR, Porta CR, Bingham JR, McVay DP, Nelson DW, Causey MW, Maykel JA, Steele SR. Biliary leak rates after cholecystectomy and intraoperative cholangiogram in surgical residency. *Mil Med*. 2015 May;180(5):565-9. doi: 10.7205/MILMED-D-14-00426.
  14. Kim KH, Kim TN. Endoscopic Management of Bile Leakage after Cholecystectomy: A Single-Center Experience for 12 Years. *Clinical Endoscopy*. 2014;47(3):248-253. doi:10.5946/ce.2014.47.3.248.

**Source of support:** Nil

**Conflict of interest:** None declared

This work is licensed under CC BY: *Creative Commons Attribution 3.0 License*.