

Original Article

A Comparison between two Pulpotomy Agents: A Randomized Clinical Trial

Shweta Gulia¹, Neeru Chahal², Mohit Rana³, Anu Dhawan⁴

¹Pedodontist, ITS Dental College, Muradnagar, Ghaziabad, Uttar Pradesh, India, ²Department of Orthodontics, Tamil Nadu Govt Dental College, Tamil Nadu, India, ³MDS Department of Oral and Maxillofacial Surgery, Faculty of Dental Sciences, M S Ramaiah University of Applied Sciences Bangalore, Karnataka, India, ⁴MDS Conservative Dentistry and Endodontics, Sudha Rustogi College of Dental Sciences, Faridabad, Haryana, India

ABSTRACT:

Background: Pulpotomy is considered to be one of the most commonly preferred treatments in children. Various pulpotomy agents have been used. An ideal pulpotomy agent should be bactericidal, should not damage surrounding tissue. Search for such a pulpotomy agent is still continued. **Aim:** The objective of this study was to compare and evaluate between two pulpotomy agents i.e. formocresol and ferric sulphate. **Material method:** A total of 200 primary molars in 100 children were selected for the study. Healthy patients aged between 5 to 9 years were included in the study. Children were randomly assigned to FC group and FS group. Each group consisted of 100 primary molars. FC/FS was placed with a cotton pellet over the pulp stumps for 5 minutes and removed; the pulp stumps were then covered by zinc oxide-eugenol paste. The teeth of both groups were restored with stainless steel crowns. Follow up was done at an interval of 6 and 12 months. **Result:** Radiographic success rate for FC at 6 month was 93% and FS was 90%. The overall clinical success rate at 12 month interval for FC group was 96.5% and FS group was 96%. Internal resorption was most common radiographical pathology observed.

Conclusion: The overall success rate of present study is lower than those reported by other authors however no significant difference was observed in success rate of both the groups.

Key words: caries, pulpotomy, ferric sulphate, formocresol

Received: 2 May 2018

Revised: 16 May 2018

Accepted: 25 June 2018

Corresponding author: Dr. Shweta Gulia, Pedodontist, ITS Dental College, Muradnagar, Ghaziabad, Uttar Pradesh, India

This article may be cited as: Gulia S, Chahal N, Rana M, Dhawan A. A Comparison between two Pulpotomy Agents: A Randomized Clinical Trial. J Adv Med Dent Sci Res 2018;6(8):40-43.

INTRODUCTION

Pediatric dentistry aims in maintaining the primary dentition in an intact state until the permanent successors starts erupting. Studies have shown that caries if left untreated can have impact physiologically and socially.¹ Extraction of primary molars can lead to subsequent space loss, blocked out permanent teeth, and difficulty eating. Thus extractions of primary molars are not recommended.² Aim of pulpotomy is to maintain the arch integrity by allowing preservation of tooth. Formocresol was introduced by Buckley in the year 1904 and since then it is considered to be the gold standard material for pulpotomy.^{3,4}

However for past few years concerns have been raised about the toxicity and potential carcinogenicity of FC in humans. There comes the need for an alternative medicament to maintain vitality of pulp.^{5,6} Various other

medicaments available for pulpotomy are electrosurgery, laser, glutaraldehyde, ferric sulfate, freeze-dried bone, bone morphogenetic protein, and osteogenic protein.^{7,8,9,10,11} Ferric sulphate has been used as pulpotomy medicament for many years. Studies have reported that application of ferric sulphate in pulpotomized human primary molars with clinical and radiographic success rates of 100% and 97%, respectively.¹⁰

So in the present study we aimed to compare and evaluate the efficacy and treatment outcome of formocresol and ferric sulphate as a pulpotomy agent.

MATERIALS AND METHOD:

100 patients with 200 primary molars were selected for the study. Patients aged between 5 to 9 years of age were included. A split mouth design was planned. Of the 100

children 60 were males and 40 females. Children with chronic systemic disease and mentally challenged children were excluded from the study. Ethical committee clearance was obtained. A written informed consent was obtained from the patient’s parents and guardians before any procedure. Thorough examination of oral cavity was done using mouth mirror, explorer in torch light making them to sit upright in chair.

Inclusion criteria:

1. Patients aged between 5 to 9 years,
2. Patients with bilateral carious molar,
3. no history of spontaneous pain;
4. Absence of radiographic evidence of internal or external resorption.

Exclusion criteria:

1. More than 1/3rd of root resorbed
2. Furcal abscess
3. Non vital tooth
4. Widened periodontal ligament

Total sample were divided in two equal groups. Patients were randomly assigned to either of the groups. Group 1: formocresol group (FC) and Group 2: ferric sulphate group (FS). FC and FS pulpotomies were performed for the respective group followed by the placement of stainless steel crown. Two visits were planned, first visit involved access opening and treating pulp chamber with FC/FS followed by placement of ZOE paste. Stainless steel crown was placed in second visit. Patients were clinically and radiographically examined at an interval of 6 and 12 months.

STATISTICAL ANALYSIS:Data was collected from each patient and tabulated. Obtained data were analyzed and A *p*-value <0.05 was considered statistically significant.

RESULTS:

A total of 200 primary molars in 100 children were randomly divided in two groups, FC (n=100) and FS(n=100). Of the 100 patients included 60 were males and 40 were females. In present study 42% children were aged between 5-6 years, 31% were aged between 6-7 years, 12% were aged between 7-8 years and 15% were aged between 8-9 years. Majority of the patients were aged between 5 to 6 years. Of the 100 patients all the patients were available for follow up at 6 and 12 months. The clinical success rates for both the groups were found to be 100% at 6 months interval. Absences of pain, mobility, sinus or fistula were considered to 100% clinical success. However 3.5% cases of premature exfoliation of tooth was observed in FC group and 4% tooth in FS group at an interval of 12 months. The overall clinical success rate at 12 month interval for FC group was 96.5% and FS group was 96%.

At 6 month radiographic evaluation, pathological changes like furcal radiolucencies, internal resorption or excessive external root resorption were observed in few cases. In FC group 7% primary molars showed internal resorption and 9% cases in FS group. Premature exfoliation was absent in FC group whereas 1/100 i.e. 1% molars in FS were exfoliated. The overall radiographic success rate at 6 month for FC group was 93% and FS was 90%. At 12 month follow up, radiographic changes such as internal resorption was 6% in FC group, premature exfoliation in 7%, and external resorption in 7% and furcal radiolucencies in 4% cases. Whereas in FS, internal resorption was observed in 10% cases, premature exfoliation in 8%, external resorption in 6% and furcal radiolucencies in 8% cases. The overall radiographic success rate at 12 month for FC group was 89% and FS was 84%.

Table 1: Patient’s demographic value

Gender	Sample	Percentage
Males	60	60%
Females	40	40%
TOTAL	n = 100	100%

Table 2: Distribution of children according to age group

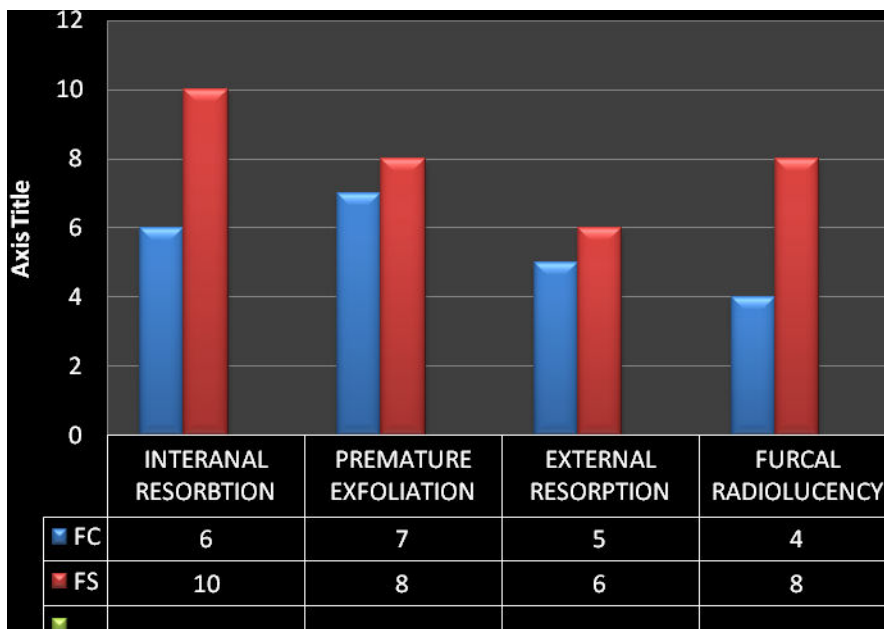
Groups	Frequency	Percentage
5-6	42	42%
6-7	31	31%
7-8	12	12%
8-9	15	15%
Total	100	100%

p> 0.05; Not significant

Table3: Comparison of success rate of formocresol and ferric sulphate radiographic treatment outcome in 6 and 12 months

Groups	AT 6 MONTH		AT 12 MONTHS	
FC	186	93%	178	89%
FS	180	90%	168	84%

Graph: 1 RADIOGRAPHICAL FINDING OBSERVED



DISCUSSION:

Dental caries infectious in nature, caries primary tooth has the potential to damage the permanent tooth buds. However dental caries are not the only reason that can lead to pulp exposure. Trauma can lead to exposure of pulp or accidental opening of pulp during restoration of tooth. The goal of pediatric dentistry is to maintain the vitality of pulp and use tooth as a natural space maintainer till permanent tooth starts erupting.

Carcinogenicity and mutagenicity nature of formocresol has been debated for long. This controversies lead to invention of other pulpotomy medicaments. In this clinical trial we made an attempt compare the clinical and radiographic success rate of FC and FS as a pulpotomy medicament in primary molars. Based on the result of present study the clinical success rate at 6 was 100 percent for both groups. Whereas clinical success rate at 12 month interval was found to be 96.5% for FC group and 96% for FS group.

Radiographic success rate for FC at 6 month was 93% and FS was 90%. In FC group 7% primary molars showed internal resorption and 9% cases in FS group. Radiographic success rate at 12 month for FC group was 89% and FS was 84%. In present study, internal resorption was observed in 10% cases in FS group; premature exfoliation in 8% cases, external resorption was evident in 6% and

furcalradiolucencies in 8% cases. Internal resorption was more common in FS group than any other radiographic pathology. Our results are similar to those reported by Smith et al and Fuks et al.^{12,9}Overall success rate in FS group was lower in present study as compared to Fei et al who reported a success rate of 96% after one year and Fukset al reported a radiographicsuccess rate of 93% at 24-34 months.^{9,10}Most of failure in FS group was due to internal resorption as ZOE paste was used it can be the reason behind internal resorption. Study conducted by Fuks et al considered study internal root resorption was considered as normal because no change appeared after 34 months.⁹At the same time Bahrololoomi et al suggested that internal root resorption have no effect on other teeth development and it should not be considered as radiographic failure.¹³ however few studies considered internal resorption as failure.¹⁴In our study also presence of internal resorption was considered as failure.

CONCLUSION:

Based on the result of our study it was found that the success rate of FS reported in current study was lower than compared to other studies present in literature. The difference observed could be due to the sample size. However no statistical difference was observed between FC

and FS group.the present study leads to the conclusion that ferric sulphate can be used as an pulpotomy agents However further study with a larger sample size and long follow up period is suggested.

REFERENCES:

1. Mandel ID. Oral infections: Impact on human health, well-being, and health-care costs. *CompendContinEduc Dent* 2004;25:881-882, 884, 888-90.
2. Low W, Tan S, Schwartz S. The effect of severe caries on the quality of life in young children. *Pediatr Dent* 1999;21:325-6.
3. Primosch RE, Glomb TA, Jerrell RG: Primary tooth pulp therapy as taught in predoctoral pediatric dental programs in the United States. *Pediatric Dentistry* 19:118-122, 1997.
4. Buckley JP: The chemistry of pulp decomposition, with a rational treatment for this condition and its sequelae. *Am Dent J* 3:764, 1904.
5. Block RM, Lewis RD, Sheats JB, Burke SG. Antibody formation to dog pulp tissue altered by formocresol within the root canal. *Oral Surg*45:282-92, 1978.
6. Pruhs RJ, Olen GA, Sharma PS. Relationship between formocresolpulpotomies on primary teeth and enamel defects on their permanent successors. *JADA* 94:698-700, 1977.
7. Shaw DW, Sheller B, Barras BD, Morton TH. Electrosurgical pulpotomy - a 6 months study in primates. *J Endod*13:500-505, 1987.
8. Shoji S, Nakamura M, Horiuchi H. Histopathological changes in dental pulps irradiated by CO2 laser: a preliminary report on laser pulpotomy. *J Endod*11:379-84, 1985.
9. Fuks AB, Cleaton-Jones P, Michaeli Y, Bimstein E. Pulp response to collagen and glutaraldehyde in pulpotomized primary teeth of baboons. *Pediatr Dent* 13:142-50, 1991.
10. Fei AL, Udin RD, Johnson R. A clinical study of ferric sulfate as a pulpotomy agent in primary teeth. *Pediatr Dent* 13:327-32, 1991.
11. Fadavi S, Anderson AW. A comparison of the pulpal response to freeze-dried bone, calcium hydroxide, and zinc oxide-eugenol in primary teeth in two cynomolgus monkeys. *PediatrDent* 18:52-56, 1996.
12. Smith NL, Seale NS, Nunn ME. Ferric sulfate pulpotomy in primary molars: a retrospective study. *Pediatr Dent* 2000 May-Jun;22(3):192-9.
13. Bahrololoomi Z, Ghodrati AR, Ghane G. Clinical and radiographic comparison of primary molars after pulpotomy with formocresol and ferricsulfate. *Journal of ShahidSadoughi University of Medical Sciences* 2005 Spring;13(2):81-5.
14. Ibricevic H, al-Jame Q. Ferric sulfate as pulpotomy agent in primary teeth: twenty month clinical follow-up. *J ClinPediatr Dent* 2000 Summer; 24(4):269-72.

Source of support: Nil

Conflict of interest: None declared

This work is licensed under CC BY: *Creative Commons Attribution 3.0 License*.