

Original Research

A comparative evaluation of bone changes following immediate dental implant placement with autogenous bone graft at different time intervals: An *in vivo* study

Amritpal Pabla¹, Nidhisha Bhalla²

¹Private Dental Practitioner, Chandigarh, India;

²Intern (BDS), Bhojia Dental College & Hospital, Baddi, HP, India

ABSTRACT:

Aim: The ultimate aim of this study was to evaluate the bone changes following immediate dental implant placement with autogenous bone graft at different time intervals. **Materials & Methods:** This study was designed on prospective ideology and attempted genuinely in male and female patients of 25 years to 45 years. All patients with any kind of anomaly related to head and neck region was excluded from the study. All patients with any underlying systemic diseases were also taken as exclusion. At first, a total of 10 patients were selected those undergone replacement of single missing anterior teeth with immediate implants with autogenous bone graft. The alveolar bone loss was evaluated radiologically using cone beam computed tomography. This was attempted on different time intervals of 3 months, 6 months and 9 months. Informed consent was obtained from the patients those were willingly ready for participation. All four surfaces i.e; mesial, distal, buccal and lingual was analyzed for bone loss/levels by cone beam computed tomography. **Statistical Analysis and Results:** Statistical analysis was attempted by statistical software Statistical Package for the Social Sciences (SPSS). The obtained data was sent to appropriate statistical tests to achieve p values, mean, standard deviation, standard error and 95% CI. $P \leq 0.05$ was considered as statistically significant. Out of 10 patients, males were 5 and females were 5. All selected and studied patients were divided into 4 age groups. 3 patients were falling in the age range of 25-29 years. 3 patients were falling in the age range of 30-34 years. Consequently we can presume that majority of the studied patients were of first two age groups. P value was found to be significant in group I & IV of age range 25-29 and 40-45 years. The calculated p value was 0.02 and 0.01 respectively. **Conclusion:** Within the limitations of the study, the authors concluded that there was noticeable bone loss on almost all surfaces of all studied immediate implants cases. Furthermore, these bone losses were in increasing pattern when seen after three months, six months and nine months of post operative phases with autogenous bone grafts. CBCT estimation also verified these bone losses accurately. These types of small and accurate detail can only be expressed by cone beam computed tomography.

Key words: Cone beam computed tomography; Bone loss, Immediate Implant, Autogenous bone grafts

Received: 23/09/2020

Modified: 18/10/2020

Accepted: 20/10/2020

Corresponding Author: Dr. Amritpal Pabla, Private Dental Practitioner, Chandigarh

This article may be cited as: Pabla A, Bhalla N. A comparative evaluation of bone changes following immediate dental implant placement with autogenous bone graft at different time intervals: An *in vivo* study. J Adv Med Dent Scie Res 2020;8(11):46-51.

INTRODUCTION

Literature has well evidenced that the relative percentage of partially edentulous patients in implant dentistry has considerably increased throughout the

world. These days, the immediate implant placements dominate in standard dental practice, predominantly the single missing tooth. This is solely due to the fact that the healing period of about five months post extraction

before implant placement is not a wise decision any more to patients.^{1,2,3} Therefore, the timing of implant positioning has become a significant matter in implantology. Single-tooth immediate implant placement and temporization, particularly in the aesthetic areas, is a extremely reliable therapy for rehabilitating the tooth.^{4,5,6} With the ever-increasing patient demand for lesser treatment time and enhanced esthetics and comfort have literally transferred research interest from implant endurance toward optimal conservation of soft and hard tissue. So, as and when possible, immediate positioning and rehabilitation of implants is strongly advocated. Many of the pioneer researchers have shown that there are some critical factors which adversely affect the final esthetic treatment. Researchers have also illustrated that recession of the peri-implant gingiva is one of the most important factors that determine long term success and esthetic outcomes. These bone quantities or heights adjoining to the implant are very crucial for long term preservation of the soft tissue and.^{7,8,9} While placing immediate implant into fresh extraction sockets, space typically exist between the implant surface and the buccal cortical plate of the bone. Furthermore, extraction of teeth, the jaw bone experiences steady atrophy especially in the first three months of service.^{10,11,12} Significant declining in the available height of the jaw bone has been demonstrated by researchers. Such changes are constantly happening after tooth extraction. The ultimate aim of this study was to evaluate the bone changes following immediate dental implant placement with autogenous bone graft at different time internals.

MATERIALS & METHODS

This study was designed on prospective ideology and attempted genuinely in male and female patients of 25 years to 45 years. All patients with any kind of anomaly related to head and neck region was excluded from the study. All patients with any underlying systemic diseases were also taken as exclusion. At first, a total of 10 patients were selected those undergone replacement of single missing anterior teeth with immediate implants with autogenous bone graft. The study sample included patients with optimal oral hygiene, sufficient bone volume for implant placement. Patients who were unable to attend post operative follow up visits were excluded from the study. All patients in the study were administered local anesthesia with adrenaline and the affected teeth were cautiously extracted with minimal trauma to the alveolar bone. Osseointegrated conventional implants of suitable dimensions were

placed judiciously using standard osteotomy procedures. This was attempted in the same clinical visit immediately after the extraction on affected teeth. Autogenous bone grafts was also administered in the desired sites to manage bone related requirements. The alveolar bone loss was evaluated radiologically using cone beam computed tomography. This was attempted on different time intervals of 3 months, 6 months and 9 months. Informed consent was obtained from the patients those were willingly ready for participation. All four surfaces i.e; mesial, distal, buccal and lingual was checked for bone loss/levels by cone beam computed tomography. Right before the execution of the study, authors had explained the relative significance of this study to all selected patients. The privacy and other unified rights of the patients along with their freedom of expression were not disclosed. Results thus received was compiled in table and subjected to basic statistical analysis. P value less than 0.05 was considered significant ($p < 0.05$).

STATISTICAL ANALYSIS AND RESULTS

In this study, all perceptible findings and data were compiled and sent for statistical analysis using statistical software Statistical Package for the Social Sciences version 21 (IBM Inc., Armonk, New York, USA). The processed data was subjected to suitable statistical tests to obtain p values, mean, standard deviation, chi-square test, standard error and 95% CI. Table 1 and Graph 1 showed that out of 10 patients, males were 5 and females were 5. All selected and studied patients were divided into 4 age groups. 3 patients were falling in the age range of 25-29 years. 3 patients were falling in the age range of 30-34 years. Consequently we can presume that majority of the studied patients were of first two age groups. P value was found to be significant in group I & IV of age range 25-29 and 40-45 years. The calculated p value was 0.02 and 0.01 respectively. Table 2,3,4,5,6,7 showed basic statistical details with level of significance evaluation using Pearson chi-square test [for three, six, nine months post operative phases]. Nine months post operative phases showed higher bone losses than three and six month groups. Nevertheless the differences were clearly seen on CBCT reports and can be explained on the basis of growing bacterial colonies/infections in the contained bony environment. Level of significance assessment by pearson chi-square test [for three, six and nine months post operative phases] illustrated significant values of p for all four studied surfaces [mesial, buccal, lingual, distal].

Table 1: Age & gender wise distribution of patients

Age Group (Yrs)	Male	Female	Total	P value
25-29	1	2	3	0.02*
30-34	2	1	3	0.06
35-39	1	1	2	0.08
40-45	1	1	2	0.01*
Total	5	5	10	*Significant

Table 2: Fundamental statistical illustration [three month post operative phase]

Surfaces [10 immediate implants]	Mean Bone Loss	Std. Deviation	Std. Error	95% CI
Mesial	0.43	0.728	0.872	1.60
Distal	0.53	0.822	0.302	1.96
Buccal	0.61	0.373	0.852	1.62
Lingual	0.53	0.828	0.220	1.50

Table 3: Level of significance evaluation by pearson chi-square test [three month post operative phase]

Surfaces [10 immediate implants]	Pearson Chi-Square Value	df	Level of Significance (p value)
Mesial	1.920	1.0	0.00*
Distal	1.763	2.0	0.2*
Buccal	2.502	1.0	0.02*
Lingual	1.029	1.0	0.01*

Table 4: Fundamental statistical illustration [six month post operative phase]

Surfaces [10 immediate implants]	Mean Bone Loss	Std. Deviation	Std. Error	95% CI
Mesial	0.72	0.323	0.928	1.53
Distal	0.63	0.212	0.827	1.52
Buccal	0.61	0.823	0.739	1.51
Lingual	0.69	0.920	0.902	1.89

Table 5: Level of significance evaluation by pearson chi-square test [six month post operative phase]

Surfaces [10 immediate implants]	Pearson Chi-Square Value	df	Level of Significance (p value)
Mesial	1.029	1.0	0.01*
Distal	1.906	2.0	0.00*
Buccal	2.920	1.0	0.01*
Lingual	1.012	1.0	0.00*

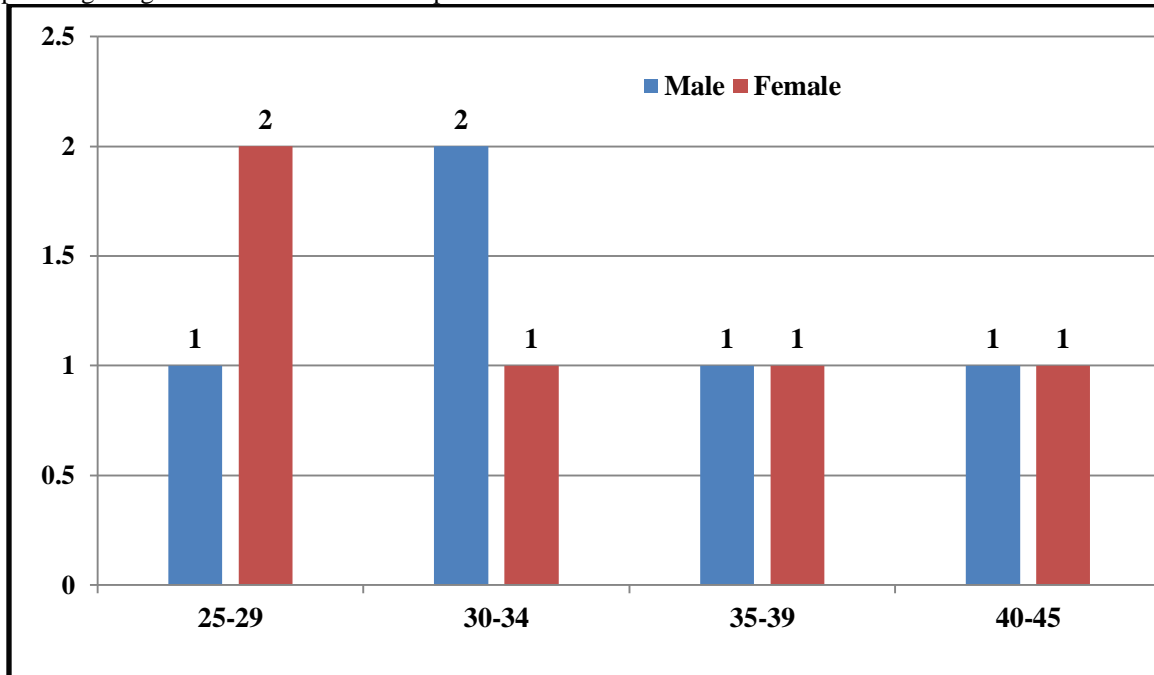
Table 6: Fundamental statistical illustration [nine month post operative phase]

Surfaces [10 immediate implants]	Mean Bone Loss	Std. Deviation	Std. Error	95% CI
Mesial	0.82	0.728	0.728	1.51
Distal	0.73	0.291	0.928	1.59
Buccal	0.71	0.893	0.277	1.55
Lingual	0.78	0.920	0.902	1.86

Table 7: Level of significance evaluation by pearson chi-square test [nine month post operative phase]

Surfaces [10 immediate implants]	Pearson Chi-Square Value	df	Level of Significance (p value)
Mesial	1.928	1.0	0.01*
Distal	1.747	2.0	0.02*
Buccal	2.516	1.0	0.03*
Lingual	1.938	1.0	0.01*

Graph 1: Age & gender wise distribution of patients



DISCUSSION

As we all are aware that immediate implant positioning can be defined as implant placement immediately following tooth extraction and as a part of the same surgical procedure, or as implant placement immediately following extraction of a tooth which must be combined in most patients with a bone grafting technique to eliminate peri-implant bone defects.^{13,14,15} Alveolar bone changes are described as a transformation in the shape and architecture of the jaw bone. Socket healing procedure usually followed and characterized by bone loss and resorption. These changes can lead to several undesirable changes or modifications in final the implant restoration. Many of the studies have shown that ridge preservation procedure is very imperative. When not performed, a mean vertical bone loss of 1.25-2.25 mm and 4.25-5.20 mm in the horizontal bone loss are noticed in the long term services of immediate implant.^{16,17,18,19} Bone losses are more significant at the buccal side than lingual or palatal sides of alveolar plates. It is more marked in the molar region, but it remains significant in the anterior region due to aesthetic needs. After placement of implants, most of the bone resorption happened during

the first year of implant placement. Roughly 2/3rd bone losses are noticed during the first three months. With the recent development of advanced dental implant technologies and biomaterials, dental implants have become the ideal treatment for partially and completely edentulous patients.^{20,21,22,23,24} Various strategies of implant placement had been evolved. Amongst these, the immediate implant placement in anterior teeth had been extensively acknowledged after it been introduced in the late1980s. Its popularity is mainly because of the fact that it can avoid the buccal bone resorption, cut down the period of treatment time, and avoid the lack of teeth due to the temporary restoration.^{25,26,27} Additionally, many of the studies have shown that there are roughly half of immediate implant placement done in anterior teeth needs bone augmentation. This is mainly because of the defect of buccal bony plate which can be created by trauma, apical periodontitis and periodontitis. Bone augmentation cannot be carried out with-out bone graft materials. Autogenous bone, allogenic bone and alloplastic materials are bone graft materials that are currently used in dental clinic. Autogenous bone graft material is considered as the golden standard since it's capable of osteogenesis,

osteoinduction, and osteoconduction.^{28,29} Our study aimed to evaluate the bone changes following immediate dental implant placement with autogenous bone graft at different time intervals.

CONCLUSION

Within the limitations of the study, the authors concluded that there was obvious bone loss on almost all surfaces of all studied immediate implants cases. Furthermore, these bone losses were in increasing pattern when noticed after three months, six months and nine months of post operative phases with autogenous bone grafts. CBCT assessment also verified these bone losses precisely. These types of small and accurate detail can only be expressed by cone beam computed tomography. Therefore, clinical usages of autogenous bone grafts done not guarantee about alveolar bone preservation in post operative phases. Our study results must be considered as suggestive for presuming prognosis for similar clinical conditions. Nevertheless, we expect some other large scale studies to be performed that might further establish certain standard and concrete norms in these perspectives.

REFERENCES

1. Kan JYK, Rungcharassaeng K, Deflorian M, et al. Immediate implant placement and provisionalization of maxillary anterior single implants. *Periodontology* 2000. 2018;77:197–212.
2. Cassetta M, Perrotti V, Calasso S, et al. Bone formation in sinus augmentation procedures using autologous bone, porcine bone, and a 50:50 mixture: a human clinical and histological evaluation at 2 months. *Clin Oral Implants Res.* 2015;26:1180–4.
3. Zucchelli G, Sharma P, Mounssif I. Esthetics in periodontics and implantology. *Periodontology* 2000. 2018;77:7–18.
4. Aghaloo TL, Misch C, Lin GH, et al. Bone augmentation of the edentulous maxilla for implant placement: a systematic review. *Int J Oral Maxillofac Implants.* 2016;31(Suppl):s19–30.
5. Schmitt CM, Doering H, Schmidt T, et al. Histological results after maxillary sinus augmentation with Straumann (R) Bone Ceramic, Bio-Oss(R), Puros(R), and autologous bone. A randomized controlled clinical trial. *Clin Oral Implants Res.*2013;24:576–85.
6. Kim YK, Kim SG, Um IW, et al. Bone grafts using autogenous tooth blocks: a case series. *Implant Dent.* 2013;22:584–9.
7. Jeong KI, Kim SG, Kim YK, et al. Clinical study of graft materials using autogenous teeth in maxillary sinus augmentation. *Implant Dent.* 2011;20:471–5.
8. Lee JY, Kim YK, Yi YJ, et al. Clinical evaluation of ridge augmentation using autogenous tooth bone graft material: case series study. *J Korean Assoc. Oral Maxillofac Surg.* 2013;39:156–60.
9. Schwarz F, Hazar D, Becker K, et al. Efficacy of autogenous tooth roots for lateral alveolar ridge augmentation and staged implant placement. A prospective

- controlled clinical study. *J Clin Periodontol.* 2018;45:996–1004.
10. Kim YK, Kim SG, Yun PY, et al. Autogenous teeth used for bone grafting: a comparison with traditional grafting materials. *Oral Surg Oral Med Oral Pathol Oral Radiol.* 2014;117:e39–45.
11. Kim YK, Lee JH, Um IW, et al. Guided bone regeneration using demineralized dentin matrix: long-term follow-up. *J Oral Maxillofac Surg.*2016;74:515.e511–9.
12. Gual-Vaques P, Polis-Yanes C, Estrugo-Devesa A, et al. Autogenous teeth used for bone grafting: a systematic review. *Med Oral Patol Oral Cir Bucal.*2018;23:e112–9.
13. Buser D, Chappuis V, Belser UC, et al. Implant placement post extraction in esthetic single tooth sites: when immediate, when early, when late? *Periodontology* 2000. 2017;73:84–102.
14. Schropp L, Wenzel A, Kostopoulos L, et al. Bone healing and soft tissue contour changes following single-tooth extraction: a clinical and radiographic 12-month prospective study. *Int J Periodontics Restorative Dent.* 2003;23:313–23.
15. Milinkovic I, Cordaro L. Are there specific indications for the different alveolar bone augmentation procedures for implant placement? A systematic review. *IntJ Oral Maxillofac Surg.* 2014;43:606–25.
16. Guiol J, Campard G, Longis J, et al. Anterior mandibular bone augmentation techniques. Literature review. *Revue de stomatologie de chirurgie maxillo-faciale et de chirurgie orale.* 2015;116:353–9.
17. Jun SH, Ahn JS, Lee JI, et al. A prospective study on the effectiveness of newly developed autogenous tooth bone graft material for sinus bone graft procedure. *J Adv Prosthodont.* 2014;6:528–38.
18. Nampo T, Watahiki J, Enomoto A, et al. A new method for alveolar bone repair using extracted teeth for the graft material. *J Periodontol.* 2010;81:1264–72.
19. Prasad M, Butler WT, Qin C. Dentin sialo phosphor protein in biomineralization. *Connect Tissue Res.* 2010;51:404–17.
20. Kim YK, Kim SG, Oh JS, et al. Analysis of the inorganic component of autogenous tooth bone graft material. *J Nanosci Nanotechnol.* 2011;11:7442–5.
21. Amato F, Polara G, Spedicato GA. Tissue dimensional changes in single-tooth immediate extraction implant placement in the esthetic zone: a retrospective clinical study. *Int J Oral Maxillofac Implants.* 2018;33:439–47.
22. Mazzocco F, Jimenez D, Barallat L, et al. Bone volume changes after immediate implant placement with or without flap elevation. *Clin Oral Implants Res.* 2017;28:495–501.
23. Kinaia BM, Shah M, Neely AL, et al. Crestal bone level changes around immediately placed implants: a systematic review and meta-analyses with at least 12 months' follow-up after functional loading. *J Periodontol.* 2014;85:1537–48.
24. Al Kudmani H, Al Jasser R, Andreana S. Is bone graft or guided bone regeneration needed when placing immediate dental implants? A systematic review. *Implant Dent.* 2017;26:936–44.
25. Velasco-Ortega E, Wojtovicz E, Espana-Lopez A, et al. Survival rates and bone loss after immediate loading of

- implants in fresh extraction sockets(single gaps). A clinical prospective study with 4 year follow-up. *Med OralPatol Oral Cir Bucal*. 2018;23:e230–6.
26. Orio-Siciliano V, Marenzi G, Blasi A, et al. Influence of platform-switched, laser-micro textured implant on marginal bone level: a 24-month case series tudy. *Int J Oral Maxillofac Implants*. 2016;31:162.
27. Terashima A, Takayanagi H. Overview of Osteo immunology. *Calcif Tissue Int*.2018;102:503–11.
28. Walsh MC, Takegahara N, Kim H, et al. Updating osteoimmunology: regulation of bone cells by innate and adaptive immunity. *Nature reviews. Rheumatology*. 2018;14:146–56.
29. Blakney AK, Swartzlander MD, Bryant SJ. The effects of substrate stiffness on the in vitro activation of macrophages and in vivo host response to poly (ethylene glycol)-based hydro gels. *J Biomed Mater Res A*. 2012;100:1375–86.