

Case Report

Review on Pathogenesis of Hybrid variant of AOT and Report of a Rare Case

Urvashi Tomar¹, Kundendu Arya Bishen², Atul Singh³, Bhuvnesh Airen⁴

¹Senior Lecturer, ²Professor and Head, Oral and Maxillofacial Pathology, ⁴Senior Lecturer, Dept. of Public health dentistry, Index Institute of dental sciences, Malwanchal University, Indore-452016 M.P.

³Associate professor, Oral and Maxillofacial surgery, Faculty of Dentistry, Uttar Pradesh University of Medical Sciences, Saifai, Itawa-206130 U.P.

ABSTRACT:

Background: Dentigerous cyst is an odontogenic cyst commonly seen arising from the impacted mandibular third molars. The epithelial lining of Dentigerous cyst may transform into an odontogenic neoplasm- like ameloblastoma. Very few cases of Adenomatoid odontogenic tumor (AOT) developing as a complication in Dentigerous cyst have been reported in literature and it has been termed as-Hybrid variant of AOT. AOT is a benign tumor of odontogenic origin composed of odontogenic epithelium presenting in diverse histopathological patterns. These lesions are usually solid but are occasionally cystic. It is generally found in young females in anterior maxilla in association with an unerupted tooth. Here we present a rare case of simultaneous occurrence of both Dentigerous cyst and AOT in a patient and review the literature on this “hybrid variant” with special emphasis on its pathogenesis. **Methods:** PubMed and Medline data was thoroughly researched for Hybrid variant of AOT/ AOT developing as a complication in Dentigerous cyst. **Results:** Only 12 cases of AOT associated with Dentigerous cysts were found in literature. **Case Description:** A 12 year female patient with chief complaint of swelling in anterior maxilla for past 10 months was found to have radiolucency around an impacted canine. The lesion was surgically removed and microscopic examination revealed the presence of luminal proliferations of AOT in dentigerous cyst. **Conclusion:** This case was diagnosed as Hybrid AOT which is a rare variant. Documentation of such cases is imperative to determine incidence, sexual predilection, age of incidence and understanding pathogenesis of this distinct variant. **Key words:** AOT, Hybrid AOT, AOT developing in dentigerous cyst.

Received: 18 April 2018

Revised: 4 May 2018

Accepted: 7 May 2018

Corresponding author: Dr. Kundendu Arya Bishen (MDS, PhD), Professor and Head, Oral and Maxillofacial Pathology, Index Institute of dental sciences, Malwanchal University, Indore-452016 M.P.

This article may be cited as: Tomar U, Bishen KA, Singh A, Airen B. Review on Pathogenesis of Hybrid variant of AOT and Report of a Rare Case. J Adv Med Dent Scie Res 2018;6(6):38-42.

INTRODUCTION:

The epithelial lining of the odontogenic cyst may transform into an odontogenic neoplasm-like ameloblastoma or AOT. There are very few cases of odontogenic tumors either arising from or associated with odontogenic cysts.¹⁻³ The purpose of this article is to present a rare case of AOT that has originated in the wall of a Dentigerous cyst.

The Adenomatoid odontogenic tumor (AOT) which was first described as an adamantinoma in 1934, acknowledged as a distinct odontogenic tumor in 1948 by Stafne. It is a benign (hamartomatous) and noninvasive lesion, with slow but progressive growth. It accounts for 2–7 % of all odontogenic tumors and is less frequent.

Philipsen et al. subdivided this condition into three groups referred to as follicular, extrafollicular, and peripheral. All these variants share a common histologic characteristic that indicates a common origin being remnant of dental lamina. The most common is the central variant (97.2%), of which 73% is the follicular type.⁴ Peripheral variant is rare with only 18 cases reported so far.⁵ Based on the clinical and radiographic assessment follicular variant is often initially mistaken as Dentigerous cyst.⁶

REVIEW RESULTS:

Neoplastic and hamartomatous lesions can occur at any stage of odontogenesis, odontogenic tumors with combined features of epithelial and mesenchymal

components may arise within the odontogenic cyst.⁷ The epithelial lining of the odontogenic cyst may transform into an odontogenic neoplasm-like ameloblastoma or AOT. Very few cases of AOT associated with a Dentigerous cyst have been reported in the literature. PubMed and Medline data showed a total of 12 cases of AOT associated with a Dentigerous cyst in the literature.⁸ AOT in association with the Dentigerous cyst is seen to occur in the anterior as well as the posterior maxilla and even in the angle of the mandible.^{9,10} In our case, the lesion was present in the anterior maxilla with most of the lining representing cystic lining resembling reduced enamel epithelium and the nodular proliferation in the lumen suggesting association of AOT with the cyst.

AOT, is an uncommon benign epithelial lesion of odontogenic origin, which was first described by Dreibaldt in 1907 as 'Pseudoameloameloblastoma'.¹¹ In 1915, Harbitz reported it as 'Cystic Adamantoma'.¹² Stafne in 1948, considered it as a distinct entity and the term 'Adenomatoid Odontogenic Tumor' was proposed in 1969 by Philipsen and Birn.^{13,14}

The central variant of AOT accounts for approximately 96% of all AOTs of which 71% are of the follicular type. This is more commonly found in the maxilla than in the mandible. The follicular type shows a well defined, unilocular radiolucency associated with the crown and often part of the root of an unerupted tooth, thus mimicking a Dentigerous or follicular cyst. In fact, 77% of follicular AOT are initially diagnosed as Dentigerous cysts.¹⁵ The origin of AOT is controversial. The tumor is derived from the complex system of dental lamina or its remnant. It has been reported that some odontogenic cysts occur in association with odontogenic tumors.¹¹ It is not clear whether the lining of an associated cyst represents a true Dentigerous cyst, cystic change within an AOT or may symbolize a distinct entity. Most central AOT's occur in a pericoronal relationship with an associated tooth; there is no way to be assertive whether the lining of an associated cyst represents a true Dentigerous cyst or a secondary cystic change within the AOT.⁷ The lesion grows into a nearby dental follicle or next to follicle leading to "envelopmental" theory which describes that the proliferation of epithelial remnants (unknown stimulus) within the gubernacular canal causes fusion between the tumor and the reduced enamel epithelium of the erupting tooth, resulting in embracement of tooth by the tumor.¹⁶ The term "Hybrid variant" was suggested where AOT is derived from Dentigerous cyst. In our case the tumor was surrounding the fully formed canine suggesting an envelopmental pathogenesis or "hybrid variant".⁹

Garcia-Pola et al.¹⁷ have described the proliferation of an AOT in the epithelial lining of a Dentigerous cyst. Tajima et al.^[18] described an AOT located in the superior portion of the maxillary sinus and speculated that the tumor was derived from a Dentigerous cyst. Philipsen et al.^{6,16,19} have

also postulated that the follicular type of AOT develops from nests of cells within the dental lamina and hence surrounds the tooth. As neoplastic and hamartomatous lesions can occur at any stage of odontogenesis, odontogenic tumors with combined features of epithelial and mesenchymal components may arise within the odontogenic cyst. Rick et al. have reported the occurrence of AOT with many types of cysts and neoplasms including Dentigerous cyst, calcifying odontogenic cyst, odontoma, ameloblastoma, etc.⁷ The lining of a cystic AOT may be present as thin nonkeratinised stratified squamous epithelium, exhibiting nodule formation and subepithelial hyalinization (present case). The cystic lining may transform into nodular thickening.^{3,17}

CASE DESCRIPTION:

A 12 year female patient reported with the chief complaint of swelling in the anterior maxilla for the past 10 months. Initially the swelling was small which gradually increased to the present size over a period time. It was associated with dull, intermittent pain with no pus discharge. Medical and personal histories were noncontributory.

On inspection, the face was asymmetrical with swelling on anterior maxilla extending from left ala of nose superiorly to the infraorbital margin and inferiorly below the corner of lip causing downward angulation of left side of upper lip and corner of mouth (Figure 1a). On palpation, the swelling was ovoid in shape, firm in consistency afebrile to touch and normal color of overlying mucosa. On intraoral examination, dome shaped expansion of buccal cortex was seen extending from distal surface of central incisor mesially to the mesial surface of maxillary first molar distally. The swelling was obliterating the buccal vestibule completely (Figure 1b).

Orthopantomogram (OPG) revealed unilocular radiolucency associated with unerupted canine, lateral incisor and premolar (Figure 2). Based on the clinical and radiographic findings, the diagnosis of Dentigerous cyst was made. The lesion was surgically removed and sent for the histopathological examination.

On gross examination most of the specimen showed normal cystic capsule attached at the neck of tooth (Fig. 3). One portion of lining showed luminal nodular proliferation. Microscopically, H & E stained sections of the excised specimen showed a cystic lining of nonkeratinized stratified squamous epithelium of 2-3 cell thickness resembling reduced enamel epithelium (Fig. 4a). The area with luminal proliferation in gross specimen showed islands of spindle shaped cells with few cells arranged in ductal pattern with peripheral cells being columnar showing reversal of polarity (Fig. 4b & 4c). Hence a diagnosis of Hybrid variant of AOT was made.

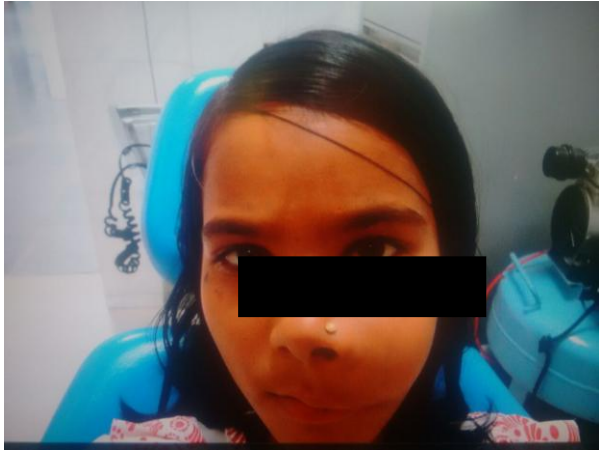

Fig-1a

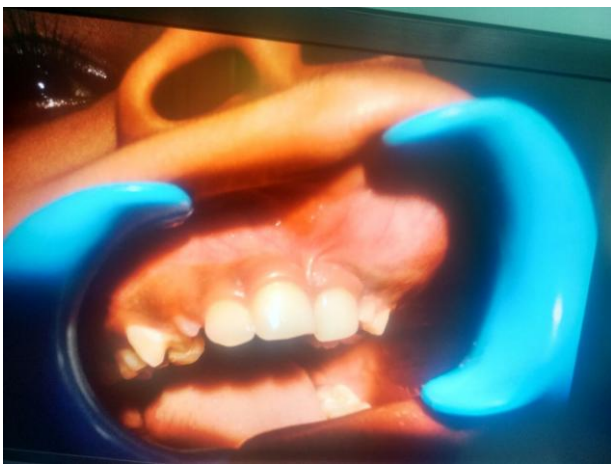

Fig-1b

Fig-1: Photographs showing the (a) extraoral and (b) intraoral extensions of anterior maxillary swelling in a young female

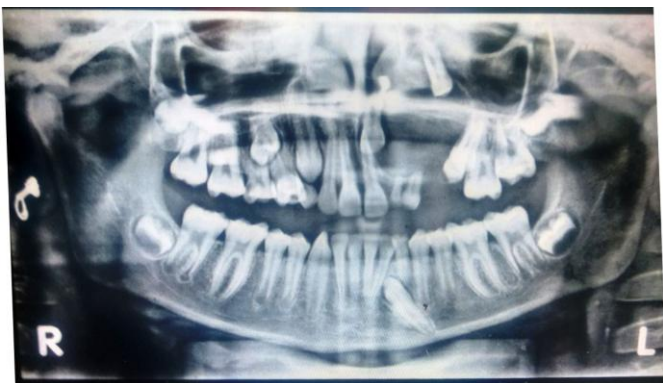

Fig-2: Photograph of OPG showing a radiolucency around an impacted canine

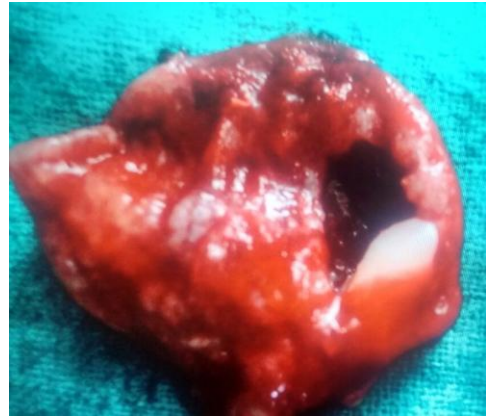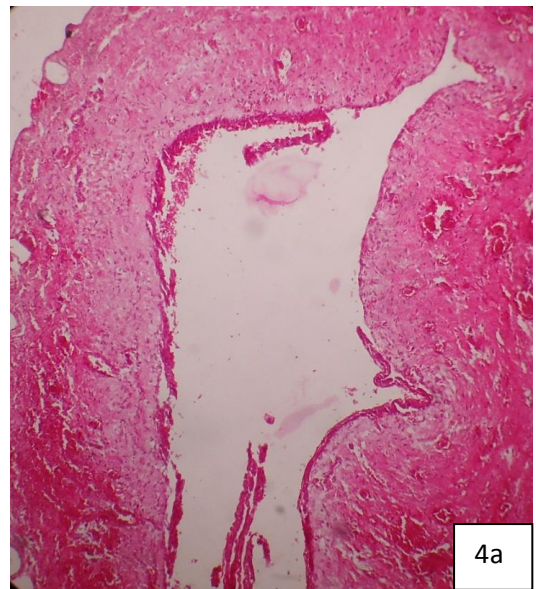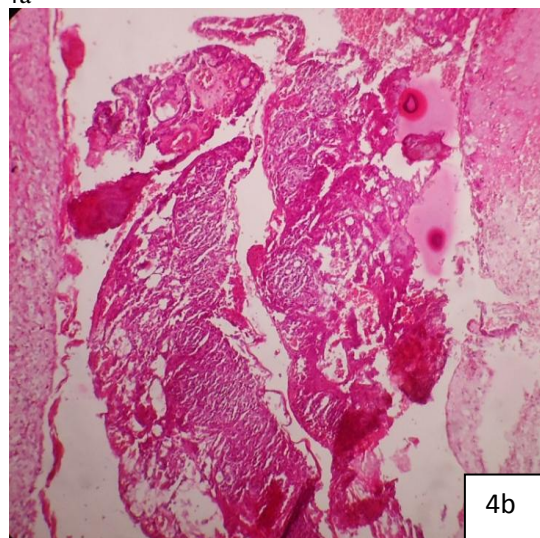


Fig-3: Photograph of gross specimen showing a cystic lesion around neck of impacted canine



4a

Fig-4a



4b

Fig-4b

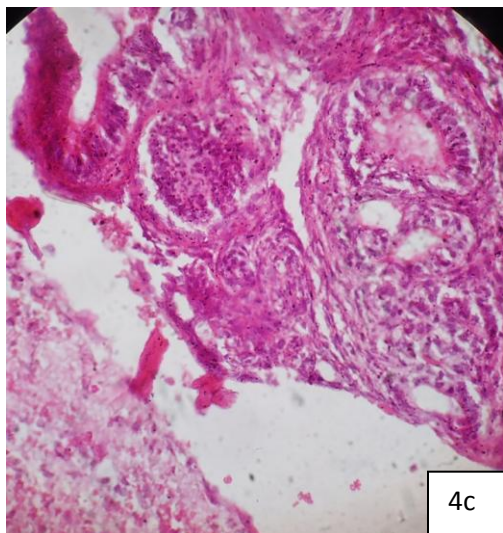


Fig-4c

Fig-4: Photomicrographs of H&E stained sections of lesion showing (a) cystic lumen surrounded by lining resembling reduced enamel epithelium suggestive of dentigerous cyst [10x], (b) Epithelial proliferations within the cyst lumen [4x], (c) Luminal proliferations in Ductal and Rosette patterns suggestive of AOT [40x].

DISCUSSION:

In the present case, histological features of Dentigerous cyst lining and AOT in form of nodules and rosette corroborate the transformation of cystic lining into the neoplasm. This feature was also observed in case reports by Warter et al., Sandhu et al., Nonaka et al. and others.^[10,20,21] Whether a lesion in this case has the potential to develop into a frank AOT is unknown.

The origin of the follicular variant occurs before or after cystic expansion is yet to be fully explained. If the tumor grows after cystic expansion, then this confirms its origin from a Dentigerous cyst, conversely, if it occurs before cystic expansion, then the tumor tissue might have filled the follicular space and the AOT presents as a solid tumor.^[22] This can be considered that, given enough time, even those originating from a cyst may grow and fill the lumen completely. It cannot be precluded that the Dentigerous cyst associated with an impacted canine developed first followed by development of AOT in the cyst wall.^[22]

It should be differentiated from Dentigerous cyst radiographically, which most frequently occurs as a pericoronal radiolucency in the jaws. Dentigerous cyst encloses only the coronal portion of the impacted tooth having attachment at the CEJ, whereas AOT shows radiolucency usually surrounding both the coronal and radicular aspects of the involved tooth. Though, in cases where AOT grows from Dentigerous cyst, like in this

case, the radiographs are indecisive. The irregularity in the wall of cyst may indicate the development of AOT.

It is uncertain whether this entity (AOT arising from Dentigerous cyst) has a more aggressive potential. The AOT and Dentigerous cyst are both benign, encapsulated lesions and conservative surgical enucleation or curettage is the treatment of choice. Dentigerous cyst has good prognosis and recurrences are very rare after complete removal of the lesion.^[10] However, there are some reports of aggressive behavior of AOT where there has been an intracranial extension from the maxilla and also report of a case that had recurred after almost 7 years.^[10,23,24] According to Marx and Stern, the more appropriate term is adenomatoid odontogenic cyst(AOC). Nevertheless, the present case is mainly cystic with areas of AOT-like proliferations into the lumen, thus supporting the view of Marx and Stern hooking to the terminology of adenomatoid odontogenic cyst (AOC).^[8]

CONCLUSION:

The present case appeared to be a usual Dentigerous cyst around the impacted canine, but extensive sampling and careful microscopic examination revealed it to be the Hybrid variant of AOT. Thus, meticulous histopathological evaluation is required for all enucleated cysts, which could contribute to the precise diagnosis and appropriate management. Regular follow up is required in these cases to study their behavioral pattern.

CLINICAL SIGNIFICANCE:

Further research reporting is required into the possibility of fourth type of a “hybrid” kind of AOT, apart from the already established three types of AOTs, is required. Documentation of such cases is imperative to determine incidence and understanding the pathogenesis of this distinct variant.

REFERENCES:

1. Chuan-Xiang Z, Yan G. Adenomatoid odontogenic tumor: a report of a rare case with recurrence. *J Oral Pathol Med* 2007;36(7):440–443.
2. McMillan MD, Smillie AC. Ameloblastomas associated with Dentigerous cysts. *Oral Surg Oral Med Oral Pathol* 1981;51(5):489–496.
3. Jivan V, Altini M, Meer S, Mahomed F. Adenomatoidodontogenic tumor (AOT) originating in a unicystic ameloblastoma: a case report. *Head Neck Pathol* 2007;1(2):146–14.
4. Gupta S et al.: Adenomatoid odontogenic tumor. *Journal of Indian Academy of Oral Medicine & Radiology*, 2016;Vol 28, Issue 4 .October-December
5. Sreenivas SD, Lalita CS, Harsha G, Rao VC. Multiple pathology in a single lesion: AOT associated with Dentigerous cyst. *J Maxillofac Oral Surg* 2015;14:215–21.
6. H. P. Philipsen and H. Birm, “The adenomatoid odontogenic tumour, ameloblastic adenomatoid tumour or adenoameloblastoma,” *Acta Pathologica et Microbiologica Scandinavica*, vol. 75, no. 3, pp. 375–398, 1969.

7. Rick GM .Adenomatoid odontogenic tumor. Oral Maxillofac Surg Clin North Am 2004;16(3):333–354.
8. Manjunatha B S, Harsh A, Purohit S, Naga MV. Adenomatoid odontogenic tumor associated with a Dentigerous cyst. J Can Res Ther 2015;11:649.
9. Chen YK, Hwang IY, Chen JY, Wang WC, Lin LM. Adenomatoid odontogenic tumor arising from a Dentigerous cyst – A case report. Int J Pediatr Otorhinolaryngol Extra 2007;2:257-63.
10. Sandhu SV, Narang RS, Jawanda M, Rai S. Adenomatoid odontogenic tumor associated with Dentigerous cyst of the maxillary antrum: A rare entity. J Oral Maxillofac Pathol 2010;14:24-8.
11. Batra P, Prasad S, Parkash H .Adenomatoid odontogenic tumour: review and case report. J Can Dent Assoc 2005;71(4):250–253.
12. Philipsen HP, Reichart PA, Siar CH, Ng KH, Lau SH, Zhang X et al. An updated clinical and epidemiological profile of the adenomatoid odontogenic tumour: a collaborative retrospective study. J Oral Pathol Med 2007;36(7):383–393.
13. Lee JK, Lee KB, Hwang BN .Adenomatoid odontogenic tumor: a case report. J Oral Maxillofac Surg 2000;58(10):1161–1164.
14. Philipsen HP, Birn H . The adenomatoid odontogenic tumour. Ameloblastic adenomatoid tumour or adenoameloblastoma. Acta Pathol Microbiol Scand 1969;75(3):375–398.
15. Rashmi G, Goje S, Harshavardhan S, Kumar MP. Adenomatoid odontogenic tumour. Indian J Dent Adv 2009;1:67-71.
16. Philipsen HP, Samman N, Ormiston IW, Wu PC, and Reichart PA, “Variants of the adenomatoid odontogenic tumor with a note on tumor origin,” Journal of Oral Pathology and Medicine, vol. 21, no. 8, pp. 348–352, 1992.
17. Garcia-Pola Vallejo M, Gonzalez Garcia M, Lopez-Arranz JS, Herrero Zapatero A Adenomatoid odontogenic tumor arising in a dental cyst: report of unusual case. J Clin Pediatr Dent 1998; 23(1):55–58.
18. Tajima Y, Sakamoto E, Yamamoto Y .Odontogenic cyst giving rise to an adenomatoid odontogenic tumor: report of a case with peculiar features. J Oral Maxillofac Surg 1992; 50(2):190–193.
19. Philipsen HP, Reichart PA, Zhang KH, Nikai H, Yu QX Adenomatoid odontogenic tumor: biologic profile based on 499 cases. J Oral Pathol Med .1991; 20(4):149–158.
20. Warter A, George-Diolombi G, Chazal M, Ango A Melanin in a Dentigerous cyst and associated adenomatoid odontogenic tumor. Cancer 1990;66(4):786–788
21. Nonaka CF, de Souza LB, Quindere´ LB .Adenomatoid odontogenic tumour associated with Dentigerous cyst—unusual case report. Braz J Otorhinolaryngol 2007;73(1):129–13.
22. Singh V, Goyal S, Sheikh S, Shambulingappa P, Singh B, Singh R. Adenomatoid odontogenic tumor with Dentigerous cyst: Report of a rare case with review of literature. Contemp Clin Dent 2012;3:S244-7.
23. John JB, John RR. Adenomatoid odontogenic tumor associated with Dentigerous cyst in posterior maxilla: A case report and review of literature. J oral Maxillofac Pathol 2010;14:59-62.
24. Toida M, Hyodo I, Okuda T, Tatematsu N. Adenomatoid odontogenic tumor: Report of two cases and survey of 126 cases in Japan. J Oral Maxillofac Surg 1990;48:404-8.

Source of support: Nil

Conflict of interest: None declared

This work is licensed under CC BY: **Creative Commons Attribution 3.0 License.**