

## Case Report

### Orthomorphic and Orthognathic treatment for Aesthetics and Function in Facial Asymmetry Post TMJ Ankylosis - A Case Report

<sup>1</sup>Raja Satish Prathigudupu, <sup>2</sup>Ranjith Kumar P, <sup>3</sup>Phani Kumar K, <sup>4</sup>Surekha Kanala, <sup>5</sup>Rahul VC Tiwari, <sup>6</sup>Latheef Saheb S.

<sup>1</sup>Senior Registrar, Ministry of Health, Amiri Dental Casualty, Kuwait,

<sup>2</sup>Professor & Consultant, Confydenz Dental Clinic, Guntur, Andhra Pradesh, India,

<sup>3</sup>Professor, OMFS, Sibar Institute of Dental Sciences, Takkellapadu, Guntur, AP, India,

<sup>4</sup>Professor & HOD, Government Dental College, Vijayawada, Andhra Pradesh, India,

<sup>5</sup>FOGS, MDS, OMFS & Dentistry, JMMCH & RI, Thrissur, Kerala, India,

<sup>6</sup>Consultant, Partha Dental Clinic, Hyderabad, Telangana, India

#### ABSTRACT:

**Introduction:** Orthomorphic surgery is performed when alone orthognathic is unable to correct the condition. It refers to correction offacial asymmetry or jaw deviation without changing the occlusion. It is the best treatment option available so far for such deformities.

**Case Report:** A 23-year-old male patient presented to us with the complaint of flattening of the right side of face. Patient gave a history of childhood trauma which lead to temporomandibular joint ankylosis and was operated for the same at the age of 10 years. He reported for unaesthetic appearance and was diagnosed as facial asymmetry with occlusal cant. Treatment was planned in two stages by giving priority to correctfunction first and then proceeding for the aesthetics 6 months later. **Conclusion:** An optimal function and aesthetic was achieved post-operatively. The described technique has the quality to alter the dentofacial deformity in any magnitude and directionin accurate dimension.

**Key words:** Orthognathic surgery, orthomorphic surgery, facial asymmetry, two stage procedure.

Received: 2 May 2018

Revised: 16 May 2018

Accepted: 17 May 2018

**Corresponding Author:** Dr. Raja Satish Prathigudupu, Senior Registrar, Ministry of Health, Amiri Dental Casualty, Kuwait.

**This article may be cited as:** Prathigudupu RS, P Kumar R, K Kumar P, Kanala S, Tiwari RV, S Saheb L. Orthomorphic and Orthognathic treatment for Aesthetics and Function in Facial Asymmetry Post TMJ Ankylosis - A Case Report. J Adv Med Dent Scie Res 2018;6(7):41-45.

#### INTRODUCTION:

All normal human faces have some degree of asymmetry. The ancient Greeks were probably the first to notice these variations between the two sides of the face, as discovered much later by analysis of their statuary, which included mild to moderate facial asymmetries. Normal asymmetries such as these often go unnoticed by the general public. Esthetically pleasing and apparently symmetrical faces do indeed exhibit skeletal asymmetries and one side of the face can be rather different from the other and still be considered completely normal. The level at which asymmetry becomes unacceptable to a patient is variable and depends on many factors, most of which are psychological.[1] Facial

asymmetry, when obvious, has enormous sociopsychological impact on the affected individuals. It can occur as a consequence of developmental anomalies or disease or after trauma or surgery. Surgical reconstruction is usually indicated in most instances involving a noticeable facial asymmetry. This is usually accomplished by reconstructing the deformed portion with its normal counterpart working as a reference.[2] Patients who present with significant facial asymmetry are not only concerned with restoring functional occlusion but also with improving esthetics and beauty. This has often been a source of social scorn for many of these patients. Beauty and symmetry have often been thought of synonymously; hence, the belief that

unattractiveness is the result of asymmetry.[3] Unilateral temporomandibular joint ankylosis occurring during the active growth period if left without treatment, or when improperly treated, is often complicated by the development of secondary changes in the structure, shape, and size of the mandible together with the surrounding tissues.[4] Mandibular asymmetry may be caused by infection and trauma during the growing period. Primary trauma may lead to asymmetry and in some cases ankylosis. Asymmetry may also follow a surgical procedure or a malunited fracture.[5] Orthognathic surgery for the correction of facial deformity arising from discrepancy in spatial relationship or dimensional differences is well established. However, when the cause of the deformity includes an alteration of the shape of the jaws, orthognathic surgery is unable to correct the resulting contour deformity.[6] For this reason in the management of facial asymmetry, orthomorphic principles of management are an adjunct to orthognathic surgery or Osseo distraction.[7] The surgical correction consisting of an osteotomy aimed at restoring the morphology is denoted the term “orthomorphic” to distinguish it from conventional orthognathic surgery. The orthomorphic correction aims to correct deformities related to shape and contour of the jaws without affecting the status of occlusion.[6]

**CASE REPORT:**

A 23-year-old male patient presented to us with the complaint of flattening of the right side of face. Patient gave a history of childhood trauma which lead to temporomandibular joint ankylosis and was operated for the same at the age of 10 years. He reported for unaesthetic appearance and was diagnosed as facial asymmetry with occlusal cant. Treatment was planned in two stages by giving priority to correct function first and then proceeding for the aesthetics 6 months later. On occlusal examination an occlusal cant was present.(Figure 1) Clinically a clear-cut asymmetry was seen in the lower border of

mandible.(Figure 2) Lateral Cephalogram and Posteroanterior Cephalogram Confirmed the diagnosis of facial asymmetry by deviation of jaw on the left side due to underdevelopment of growth from childhood trauma leading to TMJ ankylosis. (Figure 3)Grumman’s analysis and Three-dimensional computed tomography elicited mandibular deviation on left side. (Figure 4). After confirmation of diagnosis first occlusal correction was planned by performing a differential Le Fort I osteotomy as the vertical height was more on the left side compared to right side. So, the occlusal cant was corrected. After 6 months of correcting occlusion, facial asymmetry correction was planned. An extended lateralsliding genioplasty was done for correction of mandibular underdevelopment. We achieved patients and our expectation by combining orthognathic correction primarily and orthomorphic correction secondarily after 6 months.

Figure 1: Clinical Picture & Occlusion Cant Pre and Post-operative.

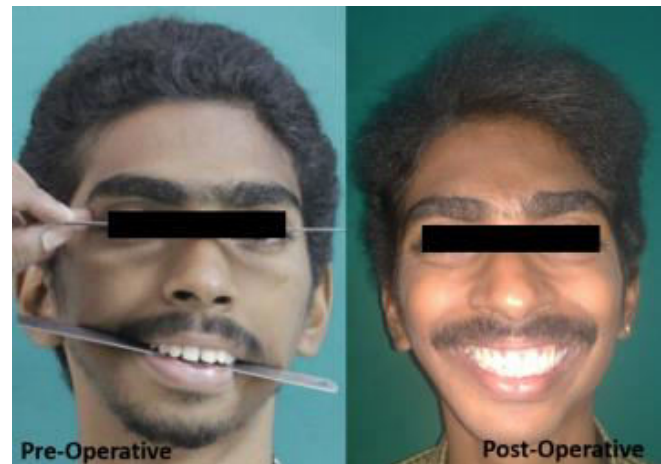


Figure 2: Deviation & Occlusion Pre and Post-operative.

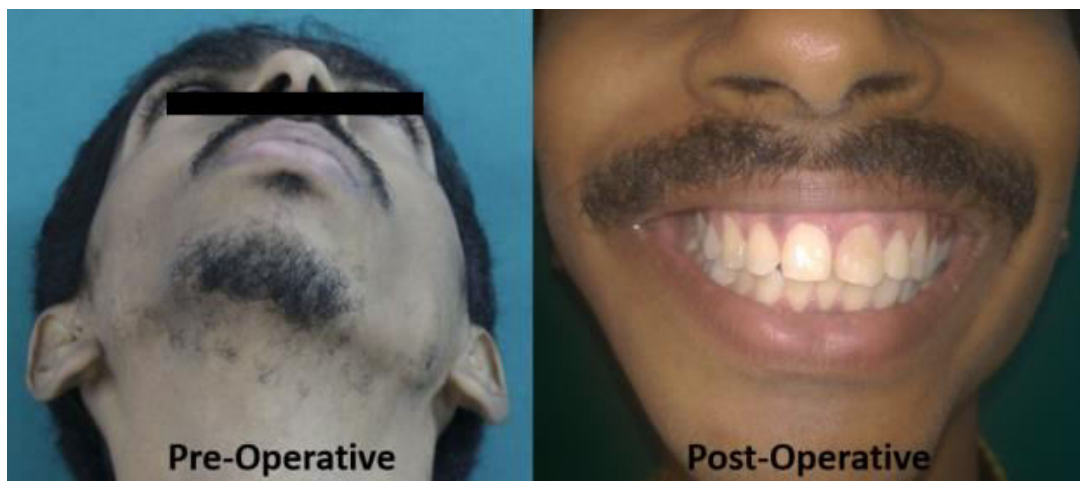

Figure 3: Lateral and PA Cephalograms Pre and Post-operative

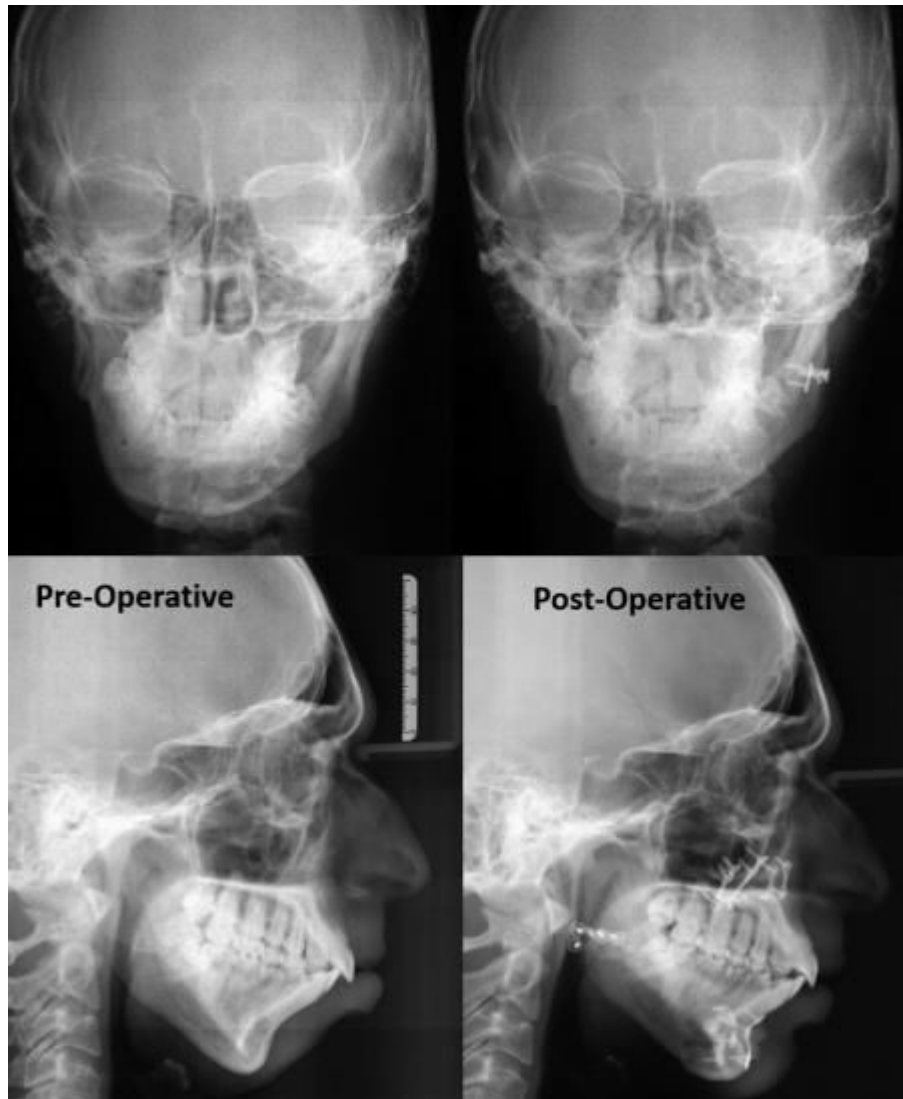
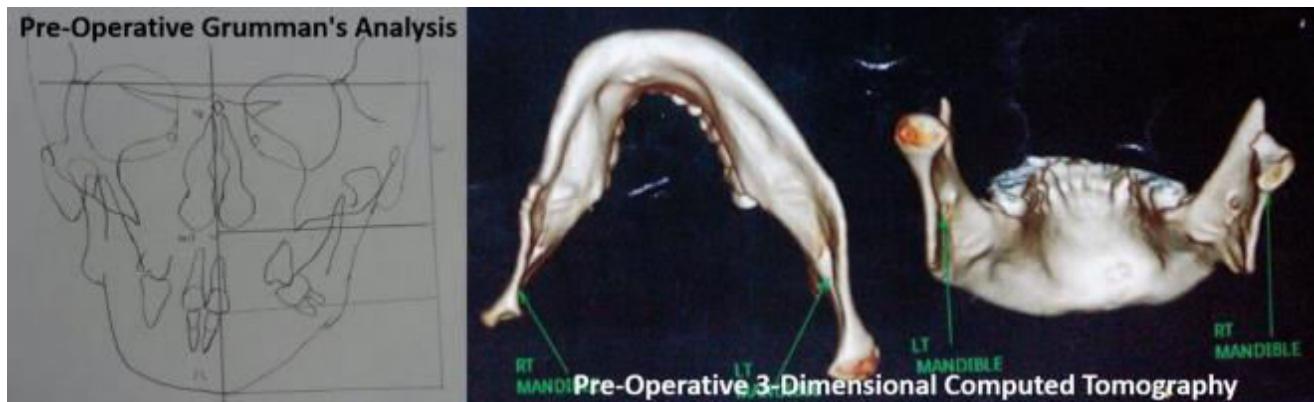

Figure 4: Grumman's Analysis & 3DCT Pre-operative.



## **DISCUSSION:**

Surgical correction of facial asymmetry is more challenging than the correction of symmetrical deformities. Often, unilateral mandibular deficiencies are associated with slight downward growth of the maxilla on the affected side, altering the position of midline structures of the middle-third of the face and creating an occlusal cant. We resorted to a line drawn perpendicular to the inter-inner canthal line as the facial midline. [8] Inferior border osteotomy of the mandible performed intraorally can be employed independently or in conjunction with other procedures to correct facial asymmetry of the mandible. Genioplasty is a well-documented procedure to move the chin to a more desirable position. The anterior chin can be moved in all 3 dimensions of space. Extended lateral sliding genioplasty is the technique followed by the first author since 1992 for the correction of facial asymmetry, especially for residual deformities of unilateral TMJ ankylosis. In TMJ ankylosis, because of the destruction of the growth center and the missing functional stimulus, the mandible on the affected side is short due to deficient growth. The opposite side of the mandible is dragged towards the affected side. This leads to facial asymmetry, with false fullness of the affected side and deficiency of the unaffected side, and resultant deviation of the mandible. The conventional technique of aesthetic correction of the above-described deformity is by ramus osteotomies and bone grafting. This technique often jeopardizes the existing occlusion. In most patients, because of the pre-existing trismus, the teeth are unhealthy, hence orthodontic treatment may not be feasible. Benefits of the 'long' osteotomy cut extending to the gonial region bilaterally have been put forward by Tessier. [9] They include maintenance of a smooth natural inferior mandibular border, noninterference with the occlusion, and simultaneous increase in the width of the jaw line. Extended lateral sliding genioplasty is an intraoral procedure where the inferior mandibular border is cut from one gonial region to the opposite gonial region below the inferior alveolar canal. Wolfe estimated the position of the inferior alveolar canal to be 6 mm below the mental foramen. [10] We made the osteotomy cut on the deficient side approximately 5 mm below the mandibular canal. However, the cut was slanted downwards by approximately 45° towards the lingual side so that the nerve canal was spared. Multiple holes were made on the lingual cortex and the bone was split using osteotomes and/ or a split spreader. None of the patients experienced transection of the nerve inside the canal. The divided bone segment was slid forward and laterally, so that the chin and the sunken lateral aspect of the mandible were augmented. The deficient side of the mandible was lengthened and the deviation of the chin was corrected. The same technique can be employed in conjunction with other osteotomies such as sagittal ramus split, maxillary osteotomies, etc., for correction of complex asymmetric deformities. Stepping on the lateral mandibular contour is often created after lateral sliding of the extended

genioplasty segment and, in such cases, autogenous bone grafting can be used to interpose or obliterate the step deformity. When aesthetic correction is performed simultaneously with functional correction of ankylosis, the resected bone may be used as the graft material thus eliminating the need for donor site surgery. Management of the mental nerve is an important issue. Hinds and Kent favor dissection and protection of the mental nerve during osteotomy. [11] Posnick et al also advocated dissection and retraction during osteotomy and reported persistent sensory deficit in 10% of their patients after 1 year. [12] Spear and Kassar [13] and Lindquist and Obeid [14] advised identification and protection of the mental nerve. These authors reported permanent mental nerve deficit in 6% [13] and 10% [13] of patients, respectively, and are against the idea of dissecting the nerve. Converse and Wood-Smith were of the opinion that the mental nerve may be divided if it obstructs the osteotomy. [15] To obtain adequate space to perform inferior border osteotomy of the mandible, extensive dissection or traction is required on the mental nerve. Moreover, inadvertent avulsion of the nerve is a possibility and is a more serious problem than intentional division of the nerve because it does not lend itself to correction by microsurgical repair. The advantages of extended lateral sliding genioplasty may be summarized as follows: a simple procedure accomplished through an intraoral degloving incision in the buccal vestibule, less time-consuming than the conventional ramus osteotomies for the correction of unilateral mandibular deficiencies, existing occlusion is not disturbed, deficient side of the mandible is lengthened, the chin is brought close to the midline, the apparent deficiency on the unaffected side is corrected by the lateral shift of the inferior border segment and thus fullness is achieved, the procedure can be done concomitantly with the correction of TMJ ankylosis, the procedure can be combined with other orthognathic procedures such as ramus sagittal split and maxillary osteotomy, harmony and balance of the face (vertical and horizontal proportions) are improved, psychological rehabilitation of the patient is rapid.

## **CONCLUSION:**

The surgical correction of facial asymmetry is extremely challenging because the asymmetry may be centered at the hard and/or soft tissue; any of a combination of dimensions; and it may involve the maxilla, mandible, and symphysis or any combination of the three. It is the effective treatment of the hard tissues that brings about the most dramatic change, as soft tissue defects are usually corrected after skeletal correction.[16] Combination of orthognathic and orthomorphic surgery is useful in correcting cases of mandibular deformity which increases quality of life of patients.

## REFERENCES:

1. Severt TR, Proffit WR. The prevalence of facial asymmetry in the dentofacial deformities population at the University of North Carolina. *Int J Adult Orthod Orthognath Surg* 1997;12:171-6.
2. Wong TY, Fang JJ, Chung CH, Huang JS, Lee JW. Comparison of 2 methods of making surgical models for correction of facial asymmetry. *J Oral Maxillofac Surg* 2005;63:200-8.
3. Stringer D, Brown B. Correction of mandibular asymmetry using angled titanium mesh. *J Oral Maxillofac Surg* 2009;67:1619-27.
4. El-Sheikh MM, Medra AM. Management of unilateral temporomandibular ankylosis associated with facial asymmetry. *J Craniomaxillofac Surg* 1997;25:109-15.
5. Cohen MM. Perspectives on craniofacial asymmetry. III. Common and/or well-known causes of asymmetry. *Int J Oral Maxillofac Surg* 1995;24:127-33.
6. Salins PC, Venkatraman B, Kavarody M. Morphometric basis for orthomorphologic correction of mandibular asymmetry. *J Oral Maxillofac Surg* 2008;66:1523-31.
7. Kent JN, Craig MA. Secondary autogenous and alloplastic reshaping procedures for facial asymmetry. *Atlas Oral Maxillofac Surg Clin North Am* 1996;4:83-105.
8. Mani V, Ranjith P. Efficacy of extended sliding genioplasty [thesis]. Calicut University, Kerala, India; 1993-1995.
9. Tessier P. Chin advancement as an aid in the correction of the deformities of the mental and submental regions: discussions. *Plast Reconstr Surg* 1981;67:630.
10. Wolfe S. Chin advancement as an aid in correction of deformities of the mental and submental regions. *Plast Reconstr Surg* 1981;6:624-629.
11. Hinds EC, Kent JN. Genioplasty: the versatility of horizontal osteotomy. *J Oral Surg* 1969;27:690-700.
12. Posnick JC, AL-Qattan MM, Stepner NM. Alteration in facial sensibility in adolescents following sagittal split and chin osteotomies of the mandible. *Plast Reconstr Surg* 1996;97:920-927.
13. Spear SL, Kassan M. Genioplasty. *Clin Plast Surg* 1989;48:210-216.
14. Lindquist CC, Obeid G. Complications of genioplasty done alone or in combination with sagittal split osteotomy. *Oral Surg* 1988;6:13-16.
15. Converse JM, Wood-Smith D. Horizontal osteotomy of the mandible. *Plast Reconstr Surg* 1964;34:464-471.
16. Reyneke JP, Tsakiris P, Kienle F. A simple classification for surgical treatment planning of maxillomandibular asymmetry. *Br J Oral Maxillofac Surg* 1997;35:349-51.

**Source of support:** Nil

**Conflict of interest:** None declared

This work is licensed under CC BY: ***Creative Commons Attribution 3.0 License.***