

## Original Article

### Efficacy of Formocresol and Ferric Sulphate Pulpotomies in Cariously Exposed Primary Molars

Asma Munir Khan<sup>1</sup>, Anser Maxood<sup>2</sup>, Khurram Shahzad Farani<sup>3</sup>, Nosheen Asim Khan<sup>4</sup>

<sup>1</sup>BDS, FCPS (Operative Dentistry) Assistant professor, Department of Conservative Dental Sciences, College of Dentistry, Qassim University, KSA, <sup>2</sup>M.Sc, FRACDS, Head of Dental Department, P.I.M.S, Islamabad, Pakistan, <sup>3</sup>BDS, MCPS (PGT), <sup>4</sup>BDS, FCPS (PGT)

#### ABSTRACT:

**Background:** Pulpotomy is the most accepted therapy for the management of cariously exposed pulps in symptom-free primary molars. Formocresol being considered as a “gold standard” has shown high success rates (ranging between 70-97%) as compared to all other techniques, but concerns about cytotoxicity and potential mutagenicity have been reported. As a consequence alternative techniques have been evaluated. Ferric sulphate (15.5%) has been used recently, and has gained much attention as a pulpotomy medicament. **Aim:** To compare the efficacy of formocresol and ferric sulphate Pulpotomies, in cariously exposed primary molar teeth in age group 5-10-years in Dental Department, Children hospital, PIMS, Islamabad, which is affiliated with QPGMC. **Materials and Methods:** 70 healthy subjects between the age group of 5-10 years with cariously exposed vital pulp were randomly allocated to either the formocresol or the ferric sulphate group of 35 teeth each. The pulpotomy procedure was performed on the selected teeth. The patients were recalled after 3 and 6 months interval and were evaluated both radiographically and clinically. The data was analyzed using the SPSS statistical software programme version 14. Total duration of this study was nine months from Jan 2009- September 2009. **Results:** Amongst the subjects, 61.4% were males and 38.6% were females. The teeth most commonly involved were the mandibular second primary molars. At 6 months follow up, only 2 out of 35 patients in both FC and FS groups reported pain and showed periapical radiolucency, thus the success rate in both FC and FS group was found to be 94.28%.

**Conclusion:** There were no statistically significant differences between the success rates for the two groups at the  $P < 0.05$  level as tested by Fisher's exact test. This study shows that Ferric Sulphate appears to be a promising alternative material for pulpotomy in primary molar teeth.

**Key words:** Pulpotomy, Formocresol, Ferric sulphate, Cytotoxicity, Mutagenicity

Received: 20 November 2017

Revised: 30 November 2017

Accepted: 2 December 2017

**Corresponding author:** Dr. Asma Munir Khan, BDS, FCPS (Operative Dentistry) Assistant professor, Department of Conservative Dental Sciences, College of Dentistry, Qassim University, KSA,

**This article may be cited as:** Khan AM, Maxood A, Farani KS, Khan NA. Efficacy of Formocresol and Ferric Sulphate Pulpotomies in Cariously Exposed Primary Molars. J Adv Med Dent Scie Res 2018;6(1):1-6.

#### INTRODUCTION:

Pulpotomy is the most accepted therapy for the management of cariously exposed pulps in symptom-free primary molars.<sup>1</sup> Its aim is to preserve the radicular pulp, to avoid pain and swelling, and ultimately, to retain the tooth.<sup>2</sup> The fundamental objective of the pediatric pulp therapy is the maintenance of the arch integrity by allowing preservation of teeth that would otherwise be destined for extraction.<sup>3</sup> A pulpotomy is typically indicated on a deep tooth with a deep carious lesion. Deep interproximal caries in primary molars is an indication for vital pulp therapy, followed by the placement of stainless steel crowns to preserve arch perimeter, and maintain arch health<sup>4</sup>. The contraindications for the pulpotomy procedure

include: swelling on mucosa, pathologic mobility, resorption, interradicular or periapical radiolucency, pulp calcification, or history of spontaneous pain.<sup>4,6</sup>

AAPD guidelines state that a tooth requiring a pulpotomy should be vital. Often, obtaining a precise pulpal diagnosis in children is a significant challenge for the dentist, primarily due to issues of cooperation and behavior management.<sup>7</sup> Children tend to adapt their behavior in order to avoid painful stimuli<sup>8</sup> and this includes inaccurate response to a pulp test. The outcomes following the vital pulp therapy can be broadly divided into devitalisation, preservation and regeneration, depending upon the type of pulp medicament used.<sup>9</sup> Although many techniques are

being widely used, yet the evidence is lacking as to which is the most appropriate method of optimizing pulp tissue recovery.<sup>10</sup> From the above treatments, the formocresol technique is considered the most universally taught and preferred pulp therapy for primary teeth for over sixty years.<sup>11</sup> (avram and pulver,1989;primosh et al;1997).

Formocresol was first advocated as a disinfectant for root canals in endodontic treatment of permanent teeth due to its bactericidal and pulpal fixation effects. Later, Sweet pioneered its clinical usage in a multi-visit technique for the pulp therapy of primary teeth in 1930.<sup>12</sup> The technique has undergone a lengthy evolution to shorten the application time to 5 minutes and reduce the concentration of the agent to 1:5 which is as effective as a full strength solution in terms of its initial toxicity to fibroblasts.<sup>13-16</sup>

The dilute formocresol is now considered as a “gold standard”<sup>17</sup> against which all the new medicaments and techniques are being compared. Although it has shown high success rates (ranging between 70-97%) as compared to all other techniques, but concerns about cytotoxicity and potential mutagenicity of the formaldehyde content and defects in succedaneous teeth and delayed healing of periapical tissues following primary tooth pulpotomies have been reported.<sup>9,18-20</sup>

It is for the above reasons that more biocompatible treatment alternatives have been sought, including glutaraldehyde, ferric sulphate, electrosurgery, calcium hydroxide, collagen solution, bone morphogenic proteins, MTA and laser irradiation.<sup>21</sup>

Calcium hydroxide has also been used as an alternative to formocresol, but its success has been poor compared with marked internal resorption reported. Other reported techniques include electrosurgery, lasers, enriched collagen solution. The efficacy of these approaches awaits full evaluation.<sup>22</sup>

Ferric sulphate (15.5%) has been used recently, and has gained much attention as a pulpotomy medicament, due to its haemostatic effect.<sup>3</sup> In contact with blood, a ferric ion protein complex is formed, and the membrane of the complex seals and cut vessels mechanically, producing hemostasis. Another form of this agent has been widely used in skin and mucosal biopsies, and as a haemostatic agent.<sup>23</sup> This haemostatic compound was proposed on the basis that it might prevent problems encountered with clot formation and thereby minimizing the chances for inflammation and internal resorption.<sup>24</sup> It has shown promising results when compared to formocresol pulpotomy in direct comparisons and meta-analysis of systematically reviewed literature.<sup>25-27</sup> Ferric sulfate produces a local but reversible inflammatory response in oral soft tissues<sup>28</sup>. No concerns about toxic or harmful effects of ferric sulfate have been published in the dental or medical literature despite regular clinical use since 1856<sup>29</sup>. The present study aims to evaluate and compare the success rate of formocresol pulpotomy with ferric sulphate in primary molar teeth vis-à-

vis Pakistani population, as no such clinical study has been conducted in this respect.

#### **MATERIALS AND METHODS:**

The study was carried out at Dental Department, Children Hospital, PIMS, Islamabad, which is a tertiary care hospital. The study was approved by the ethical review committee of the institute. Total duration of this study was nine months. Research work was started in July 2007 till February 2008. Study design was True, experimental. Seventy healthy subjects {the age ranging between 5 to 10 yrs of both sexes} with at least one symptom-free, restorable primary molar with a cariously exposed vital pulp. Randomized sampling technique was employed using the random number table.

Patients were selected from out-door patient pool of Dental Department, PIMS according to the inclusion and exclusion criteria. Informed consent was taken from the patient by explaining benefits of study.

Pre-operative assessment of both patient and oral status were done after taking complete medical and dental history and details of any presenting complaints, followed by detailed clinical and radiographic examination. A clinical exclusion criterion was spontaneous pain, swelling, tenderness to percussion and pathological mobility.

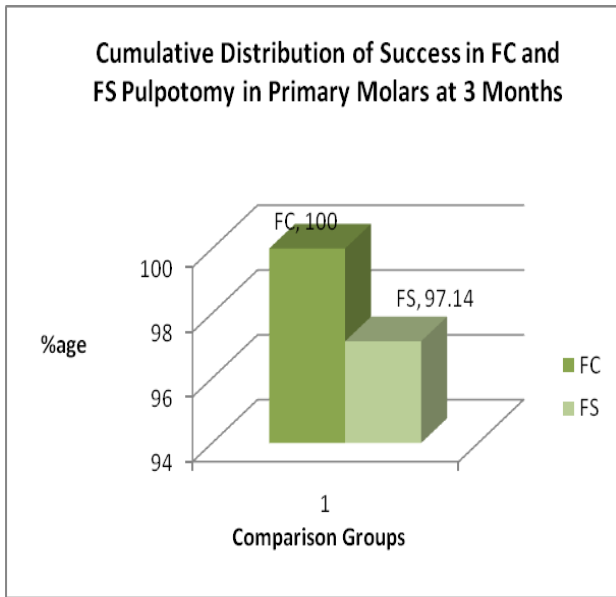
#### **STATISTICAL ANALYSIS:**

The data analysis was performed using the Statistical Package for Social Sciences (SPSS) software, version 13. Descriptive statistics had been used to analyze the demographic data. Frequency (percentage) was presented for tooth number treated, gender and socioeconomic status. Chi-square test was used to compare the clinical and radiological success of formocresol and ferric sulfate pulpotomies. P value <0.05 were considered as statistically significant.

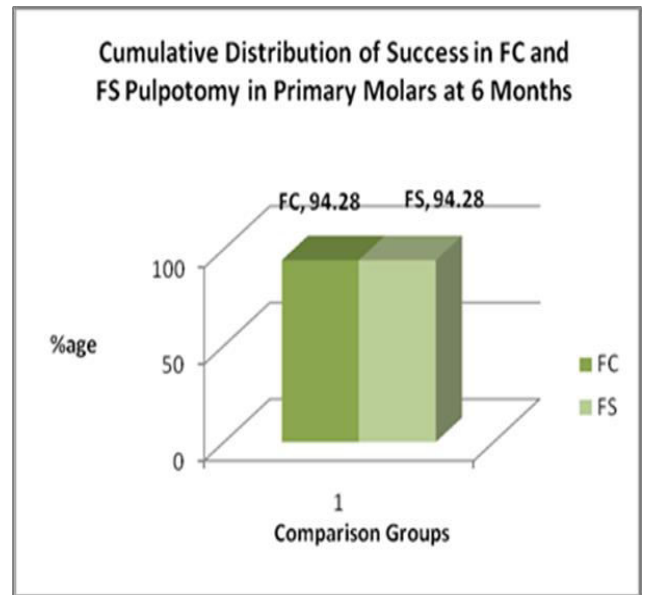
#### **RESULTS:**

In the present study the age range of children who presented with cariously exposed vital pulps was from 5 to 10 years. The mean age was 6.9±1.29 years. Amongst the subjects, 61.4% were males and 38.6% were females. The teeth most commonly involved were the mandibular second primary molars. At 6 months follow up, only 2 out of 35 patients in both FC and FS groups reported pain and showed periapical radiolucency, thus the success rate in both FC and FS group was found to be 94.28% after 6 months whereas the failure rate was found to be 5.71%. Two teeth in each group presented with periapical radiolucency and pain and were considered as a failure. The differences between success and failure rates of two treatment methods were not statistically significant as P value was >0.05. (Fisher exact test at level 5%)

**Graph 1**



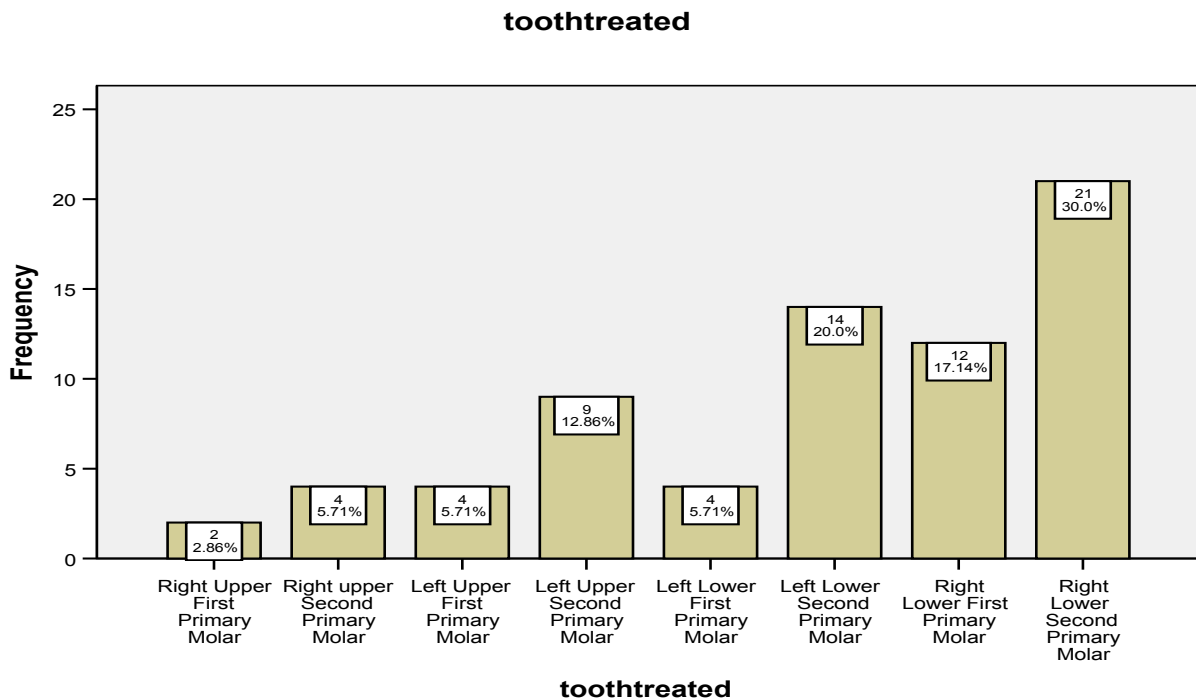
**Graph 2**



**Table 1:** Descriptive Statistics of Age of Patient (n=70)

| STATISTICS                | Age (years) |
|---------------------------|-------------|
| Mean ± Standard Deviation | 6.9±1.29    |
| Mode                      | 5           |
| Median                    | 7           |
| Minimum Age               | 5           |
| Maximum Age               | 10          |

**Graph 3:** Frequency and percentage of type of tooth treated



## DISCUSSION:

The present study aimed to explore one of the most controversial areas in the field of pediatric dentistry i.e the vital pulpotomy procedure. The present study is unique and particularly important in that it appears to be the first time that ferric sulphate has ever been applied in the primary molar tooth pulpotomy in children in Pakistan. Formocresol has been considered as a gold standard<sup>17</sup> (Kings et al, 2002) and has a high success rate as a pulp medicament yet its use has been under much scrutiny due to its possible local and systemic toxicity. These toxicity concerns make it imperative to find a biologically viable substitute to formocresol. The present study intended to determine the viability of Ferric sulphate as an alternative to Formocresol in teeth with large carious lesions approaching the pulp.

The present study covered reliably the whole spectrum of cariously exposed vital pulps among the general population as patients from government sector are treated free and private patients are charged nominally.

In the present study 70 healthy subjects between the age group of 5-10 years, both males and females were randomly allocated by using the random table to either formocresol or ferric sulphate group of 35 teeth each. The total number of patients who were assessed for eligibility was 100, out of which 22 patients were excluded as they were not meeting up to the inclusion criteria (few of them refused to participate). Of the 78 patients enrolled for the study 5 didn't attend the follow up visit, and 3 were terminated due to uncontrolled hemostasis, resulting in 70 cases for the outcome analysis. Overall 30 of 70 pulpotomized teeth were restored with amalgam, 40 with glass ionomer, followed by stainless steel crowns (SSC).

The efficacy between ferric sulphate and formocresol pulpotomy was compared in terms of both clinical and radiographic (outcomes) symptom free teeth at 3 and 6 months interval. Clinical failure parameters were pain, swelling, fistula, and pathological tooth mobility whereas radiographic failure parameter was periapical and furcation radiolucency.

Although it was hypothesized that Formocresol will have high success rate than ferric sulphate for pulpotomies of cariously exposed primary molars but the results of this investigation demonstrate a comparable clinical and radiographic outcome with FS when compared with the 'gold standard', FC.

The results of the study showed that the overall success rate in both FC and FS group was found to be 94.28% after 6 months whereas the failure rate was 5.71%. The differences between success and failure rates of two treatment methods were not statistically significant as P value was >0.05 which showed that the hypothesis 'Formocresol will have high success rate than ferric sulphate for pulpotomies of cariously exposed primary molars' was rejected.

The results of the present study are in accordance with the studies of Fei et al (1991), Fuks et al (1997), Ibrevic & Al-Jame (2000), Papagiannoulis et al (2002), Smith et al (2000), and Casas et al (2003) showing that there is no significant differences between the clinical and radiographic success rate of the FC and FS groups<sup>30-35</sup>.

In the present study the sample size was small, and the recall rate was excellent. This is in agreement with Ibrevic and AL Jame (2000) and by Fei et al (1991) studies<sup>31-33</sup>.

Fei et al (1991) used twenty seven teeth in the FC group and twenty nine in FS group<sup>31</sup>. While in present study thirty five teeth were allocated to each group. Hence the results are very much comparable with the above mentioned study.

Matracia, S. (2009) indicated that more than 62% of the children under 6 years old, who presented to either the outpatient dental clinic or a Dental Surgery Center, were treated with SSC, or SSC plus pulpotomy<sup>36</sup>. In the present study the age range of children was 5 to 10 years with a mean age of 6.9±1.29 years. The highest frequency for age occurring in the data was 5 years (Mode=5).

However, Huth KC included subjects between 2-8 years with the mean age of 4.8 ± 1.6 years as in contrast with our study<sup>9</sup>. 43 (61.4%) out of 70 subjects in the present study were males whereas 27 (38.6%) were females, which shows that males who presented with cariously exposed vital pulps outnumbered females. The explanation for this finding could be that in Pakistani society especially in lower socioeconomic groups, people are more concerned of the health of their sons. Secondly, boys are more careless about their dental hygiene. However with reference to Pakistani context, gender differences in presentation of carious teeth further needs to be investigated.

Our study is in contrast with papagiannoulis et al where the study was conducted in Greece and almost equal gender presentation was seen i.e. 46 males and 44 females<sup>34</sup>. In a similar fashion, in Germany Huth KC had 56 males and 47 females in their study<sup>9</sup>.

31% of the subjects in the study belonged to Low socioeconomic status where as 44.3% were from the middle class and 24.3% reported belonging to high socioeconomic status. This result was in contrary to many previous studies. A link between socioeconomic status factor and the disease was widely accepted and has been shown by Reisine. The pattern of disease was less extensive among high socioeconomic status class<sup>37</sup>.

In the present study it was observed that three maxillary teeth showed periapical radiolucency and pain and one mandibular tooth showed periapical radiolucency. Huth kc found no differences in overall total success rates between pulpotomies performed in first or second primary molars, or in the maxilla or in the mandible<sup>9</sup>.

The teeth most commonly involved were the second primary molars (51 teeth). It was observed that the mandibular teeth were mostly carious (51 teeth) in

comparison with the maxillary teeth (19 teeth). Likewise Spolidorio, D. et al 2003 observed that major teeth showing high levels of dental caries, particularly on the occlusal surface were the second inferior primary molar followed by the first inferior primary molar, second superior molar and first superior molar, respectively<sup>38</sup>. The increased susceptibility of inferior primary molars to dental caries can be attributed to their earlier eruption followed by the superior primary molars.

At 3 months interval only 1 of 35 patients treated in FS group showed pain in contrast to FC group where no patient had such symptoms. Subjects did not report any clinical and radiological parameters in either group after 3 months in this study.

At 6 months interval, 1 out of 35 patients in both FC and FS groups reported pain and 1 out of 35 primary molars in both FC and FS groups showed periapical radiolucency. None of the patients reported other clinical symptoms after 6 months (i.e. fistula, swelling and mobility).

The results of this study are in accordance with the study conducted by Fei et al [1991] in which at 3 and 6 months interval no statistically significant difference was found between the two groups. The most frequent evidence of failure in this short term study in both groups was furcation radiolucency<sup>31</sup>.

Clinical studies have reported similar<sup>23</sup> or higher<sup>9, 31</sup> clinical and radiographic success rates of Ferric Sulfate as compared to 1:5 dilute Formo Cresol. In a retrospective study, Smith et al showed lower success rates for Ferric Sulfate than those previously reported in the dental literature (11). Nevertheless, these success rates were comparable with those reported for dilute Formocresol pulpotomies.

The most significant limitation of this study is the shorter observation time because many patients reporting from outside Islamabad fail to show up for more than two recalls. As 6 month follow up of our patients is rather short for evaluating the outcome of pulpotomy and success rate, so further studies are needed to judge the preference of ferric sulphate to formocresol in the long term.

Another limitation is the small sample size as prospective randomized trials in humans are difficult and time consuming to conduct.

#### CONCLUSION:

This study provides a basis for further studies in the field with a long term follow up and more participants. Moreover in case of successful treatment outcome, the potential for unwanted sequelae from the unplanned extraction of primary molars will be reduced. Thus preservation of primary teeth in the arch will not only help in the management of developing dentition but will also facilitate nurturing a positive attitude in children towards dental health.

Advantages of ferric sulphate over formocresol are its ease and speed of use and it is less pungent making it easier to use with children. It is also readily available and most practitioners will already have it in their surgeries. However, it should be used with caution as can cause reversible damage to the connective tissue adjacent to the sulcular gingiva after application of ferric sulphate.

#### REFERENCES:

1. Camp JH, Barrett EJ, Pulver F: Endodontics treatment for primary and young dentition. In: Cohen S, Burns RC (edi). Pathway of the pulps. 8th Edition. St Louis Mosby; 2002:797-847.
2. American Academy of Pediatric Dentistry Clinical Affairs Committee--Pulp Therapy Subcommittee--Guideline on Pulp Therapy for Primary and Young Permanent Teeth. *Pediatr Dent* 2007-2008; 29: 163-7.
3. Fuks AB. Current concepts in vital primary pulp therapy. *Eur J Paediatr Dent* 2000; 3:115-120
4. Fuks AB. Pulp therapy for the primary and young dentitions. *Dent Clin North Am* 2000 Jul; 44(3):571-96
5. Roberts, J.D. (2009), Indirect Pulp Treatment Versus Formocresol Pulpotomy in Human Primary Molars: A Randomized Controlled Trial available at <https://pqdtopen.proquest.com/doc/305167859.html?FMT=AI>. [Retrieved on July, 2009]
6. Waterhouse PJ, Nunn JH, Whitworth JM. An investigation of the relative efficacy of Buckley's Formocresol and calcium hydroxide in primary molar vital pulp therapy. *Br Dent J* 2000 Jan 8; 188(1):32-6.
7. Guelmann M, Fair J, Turner C, Courts FJ. The success of emergency pulpotomies in primary molars. *Pediatr Dent* 2002 May-Jun; 24(3):217-20.
8. Goho C. Pulse oximetry evaluation of vitality in primary and immature permanent teeth. *Pediatr Dent* 1999; 21(2): 125-7.
9. Huth KC, Paschos E, Hajec-Al-Khatar N, Hollweck R, Crispin A, Hickel R, et al. Effectiveness of 4 pulpotomy techniques--Randomized controlled trial. *J Dent Res* 2005;84(12):1144-1148
10. Nadin G, Goel BR, Yeung CA, Glennly AM . Pulp treatment for extensive decay in primary teeth. *Cochrane Database Syst Rev* 2003; 1:CD003220.
11. Avram DC, Pulver F. Pulpotomy medicaments for vital primary teeth. Surveys to determine use and attitudes in pediatric dental practice and in dental schools throughout the world. *ASDC J Dent Child* 1989; 56(6):426-34.
12. Sweet CA. Procedure for treatment of exposed and pulpless deciduous teeth. *J Am Dent Assoc* 1930; 1150-4.
13. Morawa AP, Straffon LH, Han SS, Copron RE. Clinical evaluation of pulpotomies using dilute formocresol. *ASDC J Dent Child* 1975; 42(5): 360-363.
14. Fuks AB, Bimstein E. Clinical evaluation of diluted formocresol pulpotomies in primary teeth of schoolchildren. *Pediatr Dent* 1981; 3(4): 321-324.
15. Garcia-Godoy F. Direct pulp capping and partial pulpotomy with diluted formocresol in primary molars. *Acta Odontol Pediatr* 1984 Dec; 5(2): 57-61.

16. Prakash C, Chandra S, Jaiswal JN. Formocresol and glutaraldehyde pulpotomies in primary teeth. *J pedod* 1989; 13(4): 314–322.
17. King SR, McWhorter AG, Seale NS. Concentration of formocresol used by pediatric dentists in primary tooth pulpotomy. *Pediatr Dent* 2002 Mar.-Apr; 24(2): 157-159.
18. Kofman SH, Friedman CS, Bylykbashi J, El-Kassem M. Retrospective Clinical Study of Pulp Treatment with Ferric Sulfate and Formo Cresol. *Acta Stomatol Croat* 2006; 40(2):107-115.
19. Yamasaki M, Nakamura H, Kameyama Y. Irritating effect of formocresol after pulpectomy in vivo. *Int Endod.J* 1994; 27(5): 245-51.
20. Pruhs RJ, Olen GA, Sharma PS. Relationship between formocresol pulpotomies on primary teeth and enamel defects on their permanent successors. *J Am Dent Assoc* 1977; 94(4): 698-700.
21. Saltzman B, Sigal M, Clokie C, Rukavina J, Titley K, Kulkarni GV. Assessment of a novel alternative to conventional formocresol-zinc oxide eugenol pulpotomy for the treatment of pulpally involved human primary teeth: diode laser-mineral trioxide aggregate pulpotomy. *Int Paediatr Dent* 2005 Nov; 15(6):437–447
22. Waterhouse PJ. Formocresol and alternative primary molar pulpotomy medicaments: a review. *Endod Dent Traumatol* 1995; 11:157-162.
23. Fuks AB, Eidelman E, Cleaton-Jones P, Michaeli Y. Pulp response to ferric sulfate, diluted formocresol and IRM in pulpotomized primary baboon teeth. *ASDC J Dent Child* 1997; 64(4): 254-9
24. Antar F, Bacho R, Abi Hatem G, Ghosn Z. Is formocresol still the medication of choice for pulpotomies in primary teeth? A literature review. *Lebanes J of Dental Medicine* 2004; 3:53
25. Ibricevic H, Al-Jame Q. Ferric sulphate and formocresol in pulpotomy of primary molars: long term follow-up study. *Eur J Paediatr Dent* 2003; 4(1): 28–32.
26. Loh A, O’Hoy P, Tran X, Charles R, Hughes A, Kubo K, Messer LB. Evidence based assessment: evaluation of the formocresol versus ferric sulfate primary molar pulpotomy. *Pediatr Dent* 2004; 26(5): 401–409.
27. Casas MJ, Kenny DJ, Johnston DH, Judd PL. Long-term outcomes of primary molar ferric sulfate pulpotomy and root canal therapy. *Pediatr Dent* 2004; 26(1):44–48.
28. Shaw DH, Krejci RF, Kalkwarf KL, Wentz FM. Gingival response to retraction by ferric sulfate (Astringedent). *Oper Dent* 1983; 8(4):142–7.
29. Epstein E, Maibach HI. Monsel’s solution: history, chemistry and efficacy. *Arch Dermatol* 1964; 90(2):226–8.
30. Smith NL, Seale NS, Nunn ME. Ferric sulfate pulpotomy in primary molars: a retrospective study. *Pediatr Dent* 2000; 22:192–9.
31. Fei A, Udin R, Johnson R. A clinical study of ferric sulfate as a pulpotomy agent in primary teeth. *Pediatr Dent* 1991; 13: 327–332.
32. Fuks AB, Holan G, Davis JM, Eidelman E. Ferric sulfate versus dilute formocresol in pulpotomized primary molars: long term follow up. *Pediatr Dent* 1997; 19: 327–330.
33. Ibricevic H, Al-Jame Q. Ferric sulfate as pulpotomy agent in primary teeth: twenty month clinical follow-up. *Pediatr Dent* 2000; 24: 269–272.
34. Papagiannoulis L. Clinical studies on ferric sulphate as a pulpotomy medicament in primary teeth. *Eur J Paediatr* 2002; 3: 126–132.
35. Casas MJ, Layug MA, Kenny DJ, Johnston DH, Judd PL. Two-year outcomes of primary molar ferric sulphate pulpotomy and root canal therapy. *Pediatr Dent* 2003; 25: 97–102.
36. Matracia, S. (2009), Pulpotomy to Stainless Steel Crown Ratio in Children with Early Childhood Caries: A Cross Sectional Analysis. Available at site [http://etd.ohiolink.edu/send-pdf.cgi/Matracia%20YoonMiSophie%20L.pdf?acc\\_num=osu1242096142](http://etd.ohiolink.edu/send-pdf.cgi/Matracia%20YoonMiSophie%20L.pdf?acc_num=osu1242096142) retrieved on 15-12-2009
37. Reisine ST, Psoter W. Socioeconomic status and selected behavioral determinants as risk factors for dental caries. *J Dent Educ* 2001 Oct; 65 (10): 1009-16.
38. Spolidorio D, Hofling J, Moreira D, Rodrigues J.A, Boriollo F.G, Rosa E. Dental caries status in deciduous and permanent dentition of Brazilian children aged 6-8 years with a socioeconomic base. *Braz J Oral Sci* 2003; 2(4): 147-51.

**Source of support:** Nil

**Conflict of interest:** None declared

This work is licensed under CC BY: *Creative Commons Attribution 3.0 License*.

@Society for Scientific Research and Studies